

***In vivo* evaluation & safety profile evaluation of *Arctostaphylos uva-ursi* (L.) Spreng. extract in rabbits**

Farah Saeed^{1*}, Mehjabeen², Noor Jahan³ and Mansoor Ahmad⁴

¹Department of Pharmacognosy, Dow College of Pharmacy, Dow University of Health and Sciences, Karachi, Pakistan

²Department of Pharmacology, Faculty of Pharmacy, Federal Urdu University of Arts Science and Technology, Karachi, Pakistan

³Department of Pharmacology, Dow College of Pharmacy, Dow University of Health and Sciences, Karachi, Pakistan

⁴Research Institute of Pharmaceutical Sciences, University of Karachi, Karachi, Pakistan

Abstract: The aim of our research work was to investigate the effects of low dose of *Arctostaphylos uva-ursi* (L.) Spreng. on rabbits. Crude extract was administered for 90 days in rabbits and hematology, biochemistry parameters and histopathology changes were analyzed. In result of it gender-based variations were observed in hematological, kidney function, liver function, cardiac enzymes and lipid profile. Urine analysis revealed same results as that of standard and control drug. No significant pathology was observed in heart, stomach, liver and kidney tissues of rabbits, treated with *A.uva-ursi* in a dose of 25 mg/kg/day. Our results justify the use of *A. uva-ursi* in medicine for treatment of variable pathologies.

Keywords: Bearberry, hematology, biochemical parameters, urine analysis, histopathology.

INTRODUCTION

Arctostaphylos uva-ursi (L.) Spreng. is a drug used for treatment of pain, diuretic, contact dermatitis, kidney stone removal and urinary tract infections (Adesunloye, 2003). A number of chemical compounds have been reported from this plant such as hydroquinone, methyl arbutin, arbutin, corilagin, allantoin, hyperoside, quercetin, kaempferol, myricetin, ellagic acid, gallic acid, malic acid, picroside, α -amyrin, ursolic acid, quinic acid, hydroquinone-O- β -D-glucoside, 6-O-galloyl arbutin, ρ -coumaric acid, syringic acid, salicylic acid etc (Bradley 1992; ESCOP 2003; British Herbal Pharmacopoeia 1996; Gruenwald *et al.* 2004).

Arbutin, a phenolic glycoside is the main constituent of *A. uva-ursi* that on hydrolysis is converted into hydroquinone. Both these chemicals have anti-bacterial antiseptic effect on the urinary tract (Brown, 1995). Arbutin, alone has been found to be effective in relieving pain associated with kidney stones, cystitis and nephritis as well as a diuretic (Chiej, 1984; Foster and Duke, 1990 Launert, 1981; Lust, 1983; Kavasch, 1979; Uphof, 1959; Chevallier, 1996). Ursolic acid, iso-quercetin may be used as mild diuretic (Beaux *et al.*, 1999; Weiss, 1988). It has anti-lithic property that helps in dissolving stones in kidneys. This herb facilitates to keep the pH balance of urine from being too acidic. It actually strengthens the lining of the urinary tract and helps to get rid of any inflammation in the urinary bladder and kidneys. It has a direct relaxing effect on the bladder walls (Willard, 1992; Blumenthal *et al.* 1998; Siegers *et al.*, 1997; Larsson *et al.* 1993).

MATERIALS AND METHODS

Arctostaphylos uva-ursi (L.) Spreng. leaves were collected in 2009 from the botanical garden of the University of Karachi and identified by Prof. Dr. Mansoor Ahmad, Research Institute of Pharmaceutical Sciences, University of Karachi. A specimen voucher (FSMP-08-09) of the plant material is deposited in the herbarium of Department of Pharmacognosy, University of Karachi.

Preparation of extract

The collected fresh leaves (5 kg) of *A. uva-ursi* were air dried at 25°C and were chopped into small pieces. The chopped material was soaked in 3L ethanol. Alcoholic extract was prepared by percolation. This procedure was repeated thrice. Extract was concentrated by rota-evaporator (Buchi-Rotary Evaporator, Switzerland, model # B490) at 40°C. The yield of the extract was 450gm.

Chemicals & reagents

All the chemicals and reagents used were of analytical grade and purchased from Merck (Germany).

Experimental animals

Rabbits of both sexes, weighing 1.5kg were purchased from Animal House Dow University of Health Sciences (DUHS), Karachi and kept in animal house for a period of 15 days to acclimatize. Male and female rabbits were kept in separate cages and fed with their normal diet and water. Their weights were monitored at random. The drug was administered at an interval of 24 hours for duration of 3 months. The blood of the rabbits was taken by cardiac puncture at the end of 3 months.

*Corresponding author: e-mail: farah.saeed079@gmail.com

Animal grouping and drug dosing for hematological and biochemical evaluation

Four groups were made (male control-6 rabbits), (female control-6 rabbits), (male test (UUM)-6 rabbits) and (female control (UUF)-6 rabbits). Male and female control groups were given distilled water, while test groups UUM and UUF were given 25mg/kg *A. uva-ursi*. All the administration were oral. This treatment continued for 90 days. Blood (6ml) was collected by cardiac puncture with 10ml sterile syringe using 1mg/1ml EDTA as anticoagulant for the determination of blood and biochemical parameters.

Animal grouping and drug dosing for histo-pathological examination

Four groups were made namely; group I (positive control), group II (male test group without CCl₄), group III (Negative control) and group IV (male test group with CCl₄):

Group 1 (Positive control): Six animals were kept as male positive control. Water and food was provided to the animals during the entire period of experiment.

Group 2 (without CCl₄ group - male test group): Six animals were administered 25 mg/kg of test drug extract, water and food was provided to the animals during the entire period of experiment.

Group 3 (Negative control): Six animals were kept as male negative control. Water and food was provided to the animals during the entire period of experiment.

Group 4 (with CCl₄ group – male test group): Six animals were administered 25 mg/kg of Test drug extract, water and food was provided to the animals during the entire period of experiment.

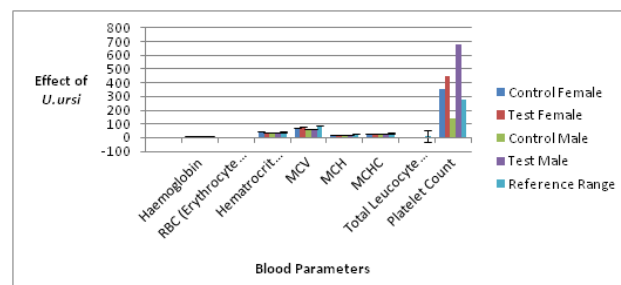
The animals were sacrificed at the end of 90 days after taking out blood through cardiac puncture technique for the afore-mentioned tests. Carbon tetrachloride was injected 6 hours before taking blood for carrying out liver function test to group III & IV by cardiac puncture and sacrificing (Lucas *et al.*, 2004). Animal studies were carried out according to Ethical Principles and Guidelines for Experiments on Animals formulated jointly by the Swiss Academy of Medical Sciences and the Swiss Academy of Sciences.

Hematological evaluation

Total erythrocyte counts were counted using a Neubauer chamber under a light microscope at 40x10 magnifications. Blood samples were diluted to 200 times by Hayem’s reagent before counting. Blood hemoglobin concentration was determined using a Sahli’s hemometer. Micro Wintrobe hematocrit tubes and hematocrit centrifuge were used to determine the (PCV). Total leucocyte counts were detected using a Neubauer chamber under a light microscope at 10x10 magnification after diluting blood samples to 10 times with Turk’s solution. Mean erythrocyte volume (MCV), mean corpuscular

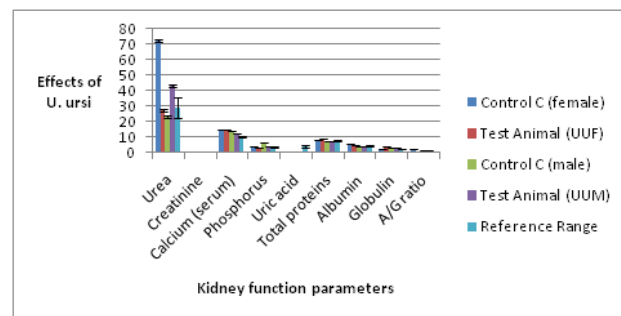
hemoglobin (MCH) and mean corpuscular hemoglobin concentration (MCHC) for particular blood samples were also calculated (Burnett *et al.*, 2006; Dacie & Lewis, 1991; McGowen *et al.*, 1955).

Biochemical evaluation: Serum samples were obtained by centrifugation of blood at 1300xg for 15min. The Menarini Classic Chemistry Analyzer was used to determine the calcium (Ca), phosphorus (P), blood urea, creatinine, total bilirubin, total protein, albumin, alkaline phosphatase (ALP), aspartate aminotransferase (AST), alanine aminotransferase (ALT), creatine phosphokinase (CPK), cholesterol, glucose, amylase, and gamma-glutamyltransferase (GGT). The globulin concentration was determined by subtracting the albumin concentration from the total protein concentration (Amadori *et al.*, 1997; Reitman & Frankel, 1957).



Graph 1: Shows the effect of *A. uva-ursi* extract on the blood parameters of rabbits (male & female) in comparison with the control (male & female).

UUF = Female rabbits treated with drug; UUM = Male rabbits treated with drug



Graph 2: Shows the effect of *A. uva-ursi* extract on kidney function parameters of rabbit in comparison with the control.

UUF = Female rabbits treated with *A. uva-ursi* extract; UUM = Male rabbits treated with *A. uva-ursi* extract

STATISTICAL ANALYSIS

Results of the study were presented as a mean plus or minus standard error of mean (M ± SEM). Differences between control and treatment groups were analyzed by student *t-test* (Snedecor & Cochran, 1967).

Table 1: Complete Blood Count of Rabbits treated (UUF & UUM) with and without (Control Female & Control Male) *A. uva-ursi* extract

Blood Parameter	Control Female	Test Female (UUF)	Control Male	Test Male (UUM)	Reference Range
Haemoglobin	12.15±0.0836	9.52±0.02	10.05±0.0836	11.208±0.063	10.75±0.689
RBC (Erythrocyte Count)	5.895±0.00836	4.425±0.0083	5.485±0.00836	5.625±0.0083	3.916±0.277
Hematocrit (HCT/PVC)	42.835±0.0739	33.768±0.093	34.2±0.0632	36.85±0.083	38.67±1.932
MCV	72.416±0.0658	75.85±0.0836	62.5±0.836	65.53±0.11	89±3.183
MCH	20.835±0.0739	21.34±0.07	18.15±0.0836	19.85±0.0836	30.167±1.180
MCHC	28.783±0.0658	28.308±0.063	29.05±0.0836	30.325±0.068	32.5±0.836
Total Leucocyte Count (WBC)	6.05±0.0836	4.67±0.048	5.5±0.0632	5.35±0.0836	11±1.673
Platelet Count	353.5±0.836	451.03±0.318	140.5±0.836	683.5±0.836	275±41.83

Table 2: Kidney Function Parameters of Rabbits treated (UUF & UUM) with and without (Control Female & Control Male) *A. uva-ursi* extract

Biochemical Parameters	Control C (female)	Test Animal (UUF)	Control C (male)	Test Animal (UUM)	Reference Range
Urea	72.5±0.83	27.5±0.836	23.5±0.83	43±0.632	29.167±6.39
Creatinine	0.85±0.008	0.71±0.01	0.85±0.0083	0.73±0.048	0.8167±0.127
Calcium (serum)	14.59±0.063	15.18±0.0083	14.17±0.0083	12.475±0.0083	10.03±0.318
Phosphorus	3.825±0.068	3.57±0.0087	6.195±0.0083	4.22±0.01	3.53±0.318
Uric acid	0.0175±0.004	0.03±0.0063	0.165±0.0083	0.043±0.0078	3.916±0.639
Total proteins	8±0.02	8.89±0.01	7.495±0.0083	7.185±0.0083	7.467±0.347
Albumin	5.83±0.013	4.65±0.0065	4.305±0.0083	4.19±0.01	4.5±0.28
Globulin	2.153±0.0096	4.22±0.01	3.185±0.0083	3.013±0.0096	2.35±0.146
A/G ratio	2.715±0.0083	1.1±0.0083	1.35±0.016	1.395±0.0083	0.75±0.052

UUF = Female rabbits treated with drug; UUM = Male rabbits treated with drug

Table 3: Cardiac Enzymes Parameters of Rabbits treated (UUF & UUM) with and without (Control Female & Control Male) *A. uva-ursi* extract

Biochemical Parameters	Control C (female)	Test Animal (UUF)	Control C (male)	Test Animal (UUM)	Reference Range
LDH	163.5±0.836	239.67±1.154	270.5±0.83	493.83±1.278	331.67±40.34
CPK	729.5±0.83	481.5±0.83	421.5±0.83	3052±1.166	90.33±25.03
CK-MB	852.5±0.83	727.5±0.836	194.5±0.83	1568.5±0.836	16.67±2.46

UUF = Female rabbits treated with drug; UUM = Male rabbits treated with drug

Table 4: Lipid Profile Parameters of Rabbits treated (UUF & UUM) with and without (Control Female & Control Male) *A. uva-ursi* extract

Biochemical Parameters	Control C (female)	Test Animal (UUF)	Control C (male)	Test Animal (UUM)	Reference Range
Cholesterol	30.5±0.83	83.5±0.836	58.5±0.83	49.5±0.836	109.16±22.24
Triglycerides	0.5±0.83	159.83±1.036	131.5±0.83	34.5±0.83	111.67±13.68
HDL	12.5±0.83	12.5±0.836	6.5±0.83	14.5±0.836	19.67±3.18
LDL	16.5±0.83	48.5±0.836	38.5±0.83	36.83±3.72	103.33±15.14
VLDL	7.5±0.83	30.5±0.836	26.5±0.83	7±0.63	30±5.83

UUF = Female rabbits treated with drug; UUM = Male rabbits treated with drug

Table 5: Liver Enzymes Parameters of Rabbits treated (UUF & UUM) with and without (Control Female & Control Male) *A. uva-ursi* extract

Biochemical Parameters	Control C (female)	Test Animal (UUF)	Control C (male)	Test Animal (UUM)	Reference Range
SGOT	26.5±0.83	18.67±0.96	42.5±0.83	565±0.63	21.83±3.11
Total Bilirubin	0.275±0.0083	0.215±0.0083	0.265±0.0083	0.305±0.0083	1.75±0.083
Direct Bilirubin	0.021±0.005	0.05±0.0063	0.041±0.0065	0.095±0.0083	0.029±0.0008
SGPT	41.5±0.83	30.83±1.036	68.5±0.83	382.67±1.154	27.5±4.18
Alkaline Phosphatase	37.5±0.83	50.83±1.036	228.5±0.83	52.5±0.836	91.67±17.30
Gamma GT	6.5±0.83	8.5±0.836	9.5±0.83	66.5±0.836	29.16±6.39

UUF = Female rabbits treated with drug; UUM = Male rabbits treated with drug

RESULTS

Effects of *A. uva-ursi* on hematological and biochemical parameters are shown in tables 1-5 and graphs 1-5 respectively. Histopathology of heart, stomach, liver and kidney tissues of rabbit treated with *A. uva-ursi* 25mg/kg/day for 90 days are shown in fig. 1. Histopathology of heart, stomach, liver and kidney tissues of rabbits treated with *A.uva-ursi* 25mg/kg/day for 90 days while injected Carbon tetrachloride 6 hours prior to dissection are shown in fig. 2.

DISCUSSION

A. uva-ursi L. Spreng. is commonly called Bearberry that contains arbutin, the hydroquinone derivative as its chief active constituent and has been used since antiquity for the treatment of urinary tract infection (Small & Catling, 1999; Kosalec *et al.*, 2008; Dykes *et al.*, 2003). Hydroquinone exhibits anti-bacterial, astringent, disinfectant and anti-oxidant activity (Chukarina *et al.*, 2007; Amarowicz *et al.*, 2004). Other active constituents isolated from *A. uva-ursi* include phenolic acids, flavonoids, tannins, iridoids and triterpenoids (Ritch *et al.*, 1996;Dykes *et al.*, 2003). Pre-clinical studies revealed that *A. uva-ursi* potentiates the anti-inflammatory effect of corticosteroids and NSAIDs (Matsuda *et al.*, 1990).

This research work is a new approach to recognize the effects of active constituents of *A. uva-ursi* extract on blood parameters of male & female rabbits (fig. 3). It is of interest to mention here that the results of *A. uva-ursi* extract in male rabbits' blood are different than that of female rabbit's blood. In male and female rabbits blood some parameters like leucocytes were slightly reduced whereas increase in platelet count may be due to the presence of arbutin. Overall *A. uva-ursi* extract showed similar effects with different values (male/female) and that is due to male and female body structures. In comparison with standard drugs and control group elevation and reduction in blood parameters were detected. These effects revealed effective utilization of *A. uva-ursi* in treatment of inflammatory condition like dermatitis and urinary tract infection.

The effects of *A. uva-ursi* extract on rabbit's kidney were observed and noted that urea (43±0.62) and albumin/globulin ratio (1.395±0.0083) were on higher side in comparison to control group of male rabbits whereas creatinine (0.73±0.48), serum calcium (12.475±0.0083), phosphorus (4.22±0.01), uric acid (0.043±0.0078), total proteins (7.185±0.0083), albumin (4.19±0.01) and globulin (3.013±0.0096) were found on lower side in male rabbits' blood as compared to control group. It is important to mention that there is a difference in male and female rabbits' blood parameters. Therefore, there are differences of values in each parameter. In kidney function test (female rabbit) the effects of *A. uva-ursi* extract were observed raised in serum calcium (15.18±0.0083), uric acid (0.03±0.0063), total proteins (8.89±0.01), and globulin (4.22±0.01) where as the following were found towards lower side: urea (27.5±0.836), creatinine (0.71±0.01), phosphorus (3.57±0.0087), albumin (4.65±0.0065) and albumin/globulin ratio (1.1±0.0083) in comparison to control group. Our results support the utilization of *A. uva-ursi* in treatment of inflammation of bladder and kidneys (Willard, 1992).

A. uva-ursi extract has effects on cardiac enzyme too but male and female rabbits' showed different responses such as in case of male rabbit cardiac enzyme, that is, LDH (493.83±1.278), CPK (3052±1.166) and CK-MB (1568.5±0.836) were found raised whereas LDH (239.67±1.154) raised in comparison to control group, while CPK (481.5±0.83) and CK-MB (727.5±0.836) were on the lower side. These effects may be due to anti-oxidant potential of *A. uva-ursi* due to its phenolic constituents.

A. uva-ursi extract showed good response in lipid profile of both sexes. In male rabbit HDL (14.5±0.836) was found towards higher side while in the female animal it remained the same but cholesterol (83.5±0.836), triglycerides (159.83±1.036), LDL (48.5±0.836) and VLDL (30.5±0.836) were found towards higher side in comparison to female control group. Male animals showed cholesterol (49.5±0.836), triglycerides (34.5±0.836), LDL (36.83±3.72) and VLDL (7.0±0.63) at a lower side in comparison to male control group.

Microscopic examination of heart

Sections show wall of heart composed predominantly of thick myocardium consists of bundles of cardiac muscle fibers separated by fibrous band, forming syncytium. Nuclei of myocytes are centrally located. Endocardium is lined by single layer of mesothelial cells resting on a basement membrane. No significant pathology is seen in any of the sections examined.

Microscopic examination of stomach

Sections show wall of gastric mucosa with intact architecture. The gastric mucosa is thrown into gastric pits and folds revealing well organized glandular structures. Underlying submucosa is scanty and unremarkable. Well organized muscular layer is seen beneath, lined externally by serosa. No significant pathology is seen in any of the sections examined.

Microscopic examination of liver

Sections show liver tissue with overall preserved lobular architecture. Portal tracts are within normal limits, containing portal triad and scanty fibrous tissue. No significant portal or lobular inflammation seen. No siderosis. No cholestasis. No evidence of granuloma or malignancy is seen.

Microscopic examination of kidney

Sections show renal tissue composed of cortex and medulla. Glomeruli are within normal limits. Tubule-interstitial compartment shows no significant pathology. Vascular structures are distributed evenly. No significant pathology is seen in any of the sections examined.

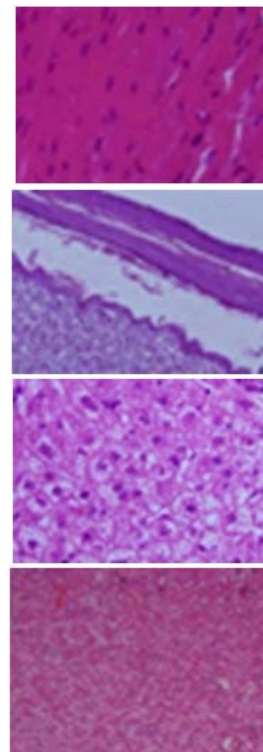


Fig. 1: Microscopic examination of male rabbit's heart, stomach, liver and kidney tissues treated with *A. uva-ursi* drugs extract.

Microscopic examination of heart

Sections show wall of heart composed predominantly of thick myocardium consists of bundles of cardiac muscle fibers separated by fibrous band, forming syncytium. Nuclei of myocytes are centrally located. Endocardium is lined by single layer of mesothelial cells resting on a basement membrane. No significant pathology is seen in any of the sections examined.

Microscopic examination of stomach

Sections show wall of gastric mucosa with intact architecture. The gastric mucosa is thrown into gastric pits and folds revealing well organized glandular structures. Underlying submucosa is scanty and unremarkable. Well organized muscular layer is seen beneath, lined externally by serosa. No significant pathology is seen in any of the sections examined.

Microscopic examination of liver

Sections show liver tissue with overall preserved lobular architecture. Portal tracts are mildly dilated with lymphocytic infiltrate and minimal fibrosis. Sinusoidal congestion and stellate cell hyperplasia is seen. Focal macrovesicular steatosis is also of note.

Microscopic examination of kidney

Sections show renal tissue composed of cortex and medulla. Glomeruli are within normal limits. Tubule-interstitial compartment shows mild focal tubular atrophy and lymphocytic inflammatory infiltrate. Occasional tubular lumina show micro abscess formation. Vascular structures are distributed evenly. No evidence of granuloma or malignancy is seen.

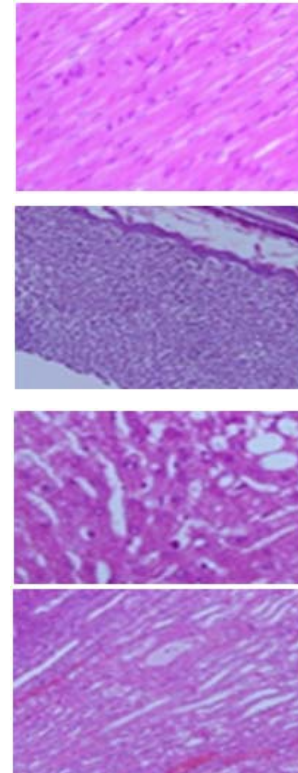
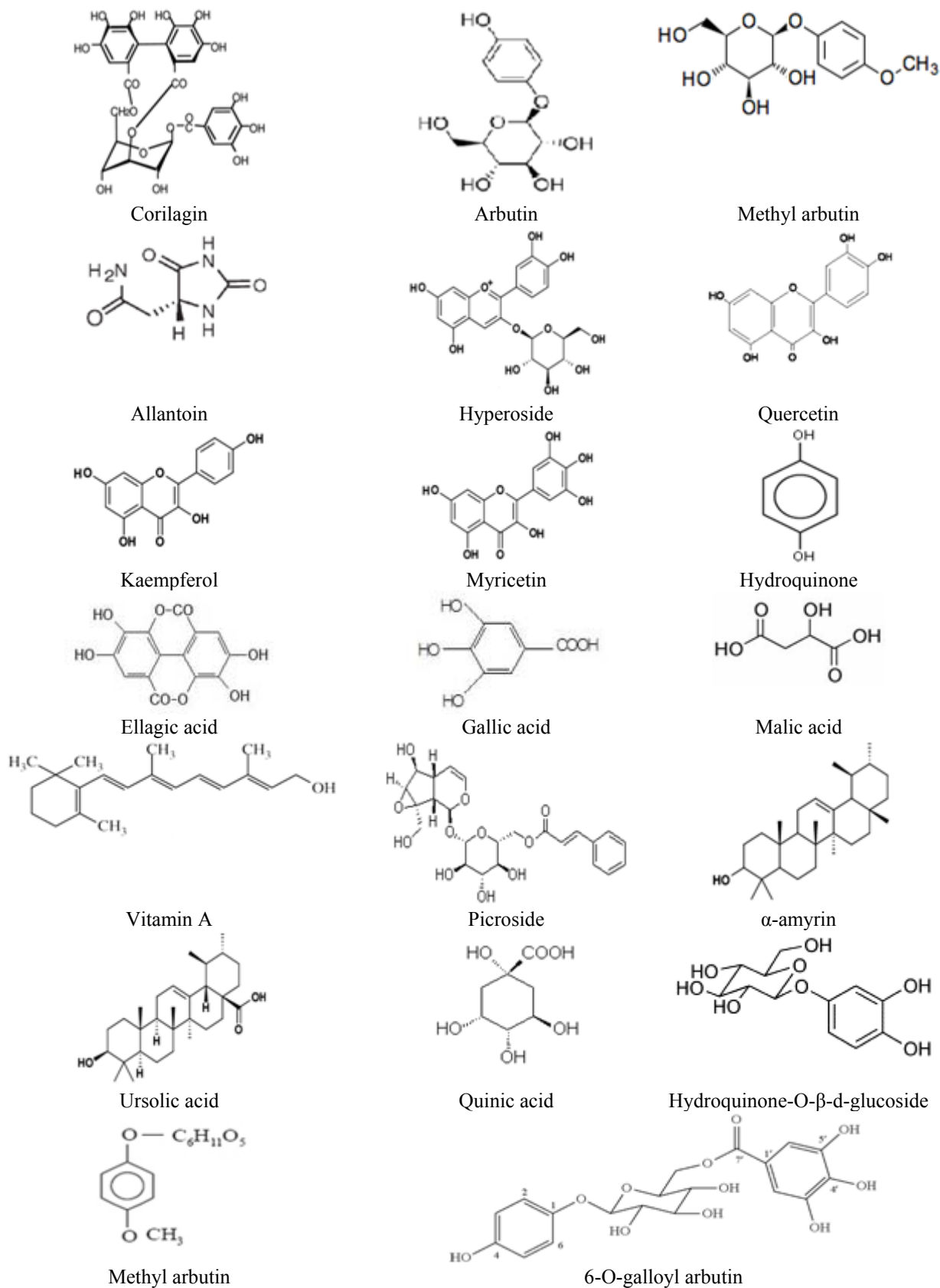


Fig. 2: Microscopic examination of female rabbit's heart, stomach, liver and kidney tissues treated with *A. uva-ursi* drugs extract.



Continued...

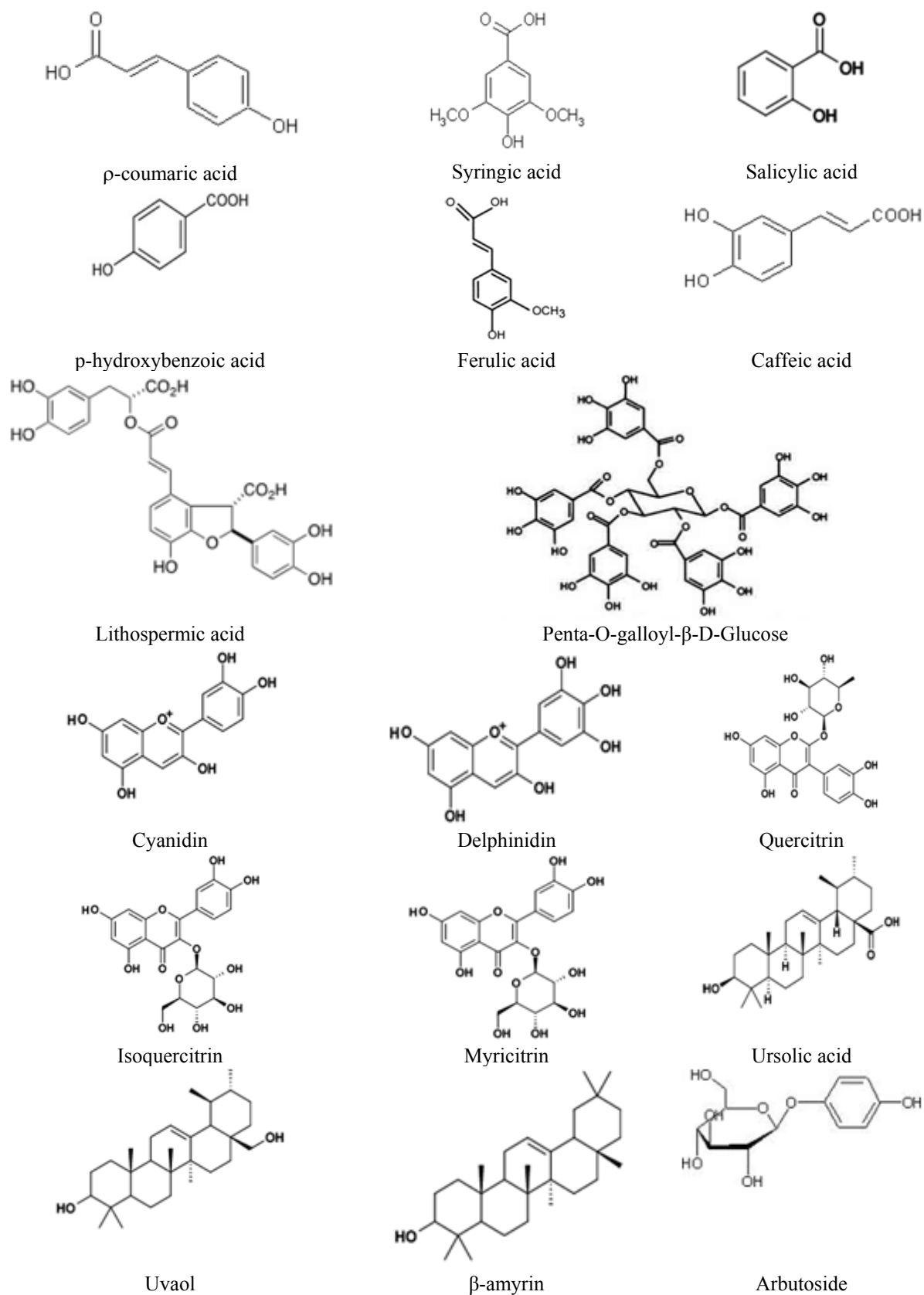
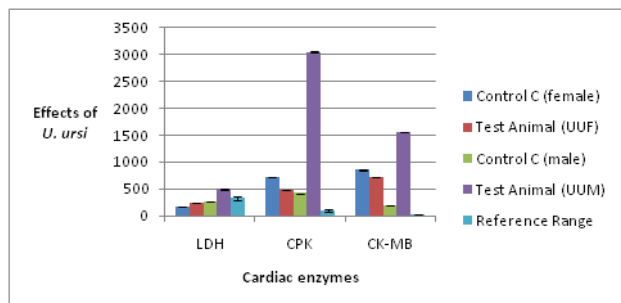


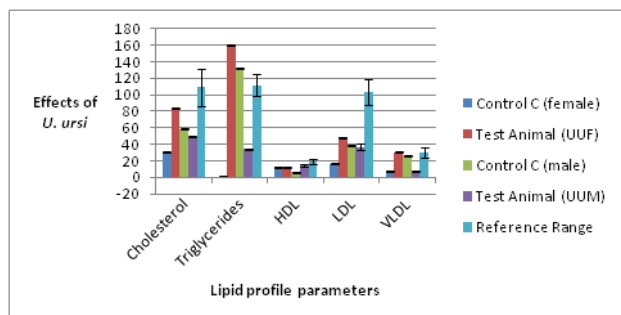
Fig. 3: Reported chemical structures present in *A. uva-ursi* L.

It is also interesting to note that in liver enzyme; alkaline phosphatase (52.5 ± 0.836) was lowered while SGOT (565 ± 0.63), total bilirubin (0.305 ± 0.0083), direct bilirubin (0.095 ± 0.0083), SGPT (382.67 ± 1.154) and gamma GT (66.5 ± 0.836) were raised in male rabbit blood parameters. In female rabbit unexpected different results were obtained such as direct bilirubin (8.5 ± 0.836), alkaline phosphatase (5.83 ± 1.036), and gamma GT (8.5 ± 0.836) were found towards the higher side. Whereas, SGOT (18.67 ± 0.96), SGPT (30.83 ± 1.036) and total bilirubin (0.215 ± 0.0083) were towards lower level in female control group.



Graph 3: Shows the effect of *A. uva-ursi* extract on cardiac enzymes of rabbits (male & female) in comparison with the control (male & female).

UUF = Female rabbits treated with *A. uva-ursi* extract; UUM = Male rabbits treated with *A. uva-ursi* extract



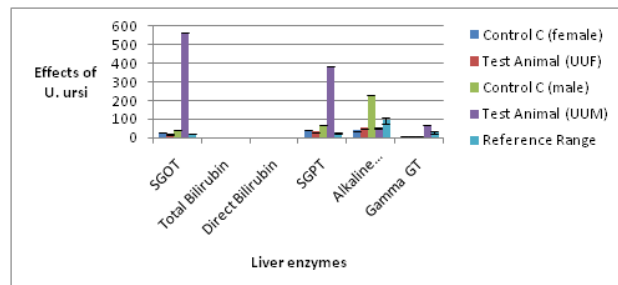
Graph 4: Shows the effect of *A. uva-ursi* extract on lipid profile parameters of rabbits (female & male) in comparison with the control (female & male).

UUF = Female rabbits treated with *A. uva-ursi* extract; UUM = Male rabbits treated with *A. uva-ursi* extract

Urine analysis results were found similar to control and standard drug of pH 8.6 to 9.0 in both sexes. This information is in favor of the use of this drug because it has no drastic effect or change in urine biochemistry parameters.

For performing autopsy of male rabbit organ, 25 mg extract was given to male and female rabbits daily for 3 months. Later autopsy of liver, kidney, heart and stomach were carried out. No pathological changes were observed in male and female rabbits. Our research work supports the previous work done on *A. uva-ursi* by *de Arriba et al.*

(2013). In the rabbits injected carbon tetrachloride subcutaneously, no pathological changes were found in heart and stomach tissues. Mild portal inflammation and peri-portal fibrosis with focal macro-vesicular steatosis was observed in liver tissues in *A. uva-ursi* while non-specific pyelonephritis was seen in kidney tissues.



Graph 5: Shows the effect of *A. uva-ursi* extract on liver enzymes of rabbits (female & male) in comparison with the control (female & male).

UUF = Female rabbits treated with *A. uva-ursi* extract; UUM = Male rabbits treated with *A. uva-ursi* extract

CONCLUSION

Our positive anti-microbial, anti-oxidant, analgesic, anti-inflammatory, diuretic and anti-urolithic results confirms the use of *A. uva-ursi* for treatment of pain, contact dermatitis, urinary tract infection, removal of kidney stones and diuresis. Therefore, our results support the utilization of *A. uva-ursi* in medicine.

REFERENCES

Adesunloye BA (2003). Acute renal failure due to the herbal remedy CKLS. *Am. J. Med.*, **115**(6): 506-507.

Amadori M, Archetti IL, Frasnelli M, Bagni M, Olzi E, Caronna G and Lanteri M (1997). An immunological approach to the evaluation of welfare in holstein frisian cattle. *J. Vet. Med.*, **44**: 321-327.

Amarowicz R, Pegg RB, Rahimi-Moghaddama P, Barl B and Weil JA (2004). Free-radical scavenging capacity and antioxidant activity of selected plant species from the Canadian prairies. *Food Chem.*, **8**: 551.

Beaux D, Fleurentin J and Mortier F (1999). Effect of extracts of *Orthosiphon stamineus* Benth, *Hieracium pilosella* L., *Sambucus nigra* L. and *Arctostaphylos uva-ursi* (L.) Spreng. in rats. *Phytother Res.*, **13**(3): 222-225.

Blumenthal M, Busse WR, Goldberg A and Gruenwald J (1998). The Complete German Commission E Monographs. American Botanical Council, Austin Texas, pp.224-225.

Bradley PR (1992). *Uva ursi*. In: British Herbal Compendium. *British Herbal Medicine Association*, **1**: 211-213.

- British Herbal Pharmacopoeia (1996). British herbal medicine association, Bournemouth. 4thed: pp.211-12.
- Brown D (1995). Encyclopedia of Herbs and their Uses. Dorling Kindersley, London. ISBN 0-7513-020-31.
- Burnett N, Mathura K, Metivier KS, Holder RB, Brown G and Campbell M (2006). An investigation into hematological and serum chemistry parameters of rabbits in Trinidad. *World Rabbit Sci.*, **14**: 175-187.
- Chevallier A (1996). Encyclopedia of Medicinal Plants. DK Publishing Inc., New York,
- Chiej R (1984). The Macdonald Encyclopedia of Medicinal Plants. London, Macdonald & Co. ISBN 0-356-10541-5.
- Chukarina EV, Vlasov AM and Eller KI (2007). Quantitative determination of arbutin and hydroquinone in leaves *Arctostaphylos*, *Vaccinium* and species. *Voprosy Pitaniia.*, **76**: 82.
- Dacie JV and Lewis SM (1991). Practical Haematology. Churchill Livingstone. *Edinburgh*, **7**: 521-534.
- de Arriba SG1, Naser B and Nolte KU (2013). Risk assessment of free hydroquinone derived from *Arctostaphylos uva-ursi* folium herbal preparations. *Int. J. Toxicol.*, **32**(6): 442-453.
- Dykes GA, Amarowicz R and Pegg RB (2003). An antioxidant bearberry (*Arctostaphylos uva ursi*) extract modulates surface hydrophobicity of a wide range of food-related bacteria: Implications for functional food safety. *Food Control*, **14**: 515.
- ESCOP Monographs (2003). *Uvae ursi* folium Bearberry leaf. European Scientific Cooperative on Phytotherapy. Thieme, Stuttgart. 2nd ed., pp.536-537.
- Foster S and Duke JA (1990). Medicinal plants. The Peterson Field Guide Series, Houghton Mifflin Company, New York.
- Gruenwald J, Brendler T and Jaenicke C (2004). PDR for herbal medicines. *Arctostaphylos uva-ursi*. 3rd ed., Thomson PDR, Montvale, pp.847-851.
- Kavasch B (1979). Native Harvests. Vintage Books, ISBN 0-394-72811-4.
- Kosalec I, Zovko M, Poljansek I, Pepeljnjak S, Kalodera Z, Sesok T and Matica B (2008). Anti-microbial activity of bearberry leaf (*Uvae ursi* folium) on clinical isolates of urogenital pathogens. *Farm. Glas.*, **64**: 357.
- Larsson B, Jonasson A and Pianu S (1993). Prophylactic effect of UVE E in women with recurrent cystitis: A preliminary report. *Curr. Ther. Res.*, **53**(4): 441-443.
- Launert E (1981). Edible and Medicinal Plants. Hamlyn. ISBN 0-600-37216-2
- Lucas RL, Lentz KD and Hale AS (2004). Collection and preparation of blood products, Clinical Techniques in Small Animal Practice. *Clin. Tech. Small Anim. Pract.*, **19**(2): 55-62.
- Lust J (1983). The Herb Book. Bantam Books.
- Matsuda H, Nakamura S, Tanaka T and Kubo M (1990). Pharmacological study on *Arctostaphylos uva ursi* (L.) Spreng II. Combined effects of arbutin and prednisolone or dexamethasone on immune-inflammation. *Yakugaku Zasshi.*, **110**: 68.
- McGowen JJ, Jones AAR and Steiner AG (1955). The haematocrit of capillary blood. *New England J. Med.*, 253-308.
- Reitman S and Frankel AS (1957). A colorimetric method of determination of serum glutamic oxaloacetic and glutamic pyruvic transaminases. *Am. J. Clin. Pathol.* **28**: 53-63.
- Ritch KRCEM, Thomas S, Turner NJ and Towers GHN (1996). Carrier herbal medicine: Traditional and contemporary plant. *J. Ethnopharmacol.*, **52**: 85.
- Siegers CP, Siegers JP, Pentz R, Bodinet C and Freudenstein J (1997). Metabolism of arbutin from *Uva-ursi* extracts in humans. *Pharm. Pharmacol. Lett.*, **7**: 90-92.
- Small E and Catling PM (1999). Canadian Medicinal Crops. NRC Research Press, Ottawa, p.21.
- Snedecor GW and Cochran WG (1967). Statistical Methods. Ames, Iowa: The Iowa State University Press, **6**: 423.
- Uphof JC Th (1959). Dictionary of Economic Plants. Weinheim, Germany. Hafner Publishing Co., New York.
- Weiss RF (1985). In: Lehrbuch der Phytotherapie, 6th ed., Hippokrates Verlag, Stuttgart, pp.304-306.
- Willard T (1992). Edible and medicinal plants of the Rocky mountains and neighbouring territories. Wild Rose College of Natural Healing Ltd, Calgary, AB: p.278.