

Discussion on robot-assisted laparoscopic cystectomy and Ileal neobladder surgery preoperative care

Daoxiu Zhang*, Mingyang Su, Chunlei Liu and Huiping Zhao

Collage of Urology, First Affiliated Hospital of Zhengzhou University, Zhengzhou, China

Abstract: To investigate the clinical applications of robot-assisted radical cystectomy with orthotopic ileal neobladder (RARC-INB) and make a preliminary summary. Retrospective analysis the clinical data of 12 patients underwent robotic bladder cancer (da vinci surgical system) assisted laparoscopic cystectomy with ileal orthotopic neobladder from March 2015 to April 2015. 12 cases were successful, with no surgical intervention, and organ damage occurred. The operation time was 330~470 min, which average (390.0±61.5) min; blood loss was 90~870 ml, which average (185.0± 88.3) ml. One case of intraoperative blood transfusion was 400 ml. The enjoin eating time of postoperative intestinal ventilation was 3~6 d, and the average time was (4.0±1.5) d. Removal of ureteral stents time was 14~28 d and the average time was (21±7) d. Removal of the catheter time was 18~28 d and the average time was (23±5) d. Postoperative hospital stay 19~29 d and the average time was (24±5) d. RARC-INB make the surgical tends to simplify, which was conducive to surgeon intraoperative control and assurance. RARC-INB make the surgical tends to use less trauma, less bleeding, complete lymphadenectomy, quick recovery, etc. It is a safe, effective and reliable the method in the treatment of invasive bladder cancer. So the method should be widely applied.

Keywords Robot; da vinci surgical system; laparoscopy; bladder cancer; cystectomy; ileal neobladder

INTRODUCTION

Radical cystectomy with ileal neobladder is currently standard surgical options of the treatment of muscle invasive bladder cancer, bladder infusion chemotherapy, and immunotherapy tolerance superficial tumors (Na,2009). In recent years, laparoscopic surgery has become an important means of treatment. With the development of medical technology, the progress of technology and the improvement of operation of the instrument, robot-assisted laparoscopic techniques are gradually showing the unique advantages in this field. And it gradually has become the development trend at home and abroad. We have 12 cases of bladder cancer underwent robot-assisted radical cystectomy with orthotopic ileal neobladder (RARC-INB) from March 2015 to April 2015. The following are early experiences we summarized.

MATERIALS AND METHODS

The clinical data

12 cases of bladder cancer group patients were male; 37 to 71 years old, and mean years were (57.5±14.2). Among them, 5 patients were first diagnosed; recurrent were 7 cases, in which 5 cases had transurethral bladder surgery 1 time with perfusion parallel, 1 case had transurethral bladder surgery twice eith parallel infusion, 1 case had undergone open surgical resection with intravesical parallel. Under Cystoscopy, we discover that tumor size were 3.7-8.9cm, 8 cases of multiple tumors, 4 cases of solitary; There were 5 cases of bladder tumor located at

the end zone, 4 cases of the side walls, 2 cases of anterior wall, 1 case of the top; The biopsy results were 11 cases of urothelial carcinoma, 1 case of squamous cell carcinoma example. Preoperative imaging (IVP/CT/MRI) on the cue is urinary abnormalities, bladder and no foreign invasion, pelvic lymph nodes and distant metastases. Preoperative WHO pathological grade: 2 cases of G1, 5 cases of G2, 5 cases of G3; TNM stage: 1 case of T_{2a} N₀ M₀, 2 cases of T_{2b} N₀ M₀, 5 cases of T₃ N₀ M₀.

Surgical methods

Preoperative patients underwent routine examination, patients with complications in previously treated accordingly. Patients began to oral antibiotics intestine before 3 d of operative, bowel preparation in parallel, intravenous nutrition from low-residue, semi-liquid transition to full liquid diet. Enema made before 3 d, 2 d nights of preoperative, fasting before 1 d of preoperative. Lavage with total intestinal, decompression surgery and indwelling catheter were stay on the morning of the operative date.

Position

Endotracheal intubation general anesthesia was successful F-18 indwelling catheter. The patient was supine, leg wear stockings knee slightly bent, lower limbs abduction, Trendelenburg was 20 to 30 degrees.

Operating channel connection establishment and equipment

Establish pneumoperitoneum at Target anatomical site from surgery on 15~20cm umbilical. The pressure was maintained at 12~15mmHg, piercing 12 mm Trocar, and

*Corresponding author: e-mail: zmac2015@sina.com

the hole was the lens aperture. Adjust the position and fix operating table; connect lens, respectively puncture under direct vision 1, 2, 3 robot arm Trocar; auxiliary Kong Jianli is located on the right of patients (1 to 2); adjust manipulator system bedside robot and move it to the appropriate location; connect and secure the camera arm and each hand Trocar. 1, 2, 3 arm curved scissors are connected unipolar, bipolar forceps and grasping forceps. See

Surgical procedures

Check to identify bladder urachal ligament, colon, iliac vessels, spermatic vessels, ureter and other anatomical landmarks and inner. Free bilateral ureteral: Found ureter in bilateral iliac artery bifurcation, which are free to outside of bladder wall and withhold from the off. Pelvic lymphadenectomy is bilateral external iliac vein, internal iliac artery, common iliac artery bifurcation, obturator nerve lymph nodes. Bladder and bowel along a line above the peritoneal pouch free vas deferens and seminal vesicles and prostate until interchange (cut vas deferens occlusion), bring forward on both sides of the vas deferens seminal vesicles, and transverse cut denonvillier fascia, free Denonvillier gap until the prostatic apex. Fold for umbilical inverted U-shaped incision peritoneum high separation at median umbilical fold and medial sides. Separate to retzius space. Reveal basin fascia and cut back in its fold line, separate since the side exposed to the midline of the levator ani muscle, carefully cut prostate pubic ligament which was close to the pubic, and fully revealed before prostate apex. Suture penile deep dorsal vein complex with "8" suture (dorsal vein complex, DVC) with 2-0 absorbable. Cut off bilateral ureteral bladder wall outside, free the bladder artery along the internal iliac artery, and clip off with Hem-o-lok. Pull forward the seminal vesicle of vas deferens. Carefully identified and cut close to the prostate capsule vascular pedicle until the prostatic apex denonvillier gap on the outside of the bladder and prostate side free vascular pedicle under direct vision in a straight line cutter. DVC has suture beneath along the distal tip off DVC exposure prostate urethra anterior, cut off lateral and posterior wall. Pull close to their rear free prostate and cut urethra muscle rectum which attached prostatic tip. Thus, bladder, prostate, seminal vesicles and vas deferens were resected completely. Do 4~5cm incision under the middle of the abdomen and remove the specimens. Pull bilateral ureteral and ileum. Take 40 cm ileum which has rich supply of blood at 15cm from the ileocecal and restore intestinal continuity, then put it into the abdominal cavity. Fold ileum W-fold and cut along the edge of mesangial, continuous suture inverted with 3-0 absorbable suture to form a new bladder, and anterior temporarily sutured. Trim sewing ureteral nipple, single-J tube placed in the bladder after new poke holes at the top drag on both sides. Replanted with 4-0 absorbable suture, and strengthened 2 fixed the new bladder outside 4-0 absorbable suture needle. Close the new bladder, and reserve base of about 1

cm opening for the new bladder neck. J tube distal end of the lead single from the new front wall of the bladder, drainage of urine until pull it external. The new bladder was put into the abdominal cavity, suture the abdominal wall, established pneumoperitoneum again, replace the needle holders, and suture bladder neck and urethra stump continuously under the guidance of new catheter by using 2-0 absorbable suture. Place drainage tube, withdraw each operation of the instrument and lens, separate removal arm and Trocar and remove Trocar.

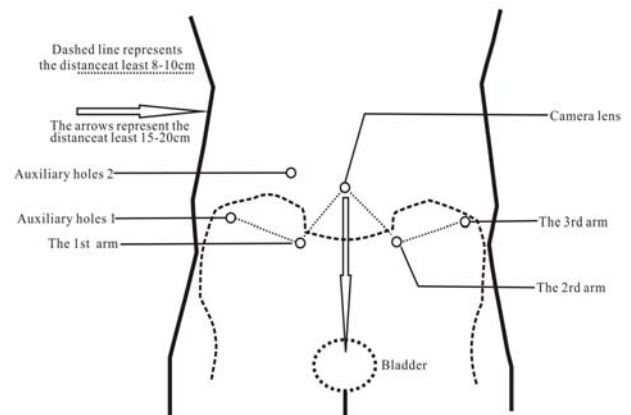


Fig. 1: Robot-assisted laparoscopic cystectomy schematic Trocar puncture site

After treatment

Maintain single-J tube, catheter, drainage tube patency through intravenous fluids and anti-inflammatory. Irrigate bladder was made 4-5 times/d under low pressure. Remove single-J tube and remove drainage tube and catheter after determines no urinary leakage. Then timed voiding of the patient is asked. Pelvic floor muscle training was according to the situation. Follow-up review as a regular.

RESULTS

12 cases were successful with no conversion to open surgery and other organ damage. The operation time were 330~470 min, and the average time were (390.0±61.5) min; blood loss were 90~870 mL, the average loss were (185.0±88.3) mL. One case of intraoperative blood transfusion was 400mL. Postoperative intestinal ventilation enjoin eating time 3~6 d, and the average time were (4.0±1.5) d. The time of removal of ureteral stents was after 14~28 d, and the average time was (21±7) d. The time of removal of the catheter time was 18~28 d, and the average time was (23±5) d. Stay at hospital 19~29 d at Postoperative, and the average time was (24±5) d. 4 cases of mild to moderate urinary incontinence, which were relieved by the levator ani training. Pathological findings: specimen margins were negative; 11 cases of squamous cell carcinoma; 1 case of the infiltration of urothelial carcinoma; 3 cases of pelvic lymph node-

positive; TNM staging: 1 case of T_{2a}N₀M₀, 4 cases of T_{2b}N₀M₀, 4 cases of T_{3a}N₀M₀, 2 cases of T_{3a}N₁M₀, 1 case of T_{4a}N₁M₀.

DISCUSSION

Laparoscopic cystectomy with pelvic lymph node dissection is the standard treatment for muscle invasive bladder cancer. It is effective treatment to improve the survival rate of invasive bladder cancer patients and avoid local recurrence and distant metastasis (Jakse *et al.*, 2006; Stein *et al.*, 2006). The basic indications were T₂-T_{4a} and N₀-X. It also includes M₀ invasive bladder cancer, high-risk non-muscle invasive bladder cancer T₁ G₃ tumors, BCG therapy ineffective T_{is}, repeated recurrence of non-muscle invasive bladder cancer, conservative treatment which can not control extensive papillary lesions, as well as retention bladder surgery after non-surgical treatment fails or relapse, and non-urothelial bladder cancer (Clark *et al.*, 2005; Jakse *et al.*, 2006).

The advantages of orthotopic neobladder are that patients can abdominal timed void or intermittent catheterization discharge clean urine without abdominal stoma. The disadvantage is that the presence of risk of recurrence of urinary retention and urinary tract cancer, such as tumor invasion of the prostatic urethra review which the increased risk is 35% (McDougal, 1998). Male patients are recommended to do routine inspection prostatic urethra, and female is recommended to do bladder neck biopsy before surgery. Do frozen section examination in intra-operative, or do urethral endoscopy and urinary cytology regularly after operate.

Compared with ordinary laparoscopic surgery, the robot has a unique deep operating, technology fine operation, which can greatly reducing the surgeon's labor intensity. It is particularly evident in a complex and time-consuming operation. It has clear vision and strong sense of hierarchy. It also can be more intuitive to observe the surgical field through the three-dimensional imaging after the surgeon. Arm vibration can be filtered and enhance the stability; Operating device has simulation wrist function, which can accurately place the various actions required to achieve, and reduce the difficulty of stitching in particularly. However, there is no advantage on tactile feedback (Wedmid *et al.*, 2011). The operation may appear excessive force, and that leads suture tear and suture breakage. It was widely used in foreign countries including pyeloplasty, cystectomy, vas deferens anastomosis which are surgical exposure difficult, and more difficult surgical operation. Bladder and prostate is located in the pelvic floor. The operation is difficult, isolated, hemostatic and sutures need higher requirements in particularly. Robot assisted laparoscopic play their strengths to protect the neurovascular bundle of free better (Tanaka *et al.*, 2014). So that it can protect the urinary function (Tewari *et al.*, 2010) and maintenance the purposes of erectile function.

The study belongs to the robot-assisted laparoscopic techniques to carry out early. Compared with general surgery laparoscopic cystectomy, in our experience, the docking located the puncture point and the robot system are essential before surgery. The distance of each robot arm between the puncture site should be maintained at least 8~10 cm or more distance between the lens and target organ which should be 15~20cm. Docking system should be fully in accordance with the rules implemented to ensure the accuracy of vision, flexible instruments during surgery, in order to avoid mutual interference in the surgical procedure.

Due to the small number of cases, we carry out this technique requires a certain degree of adaptation and learning curve at the beginning. The surgery time is longer than ordinary laparoscopic surgery (the same surgeon) from the results of this study (Wang *et al.*, 2012). With the improvement and familiarity of the surgical instrument systems, the operation time will gradually shorten. Similarly, as the same surgeon, compared with ordinary laparoscopic surgery, the difficulty of anastomotic suture the operation significantly reduced, and the consistent quality has improved significantly. Thus catheter retention time was significantly shorter than the ordinary laparoscopic surgery (Wang *et al.*, 2012). Free, bleeding, cutting and other actions of robot-assisted system under the space of the microscope were more precise than ordinary laparoscopic and delicate. Vice damage caused by the relevant also reduced. Despite being undertaken early, it was less blood loss, no rectal damage and obvious lymphatic leakage, small intestinal disturbances. Therefore, faster postoperative recovery of bowel function, and postoperative hospital stay time is short. It also has no positive margin.

We believe that RARC-INB makes surgery tended to be simplified, which will help the surgeon has intraoperative control and assurance. It has the characteristic of good reliability, safety, less bleeding, in patients with trauma, rapid recovery, complex pelvic surgery provides a favorable choice, which should be widely applied. Of course, since this group of patients is less, we only conducted a preliminary analysis and summary at the level of surgical treatment, and there was no long-term visit data (tumor control, urinary continence, erectile function, etc.). So the study needs further improvement and long-term to sum up. At the same time, from the perspective of health economics, the costs of health care of robotic systems are relatively high, which will ultimately affect their wider application. So it also requires a lot of practice and hard work.

REFERENCES

Clark PE and Hall MC (2005). Contemporary management of the urethra in patients after radical

- cystectomy for bladder cancer. *J. Urol. Clin. North Am.*, **32**(2): 199-206.
- Jakse G, Algaba F and Fossa S *et al* (2006). Guidelines on bladder cancer muscle-invasive and metastatic. *J. Eur. Assoc. Urol.*, 2004;172:1342-7.
- Mc Dougal WS (1998). Use of Intestinal Segments and Urinary Diversion[M] // Walsh PC, Retik AB, Vaughan ED Jr, *et al*. Campbell's u-rology, 7th ed. Philadelphia (PA): W. B. Saunders. pp.3162-3245.
- Na YQ (2009). Chinese diagnosis and treatment of urological diseases handbook. Beijing: People Health Press. pp.30-31.
- Stein JP, Quek KL and Sdinner DG (2006). Lymphadenectomy for invasive bladder cancer: 1. historical perspective and contemporary ration-ale. *J. BJU. Int.*, **97**(2): 227-231.
- Tanaka K, Shiqemura K and Hinata N *et al* (2014). Histological evaluation of nerve sparing technique in robotic assisted radical prostatectomy. *Indian J. Urol.*, **30**(30): 268-272.
- Tewari AK, Patel ND and Leung RA *et al* (2010). Visual cues as a surrogate for tactile feedback during robotic-assisted laparoscopic prosta-tectomy: posterolateral margin rates in 1340 consecutive patients. *J. BJU. Int.*, **106**(4): 528-536.
- Wang D, Liu J and Qiu MX *et al* (2012). Laparoscopic cystectomy surgery with ileal orthotopic neobladder clinical analysis of 62 cases. *J. Sichuan Medicine*, **33**(12): 2071-2073.
- Wedmid A, Llukani E and Lee DL (2014). Future perspectives in robotic surgery. *J. BJU. Int.*, **108**(6b): 1028-1036.