

Plasty of Human bites induced full thickness large area eyelid defects

Hong-yan Zhou¹, Wen-song Zhang^{2*}, Hong Zhang¹, Xunyi Gao¹ and Jie Wu¹

¹Department of Ophthalmology, China-Japan Union Hospital of Jilin University, Changchun City, China

²Department of Ophthalmology, The second hospital of Jilin University, Changchun City, China

Abstract: Large area eyelid defects induced by human biting was rare. A 43-year-old man was bitten by a human. His Blepharocoloboma size was 60% percent of the upper eyelid, the horizontal defect length of defect area was 25mm, the vertical height was 5mm, a small mass like lateral eyelid tissue was left on the Lateralis lid margin. The toughness of this lateral eyelid tissue was enough to support the lateral canthus tissue transferred to the same area. then the lateral eyelid tissue was sutured with the remaining sclera after which the sclera-conjunctiva was reconstructed. The skin tranfering from lateral canthus was sutured with conjunctiva without exposing. Eyelid defect was effectively repaired. The technique of lateralis cantholysis association with self remaining lateral eyelid tissue version was manifested an alternative and useful procedure for the reconstruction of large area upper full thickness eyelid defects.

Keywords: Eyelid defect; lateralis cantholysis; plastic

INTRODUCTION

A 43-year-old man was bitten by a human. He was taken to a local hospital where he was wrapped up. 6 hours later he came to our clinic. He was complaining his painful and bleeding left eye. Laboratory tests revealed white blood cell count was $13.5 \times 10^9/L$. His body temperature was $36.3^\circ C$ on admission. The patient was given rabies vaccine and tetanus immunization and was administered of cefuroxime 1.0g three times and metronidazole 250ml once daily before and after operation. Ophthalmologic examination revealed as follows: Right eye: Visual acuity was 0.8, Left eye: Visual acuity was decreased to 0.1. Eyelids were swollen and hyperemic. Blepharocoloboma size was 60% percent of the upper eyelid, the horizontal defect length of defect area was 25mm, the vertical height was 5mm, a small mass like lateral eyelid tissue was left on the Lateralis lid margin. Some secretion was along with the wound of the upper eyelid. Secretion in his upper lid should be a sign of inflammation. But Cultures of secretion showed negative results. A small amount of lateral eyelid tissue mass was left near to lateral canthus. The eyeball was integral. Slightly macula edema appears by fundus examination and spectral-domain optical coherence tomography (OCT) (fig. 1).

Lateralis cantholysis was carried out, the small mass like lateral eyelid tissue was pulled to the middle defect area after releasing from the periphery tissue, the toughness of this lateral eyelid tissue was enough to support the lateral canthus tissue transferred to the same area. Then the lateral eyelid tissue was sutured with the remaining sclera after which the sclera-conjunctiva was reconstructed. The skin tranfering from lateral canthus was sutured with conjunctiva without exposing. Eyelid defect was effectively repaired. Schirmer testing without anesthetic at

5 minutes resulted in 25mm of wetting in right eye and 8mm in his left eye. BUT testing resulted in 11seconds in right eye and 5 seconds in left eye. Topical artificial tears was applied for him. His dry eye symptom thus release. There is no symptoms of trichiasis, canthal dystopia and lagophthalmos. No more plastic surgery operations were needed (fig. 2).

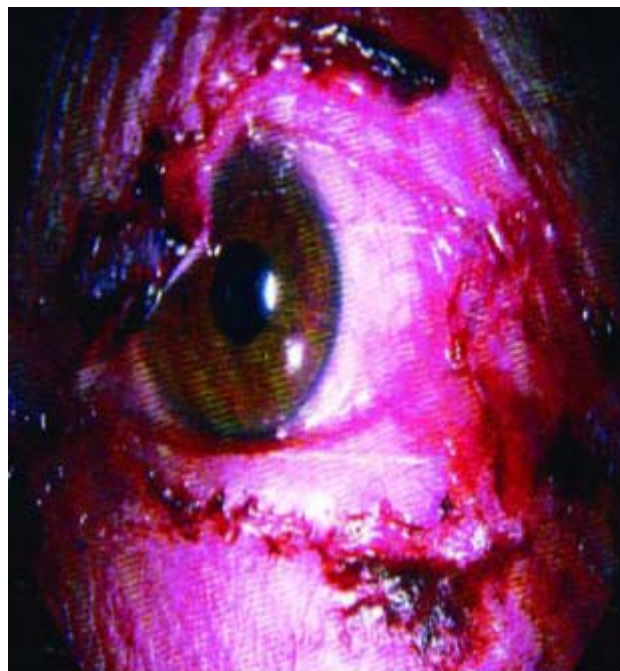

Fig. 1: Full thickness eyelid defect of the upper 175 eyelid induced by human biting in the left eye.

DISCUSSION

We report a case of human bites induced large area upper eyelid full thickness defects. The repair of this kind of trauma is a complicated procedure for the need of

*Corresponding author: e-mail: zhangzhou89@sina.com

cosmetology and functions requirements. We subtly utilize self remaining lateral eyelid tissue translocation to the defect area supporting the incisional lateral canthus tissue and reconstructing the upper lid rather than ectogenesis graft. This technique is reliable for the reconstruction of large area defect of upper eyelid. No more extra plastic surgery is requisite. Human bites induced eyelid defects is really rare. Bites resulted in localized infections including bacterial, parasitic, fungal, and viral diseases (Geffray, 1999). Human bites should be considered being infected (Sutherland, 2007). Reviews of human bites manifested that prophylactic antibiotics should be given to all patients with human bites which need injury prevention and early treatment. Bites and envenomations need proper and prompt protocols in clinical cases Rittner, Fitzpatrick, Corfield (2005). Best evidence topic report. Are antibiotics indicated following human bites. (Rittner 2005; Dahl 2011; Dusheiko, 1990; Andreo 2004; Figueiredo 1994; Janet Stockheim 2005). Secretion in the upper lid of this case maybe a signal of inflammation as above although the cultures of secretion showed negative results. Flap Repair, The acellular dermis composite graft, venous wall and skin graft, sclera homografts were efficacious method to maintain the structure and function of eyelid suffering from large area full thickness eyelid defects (Milap Mehta 2011; Gu J 2012; Gu 2012; Y Mi 1990; Krishnamurthy, 2011). But in this case, for the latency possibility of inflammation. This will be a risk factor for rejection and poor graft function. We prefer to reconstruct the eyelid defect by his own tissue. The influx of neutrophils and dendritic cells converged at localized damage sites including bites (Ribeiro-Gomes 2012. Naturally and artificially acquired immunity against bites need to be noticed (Diatlov 2011).

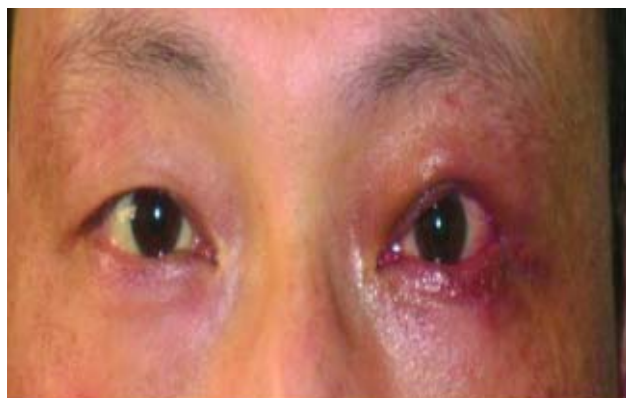


Fig. 2: Eyelid defect was effectively repaired by Lateralis Cantholysis technique association with lateral eyelid tissue version.

CONCLUSIONS

The technique of lateralis cantholysis association with self remaining lateral eyelid tissue version was manifested alternative and useful.

ACKNOWLEDGEMENT

Supported by Jilin University basic scientific research operating expenses fund (Research Fund of the Bethune B plan of Jilin University, 2012230); Supported by National Natural Science Foundation of China (No.81300727);

REFERENCES

- Andreo SM, Barra LA and Costa LJ (2004). *AIDS. Res. Hum Retroviruses*, **20**(4): 349-350.
- Dahl E (2011). Wound infections on board ship- prevention, pathogens and treatment. *Int. Marit. Health*, **62**(3): 186-190.
- Diatlov IA, Biketov SF and Firstova VV (2011). Perspectives of creation of vaccines against tick bite for nonspecific prophylaxis of vector borne diseases. *Zh. Mikrobiol. Epidemiol. Immunobiol.*, **4**: 101-106.
- Dusheiko GM, Smith M and Scheuer PJ (1990). Hepatitis C virus transmitted by human bite. *Lancet*, **336**(8713): 503-504.
- Figueiredo JF, Borges AS and Martínez R (1994). Transmission of hepatitis C virus but not human immunodeficiency virus type 1 by a human bite. *Clin. Infect Dis.*, **19**(3): 546-547.
- Geffray L (1999). Infections associated with pets. *Rev. Med. Interne.*, **20**(10): 888-901.
- Gu J, Zhai J and Chen J (2012). The use of acellular human dermis composite graft for upper eyelid reconstruction in ocular injury. *J. Trauma Acute Care Surg.*, **72**(1): 288-292.
- Janet Stockheim MD (2005). MPH human bites and blood exposures in New York city schools, *Clin. Pediatr. (Phila)*, **44**(8): 699-703.
- Krishnamurthy A and Vaidhyanathan A (2011). Switch flap' for full thickness upper eyelid reconstruction. *J. Cutan. Aesthet. Surg.*, **4**(2): 148-150.
- Mehta M and Julian D Perry (2011). Semicircular flap repair of full-thickness eyelid defects using only anterior Lamella. *Invest Ophthalmol. Vis. Sci.*, **52**: 739.
- Min Y (1990). Blepharocolobomarepaired with preserved scleral homograft. *Zhonghua. Yan. Ke. Za. Zhi.*, **26**(6): 346-348.
- Ribeiro-Gomes FL, Peters NC and Debrabant A (2012). Efficient capture of infected neutrophils by dendritic cells in the skin inhibits the early anti-leishmania response. *PLoS Pathog.*, **8**(2): e1002536. Epub 2012 Feb
- Rittner AV, Fitzpatrick K and Corfield A (2005). Best evidence topic report. Are antibiotics indicated following human bites? *Emerg. Med. J.*, **22**(9): 654.
- Sutherland NN (2007). Human Bites in the Classroom: Incidence, Treatment and Complications. *J. Sch. Nurs.*, **23**(6): 362.