

# Modified kloen approach treatment for acetabular fractures

Shunli Xu<sup>1</sup>, Xiang Lv<sup>2</sup> and Yisheng Wang<sup>1\*</sup>

<sup>1</sup>Department of Orthopaedic Surgery, The First Affiliated Hospital of Zhengzhou University, Zhengzhou City, PR China

<sup>2</sup>Department of Orthopaedic Surgery, The Red Cross Hospital of Huojia County, Zhengzhou, China

**Abstract:** To evaluate the feasibility and efficacy of modified Kloen approach for the treatment of acetabular fractures through lateral window exposure beneath fascia iliaca with superior ramus of pubis exposure by internal small incision. Matta radiological criteria was employed to evaluate the post operation recovery, and modified D'Aubigne-Postel evaluation system was adopted for demonstration of hip joint function condition. There is no incision infection, neurovascular trauma or postoperative lymphorrhagia. 42 patients cooperated with the following up of 11.2 months. The average bone healing time was 13 weeks. Matta radiological criteria was to evaluate the postoperative fracture quality, 18 case with excellent recovery, 16 cases with good recovery, 4 cases with normal recovery and 1 case with bad recovery. Modified D'Aubigne-Postel evaluation was taken 6 months after surgery, 17 cases with excellent recovery, 22 cases with good recovery, 2 cases with normal recovery and 1 case with bad recovery. There was no internal fixation loosening, breakage or inguinal hernia. The modified Kloen approach can improve iliofemoral vascular activity, exposure range for restoration and fixation. Besides, the exposure of articular surface could ensure the condition of restoration quality, and avoid the incidence of postoperative hernia.

**Keywords:** Acetabular fractures, surgical procedures, modification.

## INTRODUCTION

In 2002, Kloen put forward the modification on classical ilioinguinal approach (Kloen *et al.*, 2002; Letournel, 1980), with the initial purpose for treating anterior column fractures of acetabular anterior wall and low part. The limitation from inguinal ligament was avoided by the employment of anterior superior spine osteotomy. The lateral window exposure was obviously expanded through intraoperative operations on hip flexor, while the combination of center and internal windows exposure was equally fit for general acetabular anterior column, transverse fractures and other types of fractures (Kloen *et al.*, 2002). This approach has been applied in the treatment of acetabular and pelvic fractures since 2010. Through clinical observation, the lateral segment delineation of Kloen approach was quite obscure and difficultly controlled. One-screw adoption on osteotomy fixation has the poor stability with longer postoperative bracing time, going against patients' postoperative rehabilitation exercises. For the internal part, the canalis inguinalis still required incision while iliofemoral vascular required separation, which may result with vascular trauma and postoperative lymphatic leak and hernia. Through autopsy studies, we modified this approach and applied it into clinic. Our department adopted modified Kloen approach in the treatment for 42 cases acetabular fractures in The First Affiliated Hospital of Zhengzhou University from Jan. 2012 to December 2014. The satisfactory results were achieved and reported as follows.

\*Corresponding author: e-mail: zmabc2015@sina.com

## MATERIAL AND METHOD

### General cases

There were 42 cases of patients suffering acetabular fractures adopted modified Kloen approach treatment in The First Affiliated Hospital of Zhengzhou University from January 2012 to December 2014, including 26 cases of male patients and 16 cases of female patients. The mean age was 34.5 years old, ranging from 15-70 years old. The injury reasons were 15 cases in traffic trauma, 24 cases in high falling injury, 3 cases in weight crushing. In fracture types, there were 1 case for ipsilateral femoral neck fracture, 6 cases for multiple rib fractures, 1 case for patella fractures, 3 cases for craniocerebral injury, 1 case for lumbar vertebral fracture. Based on Judet-Letournel classification, 1 case was for anterior wall fracture, 18 cases for anterior column fracture, 15 cases for transverse fracture, 3 cases for T-shape fracture and 5 cases for both column fracture. In total, 34 cases, which applied single modified Kloen approach, 8 cases applied combined Kocher-Langenbeck approach. The time to get surgery since got injured was 1 to 9 days, average 5.5 days. Lag screw and general pelvic were utilized in internal fixation to reconstruct steel plates. The patients' demographics were as shown in table 1.

### Surgery method

Postoperative enema, retention catheterization and shaving skin were conducted under supine position, with 20 to 30 degree elevation from shoulder to hips, in order to assist pelvic organs moving towards the uninjured side. The lower limbs were disinfected for intraoperative convenient movement. Skin incision was made along anterolateral iliac crest from the front and back of

tuberculum iliacum to anterior superior spine and then extending about 5-8cm towards the internal and below part of sartorius muscle (fig. 1a). Superficial fascia separation and iliac crest, anterior superior spine and sartorius muscle exposure (fig. 1b). Ilioinguinal and iliohypogastric nerves of the upper part and superficial lymph nodes of the lower part should be avoided being injured. Nervus cutaneus femoris lateralis was firstly separated from the lateral border of sartorius muscle, with rubber band marks protection. Then, attachment sites exposing sartorius muscle and inguinal ligament on anterior superior spine were separated; osteotomy was made for anterior superior spine, with the bone size standard of covering the overall sartorius muscle starting point and 2-screws reliable implantation (fig. 1c). Towel clips were applied by assistants to pull through the internal part while the protect role was played by surgeons who stretched fingers beneath fascia iliaca during this process. Sharp knives were used to cling closely to the medial margin of crista iliaca to cause the separation of fascia iliaca and abdominal muscle adhesion. The above structures were dragged toward the internal part through drag hooks, bring iliopsoas and femoral nerves exposure. Hemostasis through electrocauterization for branches of circumflex iliac profound vessel should be noticed and made. Hip joints adduction was made through suitable flexion, bringing an internal expansion beneath fascia iliaca to sacroiliac joint and lesser pelvis margin. For iliac shame bump or squares fractures, iliopectineal arch and inguinal ligament should be separated at fusion sites to furtherly loose iliac blood vessels. Straight head of rectus femoris muscle was dragged internally or joint capsule was exposed after the incision on the position away from anterior inferior spine starting point. After conventional T-shape incision for joint capsule, femoral head was laterally dragged, rotated and moved to expose the articular surface of hip joints. Restoration under direct view and treatment for abnormal changes (such as femoral head cartilage injury and bone block dissociation) within joints (fig. 1d) were made. Exclusive surgical instruments and restoration skills were fully employed to ensure the possible levelling of articular surface.

The fractures involving superior ramus of pubis or steel plate, the fractured bones should be fixed on superior ramus of pubis and supplemented by internal incision. Touched by the surgeon's finger, the outer cycle mouth was marked and incised for about 2-3cm on lateral part. Superior ramus of pubis was touched by blunt dissection of superficial fascia to expose lacunar ligament and keep its integrity. Bone marrow was incised on superior ramus of pubis, sneak separated and connected with the lateral incision through the fixation by putting steel plate (fig. 1e).

Wounds were irrigated by normal range sterile saline (>3000mL) through impulse. Broken skeletal and sludged blood were washed down to decrease the possibility of

heterotopic ossification and infection. Joint capsule, rectus femoris (when been cut) and iliopectineal arch were sutured. Osteotomy block were fixed longitudinally or transversely by steel plate according to the stability of iliac ala fractures. Femoral fascia and abdominal muscle were sutured to occlude wounds. For internal incision occlusion, fascia was orthostatic sutured or occluded by inferior patching. Negative pressure was conventionally set to carry out drainage. Both column and T-shape fractures were restored and fixed through Kocher-Langenbeck approach.

#### ***Postoperative management***

Celecoxib tablets were used to relieve pain and prevent heterotopic ossification until postoperative 6 weeks after 2 days of postoperative using analgesic pump. Antibiotic was adopted for 3-7 days based on compound injury; active systolic-diastolic motion of double limbs by wearing anti-rotation shoes for immobilization in the first three days after operation; CPM application was given after 3 days. Deep venous thrombosis was prevented through regular air pressure pump and low molecular heparin calcium. Affected limb motion without weight bearing was made by double crutches after half-month postoperative taking out stitches; 8 week postoperative part limb motion with weight bearing was made. Two postoperative reexaminations were made after 3 and 6 month respectively. Further exercise plan was decided according to the reexamination situation.

#### ***Postoperative follow-up and therapeutic evaluation criteria***

Patient database was established and regular reexamination was conducted by specially-assigned hospital staff. Conventional reexaminations were arranged in the 3<sup>rd</sup> month, 6<sup>th</sup> month, 12th month and the 2<sup>nd</sup> year. Re-examination was performed in hospital once patients felt uncomfortable. Matta radiology quality criteria was adopted for evaluation the postoperative fracture, and modified D'Aubigne-Postel marking system was utilized to evaluate hip joint function (Chen *et al.*, 2013).

## **RESULTS**

The mean operative time for patients was 90 minutes (60-160 minutes); the mean bleeding volume was 530mL (400-1050mL). No incision infection, neurovascular trauma nor postoperative lymphorrhagia happened. An average 11.2 months (6-21 months) long follow-up visit was given to all patients while the average bone healing time was 14 weeks. Postoperative restoration quality was evaluated by Matta criteria for acetabular fractures: 18 excellent cases, 6 good cases, 4 pretty good cases, 2 bad cases were achieved in this study. According to modified Merle D'Aubigne-Postel marketing system, hip functions were excellent in 17 cases, good in 22 cases, pretty good in 2 cases, bad in 1 case in 6 months after operation. No internal fixation loosening or breakage nor inguinal

**Table 1:** The patients' demographics

Total (42 cases)	Male (26 cases)	Female (16 cases)
Age		15-70 years old
Mean age		34.5 years old
Injury reasons	Traffic trauma	15 cases
	High falling injury	24 cases
	Weight crushing	3 cases
Fracture types	Ipsilateral femoral neck fracture	1 case
	Multiple rib fractures	6 cases
	Patella fractures	1 case
	Cranio-cerebral injury	3 cases
	Lumbar vertebral fracture	1 case
Based on Judet-Letournel classification	Anterior wall fracture	1 case
	Anterior column fracture	18 cases
	Transverses fracture	15 cases
	T-shape fracture	3 cases
	Both column fracture	5 cases
Applied single modified Kloen approach		34 cases
Applied combined Kocher-Langenbeck approach		8 cases
The time to get surgery since got injured		1 to 9 days
Average time		5.5 days

**Table 2:** Operative records

Mean operative time		90 minutes
Mean bleeding volume		530mL
Results		No incision infection, neurovascular trauma nor postoperative lymphorrhagia happened
The average bone healing time		14 weeks
Matta criteria for acetabular fractures	Excellent	18 cases
	Good	6 cases
	Pretty good	4 cases
	Bad	2 cases
Merle D'Aubigne-Postel marketing system	Hip function in excellent	17 cases
	Hip functions in good in	22 cases
	Hip functions in pretty good	2 cases
	Hip functions in bad in	1 case
Results		No internal fixation loosening or breakage nor inguinal hernia. 1 case of femoral head necrosis and traumatic osteoarthritis and was given total hip replacement arthroplasty

hernia. 1 case of femoral head necrosis and traumatic osteoarthritis and was given total hip replacement arthroplasty (as shown in table 2). Typical cases figs. were displayed in fig. 2.

## DISCUSSION

Acetabular fracture was intra-articular fractures of lower limb weight-bearing joints; Excellent efficacy for such fractures majorly depended on high-quality restoration and reliable internal fixation which required good approach and exposure (Wang *et al.*, 2014). Classical ilioinguinal approach was performed on inguinal ligament. Due to the inguinal ligament limitation, the approach could not fully expose hip joint, only the

indirect restoration was advisable, the separation and traction of iliac vein and deep lymphatic tissue could easily cause intraoperative vascular injury, postoperative arterial-venous thrombosis and lymphatic leak. The inguinal canal incision increased the possibility of postoperative inguinal hernia (Farid, 2008). Ilioinguinal approach from Farid was a complete three-window exposure beneath inguinal ligament and easily caused postoperative neuralgia or sensory disability due to the direct lateral femoral cutaneous nerve incision during operation; the separation of external iliac blood vessels and femoral blood vessels beneath inguinal ligament could increase the vascular injury risk and caused multitype femoral hernia incidence due to the destruction on pectineal muscle. Kloen approach adopted

anterior superior spine osteotomy, relieved inguinal ligament limitation, fully exposed low anterior column and anterior wall fractures, and significantly expanded the exposure range of lateral window through intraoperative hip flexor. However, lateral description of Kloen approach was quite obscure and uneasily to be controlled; one-screw fixation on bone cutting piece had poor stability with longer postoperative breaking time, which went against patients' restoration exercises; the inguinal canal incision and iliofemoral vascular separation in internal part might cause vascular injury and postoperative lymphatic leak and hernia. Through the autopsy research (Xu *et al.*, 2014; Xu *et al.*, 2015; Xu *et al.*, 2014), the Kloen ilioinguinal approach was modified based on the above advantage and disadvantage of above method.

Firstly, Kloen described that the surgical position was horizontal position, and the incision was the lateral of inguinal area, and surrounding the iliac spine and downside for 100 degree and oblique line inside. The above description was not easy and accurately to understand. The injured side was elevated 20-30 degree, going sartorius direction, then going along with sartorius direction; the elevation of injured side was easy to expose the shift of pelvic cavity viscera. The natural shift of abdominal wall enabled postoperative incision have distance from bone, and avoided the scar friction. The extruded bone structure and clear sartorius was easy to understand and grasp.

Secondly, the construction of inguinal ligament, iliopectineal arch and sartorius formed the protection and restraint function against external iliopsoas, nervus femoralis and internal iliofemoral vascular (Oeckl and Hohenberger, 2011). The intraoperative separation removed the constraint function, further eased the iliopsoas, nerve and blood vessels, greatly expanded the exposure surgical area for further convenient and good reduction and fixation. In most cases, the separation and traction of blood vessel was unnecessary, thereby reduced the complication of vascular and lymphatic system.

Thirdly, abdominal muscle had the protective effect on the stability of pelvic ring. The direct crista iliaca sharp dissection was easy to postoperative stitch (Ghanayem *et al.*, 1995). As the partial attachment points of abdominal muscle, the integrity of inguinal ligament was indispensable for the function of abdominal muscle. The directly abscission of inguinal ligament could cause tear again and tension. The osteotomy did not destroy the integrity, easy to restore its tension through suture iliopectineal arch, cut bone fixation. Steel double cortical screw fixation had better effect on single screw longitudinal fixation, and helpful for early functional function rehabilitation training, which was significant for postoperative function recovery (Wu *et al.*, 2010).

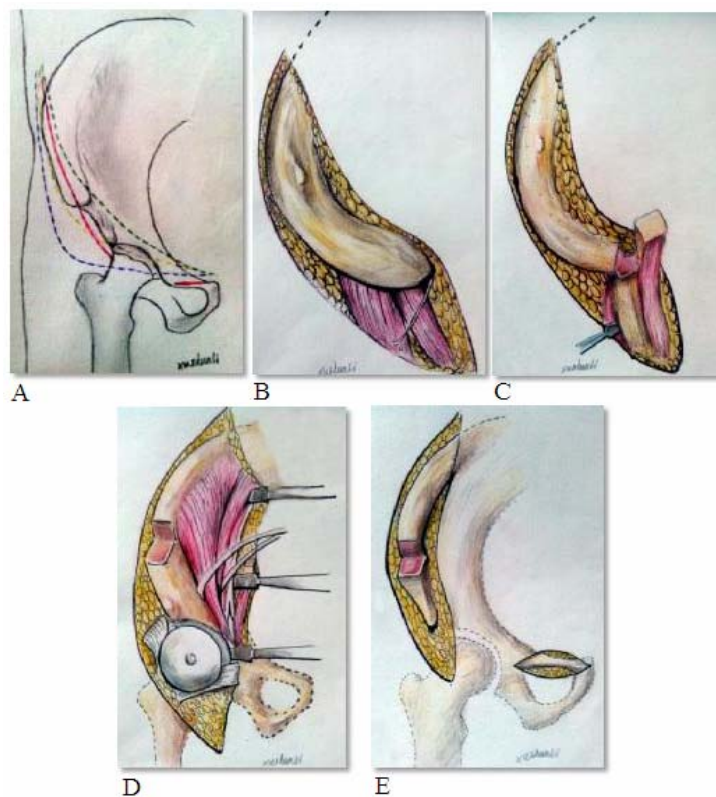
Fourthly, the preliminary autopsy demonstrated that iliopectineal arch at iliopubic eminence was with strong combination, not easy for exfoliation (Xu *et al.*, 2014). The incision could easily injure the iliac artery at inner side, and unable to rebuild after stripping, caused the inguinal ligament tension. Iliopectineal arch formed an angle at the coalesce area of inguinal ligament, where was filled by loose connective tissue, easy to separate and suture postoperatively.

Fifthly, nervus cutaneus femoris lateralis in fossa iliaca spread inside or outside of the fascia iliaca, and oblique lining from inside upward to outside downward. The integrity of fascia iliaca could not heart the nerve (Xu *et al.*, 2014). Studies had found that lateral cutaneous nerve of variation across the iliac crest (Gao *et al.*, 2006). Although the previous anatomic and clinical surgery did not had this variation, the far distant separation and protect the nervous could avoid injury.

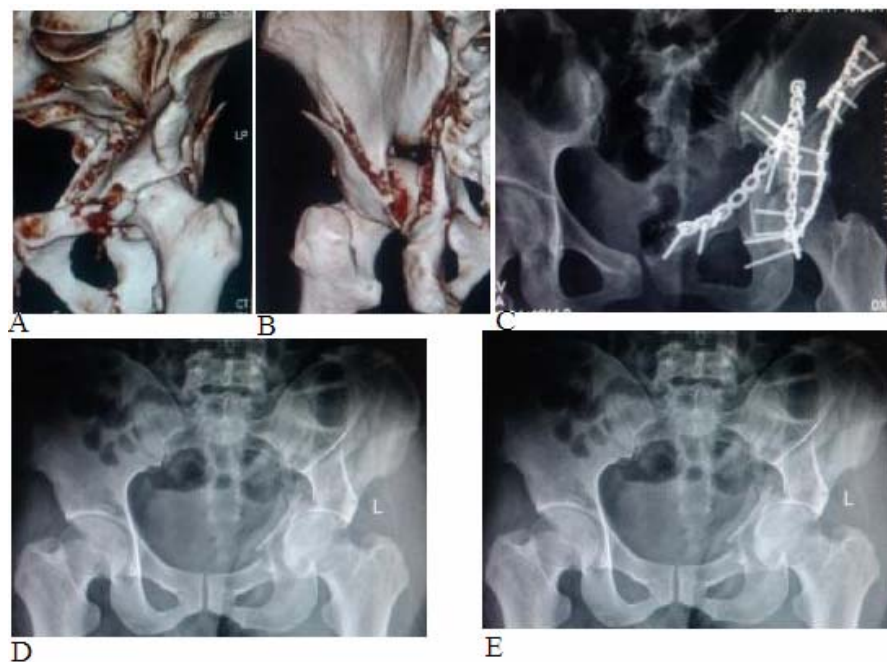
Sixth, the directly incision of lacunar ligament not only could injure the ventral abdominal artery and obturator artery, and difficult to rebuild its tension when been cut, due to the weak at the medium area. Through the autopsy, Shiwen Zhu *et al* (2010)observed that the area of anastomosis vascular had a certain activity while crossing the pubic area, and supposed that upper wall pubic branch was exposed in acetabulum fracture surgery, as long as the subperiosteal operation was performed, it would not easily injure the anastomosis. Through preliminary autopsy, the tensile structure was detected between lacunar ligament and pectineal muscle fascia. The upper pubic exposure could keep the integrity of lacunar ligament, and detected from pectineal muscle fascia. The direct suture fascia could be done after slight removal of further distant fascia after the steel plate was placed. The fascia structure was density to tolerate thread tension membrane structure and not easy to tear off. If the difficult of stitching was due to the thickness of the steel plate restriction, the low repairing hernia surgery method should be taken.

Finally, the no incision inguinal ligament avoided the postoperative hernia incidence. The locally separation of lower area of pubic bone muscle could avoid the risk of postoperative femoral hernia.

Acetabulum fracture belonged to intra-articular fractures. Due to the special three-dimensional morphological structure, the indirect reduction was difficult to guarantee the smooth surface joints. The direct reduction was beneficial to the articular surface recovery and articular cartilage lesions in the early treatment (Maini *et al.*, 2014). the reset joint surface under regular joint capsule incision could handle the intra-articular lesions, as much as possible to ensure quality of reset to facilitate the curative effect of future recovery. Although there was still



**Fig. 1:** Modified Kloen approach: a. comparison between four types of approaches; b. crista iliaca, anterior superior spine and sartorius were incised and exposed along the line feed of sartorius muscle; c. anterior superior spine, sartorius muscle and inguinal ligament osteotomy; d. ace tabular fractures was restored under direct view through hip joint exposure; e. superior ramus of pubis was exposed by internal incision attachment and then placed with steel plate.



**Fig. 2:** a-c. 32 years old female patient with heavily comminuted front-back fractures, poor results of intra-articular restoration under direct view and fair weight bearing area and anaphase functions; d-e. 36 years old male with front-back fractures, excellent results of intra-articular restoration, steel plate fixation on osteotomy position and excellent anaphase functions for early exercises.

a unsatisfactory reset, it was related to the particularity of pelvic morphology and insufficient reset related skills and experience. Further more, the purpose of modified approach was to improve the exposure effect with minimum injury. The combined K-L approach was advised for difficulty reveal of T-shaped column and back column after fractures (Letournel, 1980). Modified Stoppa approach was recommended for quadrilateral body fracture related superior to small pelvis or fracture requiring screw fixation from inside to outer side area (Kim *et al.*, 2015).

## CONCLUSIONS

Clearly mention the advantages, disadvantages and limitations of the study in the section of Conclusion.

## REFERENCES

- Chen G, Ou Y and Chen Z *et al* (2013). Modified ilioinguinal approach for the treatment of acetabular anterior wall fractures. *Chinese J. of Orthop. Traum.*, **15**(11): 956-960.
- Farid YR (2008). The subinguinal retroperitoneal approach for fractures of the acetabulum: A modified ilioinguinal approach. *J. Orthop. Trauma.*, **22**(4):270-275.
- Gao MT, Jiang DM and Gao SM (2006). Applied anatomy and Anat and nerve entrapments symptom complex for lateral femoral cutaneous nerve pelvic outlet. *Clin.*, **11**(2): 84-85.
- Ghanayem AJ, Wilber JH, Lieberman JM and Motta AO (1995). The effect of laparotomy and external fixator stabilization on pelvic volume in an unstable pelvic injury. *J. Trauma.*, **38**(3): 396-401.
- Kim HY, Yang DS, Park CK and Choy WS (2015). Modified Stoppa approach for surgical treatment of acetabular fracture. *Clin. Orthop. Surg.*, **7**(1): 29-38.
- Kloen P, Siebenrock KA and Ganz R *et al* (2002). Modification of the ilioinguinal approach. *J. Orthop. Trauma.*, **16**: 586-593.
- Letournel E (1980). Acetabular fracture: Classification and management. *Clin. Orthop.*, **151**: 86-106.
- Maini L, Batra S, Arora S, Singh S and Gautam VK (2014). Surgical dislocation of the hip for reduction of acetabular fracture and evaluation of chondral damage. *J. Orthop. Surg. (Hong Kong)*, **22**(1): 18-23.
- Oeckl K and Hohenberger W (2011). Modified incomplete Sartorius muscle flap for femoral vessel protection. *Chirurg.*, **82**(10): 936-941.
- Wang ZG, Qu TN, Cui SH and Chen HY (2014). Analysis of influencing factors for hip joint function restoration after acetabular fracture operation. *Chinese Bone and Joint Surg.*, **7**(6): 486-490.
- Wu XB, Zhang Q and Song LX *et al* (2010). The influence of early rehabilitation on postoperative function of acetabulum posterior wall comminuted fracture. *Chinese J. of Clin. Rehab.*, **14**(4): 732-735.
- Xu SL, Lv X, Liu ZG and Wang YS (2014). Anatomy research for inguinal approach beneath myopectineal orifice lower area. *Chinese J. of Clin. Anat.*, **32**(6): 648-651.
- Xu SL, Lv X, Wang YS, Li Y and Zhang H (2015). Risk of inguinal approach for the treatment of acetabular fracture. *JPr. Orthop.*, **21**(1): 50-53.
- Xu SL, Zhao XS, Lv X and Wang YS (2014). Centre window dissection and modification for ilioinguinal approach. *Acta Anatomica. Sinica.*, **45**(6): 819-823.
- Zhu SW, Sun DJ and Wang MY *et al* (2010). Anatomy researches for Corona mortis. *Shandong. Med. J.*, **50**(44): 28-29.