

REPORT

Report on the heterozygosis mutations of c.567dupT, p.(Ile190Tyrfs*13) of MMAHC gene in 1 Child patient with methylmalonic academia

Kai Liu, Guohong Chen, Yanli Ma, Yixin Xian and Zhang Zhang

Department of Pediatric Neurology, Zhengzhou Children's Hospital, Henan, China

Abstract: This article reported 1 child patient with early-onset methylmalonic acidemia and proceeded gene detection for the child and his parents. The detecting results showed that there were respectively heterozygosis mutations of c.609G>A,p.(Trp203*) and c.567dupT,p.(Ile190Tyrfs*13) in the MMA HC gene of child's parents, and all of the diseases were entailed to the child and caused the paroxysm of child. Consequently, the c.567dupT,p.(Ile190Tyrfs*13) was considered as a kind of new gene mutation. After being treated with vitamin B12 and levocarnitine, the clinical symptoms and organic acid content of hematuria of this child patient had taken a turn for the better.

Keywords: Methylmalonic acidemia; MMAHC gene; heterozygosis mutations of c.567dupT,p.(Ile190Tyrfs*13)

INTRODUCTION

Methylmalonic acidemia is one of the most common congenital metabolic diseases of organic acid in nationwide child patients. cblC is the most common type of MMA. The occurrence of mutations in any location of MMA HC gene may give rise to the metabolic disturbance of cobalamin, cbl, VitB12 and abnormal accumulating of multiple intermediate metabolites, which include isosuccinic acid, methyl citric acid, occur in child patients. And multiple systems of body will be damaged. The application of mass-spectrometric techniques: Tandem mass spectrum and gas chromatography helps fast and accurately make the diagnosis. And the gene detection techniques helps provide reliable bases for the subtypes, treatment, prognosis and antenatal diagnosis of diseases. This article reported 1 child patient with rare mutation site of MMAHC gene and provided bases for the genetic diagnosis.

Clinical material

This child patient was male, one month and 23 days old. Low increase in body weight was the main cause of hospitalization. The birth weight of this child patient was 3.25Kg. He was fed by mixed feeding. 1 month later, his weight was 3.5Kg, the patient occurred feeding intolerance and could not eat up the breast milk. The child started emesis and acidic odor in excrement without long-term fever, diarrhea and convulsion. Prior to admission, the measurement for his weight had no obvious increase than birth weight, and the blood routine examination showed that RBC was 2.37×10^{12} , HGB was 79g/L and HCT was 25%. Therefore, this child patient was defined

as malnutrition and anemia and hospitalized. The pre-admission physical examination results: stature of 54 cm, weight of 3.32Kg, head circumference of 36 cm, subcutaneous fat of 0.6 cm, pale skin with poor elasticity, obvious signs of hyper pigmentation on skin of both lower extremities, overlap in sutura cranil, soft bregma with approximate size of 1.5 cm \times 1.5 cm, no signs of cleft palate and malformation found in oral cavity, no anabrosis and erosion found, mild neck without resistance, no abnormal signs found in cardiopulmonary and abdominal parts, normal indexes of muscular tension and myodynamia of limbs, existence of tendon reflex with ability to proceed eye tracking and hearing tracking. Then do post-admission relevant auxiliary examination; the hint from TORCH examination showed that the cytomegalovirus presented IgG positive; The hint from detection of food intolerance showed that moderate intolerance to milk; normal indexes in functions of blood biochemistry (referred to hepatic and renal functions, myocardial enzyme and electrolyte) and thyroid; The color Doppler ultrasound for heart showed that foramen ovale did not occlude. Treatments of collecting blood PH value, supplementing nutrient solution by venous transfusion and feeding deep hydrolyzed milk powder by nasal feeding were arranged after admission. Repeatedly monitoring for arterial blood gas analysis showed that the metabolic acidosis took a turn for the better and levels of blood ammonia and lactic acid returned to normal levels. But the child patient still could not suck the milk himself, and no signs of thickening in subcutaneous fat were found. By means of combining the state of child's illness with the inspection result, the inherited metabolic disease was taken into consideration. Then the hematuria specimen of child was sent to Jinyu inspection center for

*Corresponding author: e-mail: zmabc2015@sina.com

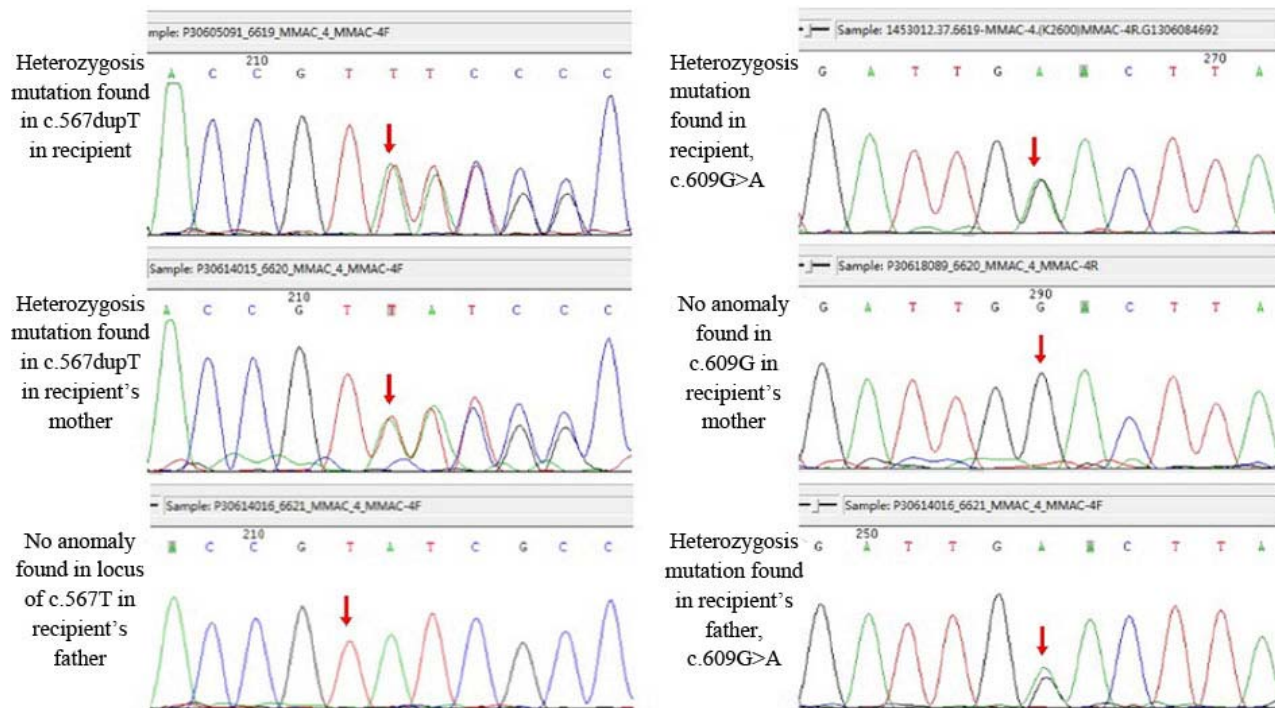


Fig. 1: Heterozygosis mutations in recipient and recipient's mother and father

genetic metabolic screening by taking advantage of high-performance liquid chromatography-tandem mass spectrometry. The results of blood specimen showed the disease might be methylmalonic acidemia or propionic acidemia. The results of urine specimen showed that value of isosuccinic acid was 159.8uM (Reference value was from 0.2 to 3.6uM) and value of methyl citric acid was 3.4uM (Reference value was from 0 to 1.1uM), both values of them increased. Therefore the methylmalonic acidemia was taken into superior consideration. After communicating with the parents, the gene detection was arranged to them. The gene detection results showed that no pathogenic mutation was found in exon code area of MUT, MMAA and MMAB genes, two heterozygosis mutations: c.567dupT, p.(Ile190Tyrfs*13) and c.609G>A, p. (Trp203*) in MMACHC gene were found. Further detection to the gene of parents was arranged. The results showed that the child's mother carried heterozygosis mutation of c.567dupT, p. (Ile 190Tyrfs*13) and the mutation belonged to frame shift mutation; the child's father carried heterozygosis mutation of c.609G> A, p. (Trp203*). By means of combining the inspection results of hematuric metabolism, the child patient was diagnosed as methylmalonic acidemia of Type cblC. Then the child patient was treated injections of vitamin B12 and levocarnitine for 5 days. Consequently, the reexamination results of blood metabolism revealed that the specific value between propionyl-carnitine and acetyl-carnitine reduced to the normal lever but the clinical manifestation of child patient did not improve markedly. Therefore the

patient left hospital without cure. The periodical following-up visits were arranged after the child patient discharged from hospital, it is found that there still was feeding difficulty to this child patient and the value of child's weight had no obvious increase.

DISCUSSION

In this case, this child patient came on the disease 1 month after his birth and appeared symptoms of feeding difficulty, body weight standing the same, malnutrition and pancytopenia. After being treated with injections of vitamin B12 and levocarnitine, the re-examination results of blood and organic acid metabolism returned to normal levels but the clinical manifestations did not take a turn for the better, neither were the results of regular following-up visits, which was relative consistent with the manifestations of early-onset methylmalonic acidemia of Type cblC.

In our country, the mutation of Type c.609G>A(W203X) was most frequent and common and belonged to hot spot mutation. Otherwise, there were also some reports on Type c.482G>A, c.217C>T, c.80A>G, c.347T>C, c.470G>C and other types and most of them were nonsense mutations and missense mutations (Mei-Ying *et al.*, 2010).

In this case, the child patient was proceeded gene detection. The results of gene detection revealed that no

pathogenic mutations were detected in exon code areas of MUT, MMAA and MMAB genes, and the mutations of rs2229384 (heterozygosis mutations), rs9395492 (heterozygosis mutations), rs7769646 (heterozygosis mutations), rs1141321 (heterozygosis mutations), rs9473557 (heterozygosis mutations) and rs8589 (heterozygosis mutations) of MUT gene and the mutations of c.1089G>C,p. (Gln363His), rs2270655 of MMAA gene were known polymorphic sites and could not be pathogenic at all; two heterozygosis mutations of MMACHC gene were found, they were c.609G >A,p. (Trp203*) and c.567dupT,p.(Ile190Tyrfs*13). Further detection was arranged to detect the c.609G site and c.567T site of the child patient's parents, the detection results showed that the child patient's mother carried heterozygosis mutations of c.567dupT,p. (Ile 190Tyrfs*13) and the mutations belonged to frame shift mutations; the child patient's father carried heterozygosis mutations of c.609G>A,p. (Trp203*) and the mutations belonged to reported mutations. Due to the reason that MMA was an autosomal recessive genetic disease, this child patient was diagnosed as MMA. Considering that this child patient's father carried heterozygosis mutations, thereby the heterozygosis mutations of this child patient's mother should be the pathogenic mutations. But there were no relevant reports on this case in domestic, and only one report was issued by Chang *et al.* (2011) in Taiwan.

In conclusion, in this report, the child patient was clearly diagnosed as early-onset methylmalonic acidemia of Type cb1C by means of taking advantage of tandem mass spectrum, gas chromatography-mass spectrum and gene detection, which provided the child's parents basis for antenatal diagnosis. This article also found that there were no relevant reports on the new gene mutation sites in domestic. With regard to the reason that the biochemical criterion of this child patient with early-onset methylmalonic acidemia of Type cb1C returned to normal level but the clinical manifestations did not improve after being treated with vitamin B12 and L-carnitine still need further discuss and explore. The data supports from Zhengzhou Jinyu Inspection Center!

REFERENCES

- Chang JT, Chen YY and Liu TT *et al* (2011). Combined methylmalonic aciduria and homocystinuria cb1C type of a Taiwanese infant with c.609G>A and C.567dupT mutations in the MMACHC gene. *Pediatrics & Neonatology*, **52**: 223-226.
- Mei-Ying Liu, Yan-Ling Yang and Ying-Chen Chang *et al* (2010). Mutation spectrum of MMACHC in Chinese patients with combined methylmalonic aciduria and homocystinuria. *Journal of Human Genetics*, **55**: 621-626.