

# Therapeutic effect of minimally invasive interventional treatment of brain hematoma

Lin Weiwei<sup>1</sup>, Xing Bing<sup>2</sup>, Deng Yiming<sup>3</sup>, Zhang Zhen<sup>4</sup> and Du Yifeng<sup>5\*</sup>

<sup>1</sup>Neurology Shandong Provincial Hospital affiliated to Shandong University Jinan, Shandong, People's Republic of China

<sup>2</sup>Neurosurgery Beijing Union Medical College Hospital Beijing, People's Republic of China

<sup>3</sup>Neurology Beijing Tian Tan Hospital, Capital Medical University Beijing, People's Republic of China

<sup>4</sup>Neurosurgery Shandong Provincial Hospital affiliated to Shandong University Jinan, Shandong, People's Republic of China

<sup>5</sup>Neurology Shandong Provincial Hospital affiliated to Shandong University Jinan, Shandong, People's Republic of China

**Abstract:** To investigate the therapeutic effect of minimally invasive interventional treatment of brain hematoma, 128 patients with brain hematoma were randomly divided into two groups, including observation group (64 cases) and control group (64 cases). The observation group was performed with minimally invasive interventional therapy and drug conservative therapy was used in the control group. Clinical curative effect, treatment of neural function defect score, and quality of life score were recorded. Total effective rate in observation group was significantly higher ( $p < 0.05$ ) than that in control group (90.6% vs 62.5%). And the mortality in observation group was significantly lower ( $p < 0.05$ ) than that in control group (3.1% vs 9.4%). National Institute of Health stroke scale (NIHSS) and Quality of Life (QOL) of the two groups after treatment were improved significantly ( $p < 0.05$ ) compared with those with treatment before; and the improved level of concept in observation group was significantly higher ( $p < 0.05$ ) than that of control group. Therefore, minimally invasive interventional brain hematoma surgery can effectively remove the hematoma in the brain, improve the nerve function of patients caused by trauma and improve the quality of life.

**Keywords:** Minimally invasive surgery; brain hematoma; nerve function; therapeutic effect.

## INTRODUCTION

Brain hematoma has a high morbidity and mortality rate. Drug treatment can play a certain effect in patients with small hematoma (Dey *et al*, 2015 & Zhang *et al*, 2013). Although the traditional cortical bone flap angioplasty is able to quickly remove the hematoma, but the patients with trauma large are not conducive to recovery of nerve function (Newell *et al*, 2011). Clinical prognosis would be improved effectively when removal of an intracerebral hematoma in time. Recently, imaging guided minimally invasive interventional therapy is carried out (with only the needle and without skin incision). And current developing minimally invasive interventional operation has become a main method for the treatment of brain hematoma (Wang *et al*, 2015). However, the lack of large-scale, clinical, multi-center, randomized controlled trials limited the clinical application of minimally invasive interventional operation.

In our study, we have analyzed a total of 128 patients with brain hematoma to investigate the therapeutic effect of minimally invasive interventional treatment of brain hematoma, which suggested that minimally invasive interventional brain hematoma surgery can effectively remove the hematoma in the brain, improve the nerve function of patients caused by trauma, and improve the quality of life.

## MATERIALS AND METHODS

### *Patients*

This study mainly focuses on 128 cases of patients with brain hematoma. There are 74 male cases and 52 female cases with 25-80 years old ( $55.56 \pm 3.75$ ). These patients shall be well distributed in the provinces according to the population density and only one case of each family could be involved. The study was approved by the Ethic committees of Shandong Provincial Hospital affiliated to Shandong University and written informed consent was obtained from all patients included in the study.

### *Inclusive and exclusion criteria*

All 128 patients included in the study are in line with the fourth cerebral vascular disease Academic Conference on brain hematoma diagnostic criteria, all patients were examined and confirmed by CT, excluding patients with impaired clotting mechanism affect and serious heart, liver and Renal insufficiency. The hematoma was located in brain stem in 50 cases, or basal ganglia in 66 cases (fig. 1). Then the size of the hematoma ranged 10-90mL.

### *Grouping*

128 patients with brain hematoma were randomly divided into two groups, including observation group and control group. Minimally invasive surgical treatment was applied for 64 cases with  $55.86 \pm 3.55$  years old in the observation group, during which 36 cases were male and 28 were female. The hematoma size ranged in 10-85mL ( $55.35 \pm$

\*Corresponding author: e-mail: 157351403@qq.com

4.36mL) and hematoma located in brain stem in 24 cases, or basal ganglia in 40 cases. Then 64 cases with  $56.32 \pm 3.53$  years old in control group were given conservative treatment, during which 38 cases were male and 26 were female. The size of hematoma ranged between 10-90mL ( $56.32 \pm 4.88$ mL), and hematoma located in brain stem in 26 cases, or basal ganglia in 38 cases.

### Therapeutic method

The two groups were treated with routine treatment measures, such as reducing intracranial pressure, nutritional support and maintaining water and electrolyte balance. Conservative treatment with drugs was performed in the control group, with intravenous drip of mannitol and speed urine. Then minimally invasive interventional treatment was performed in observation group. Patients with supine position or lateral position were determined according to the location of Hematoma, during which lidocaine anesthesia was applied. CT scans were applied to identify the surface and orientation of puncture, and the size of drainage. Next, certain specifications of the puncture needle (YL-1) were used to drill the skull and endocranium. Subsequently, obtuse plastic needle was applied to slowly enter the layer of hematoma and was pulled out with the application of drainage tubes. After the aspiration of liquid portion on the layer of hematoma, obtuse plastic needle was used again to enter the hematoma with the application of 0.3-6 million U urokinase for liquefaction and slow aspiration of hematoma was performed. And drainage was washed with physiological saline.

### Evaluation standard

The clinical efficacy of the two groups of patients were compared. Recovery: complete disappearance of hematoma, NIHSS score (neural function defect scale) decreased 91%-100%; Effective: hematoma >50%, NIHSS score decreased 46%-90%; invalid: hematoma not successful removal, NIHSS score reduce <45%; Deteriorate: Hematoma and NIHSS score increased.

Neurological deficit score: according to the United States National Institute of neurological function defect score (NIHSS), the lower the score, the better the recovery of neurological function (Wang *et al*, 2013). Quality of life score (QOL): out of 100 points, the higher the score, the better the quality of life.

### Residual hematoma volume measurements

The residual Hematoma Volume was determined by freehand tracing tools and/or semiautomated segmentation in the region of interest module based on the Analyze software of CT. Each section as well as each separate target area was determined by the reader, after which the Analyze software provided measurements of each region of interest including area (square millimeters) and volume (cubic millimeters).

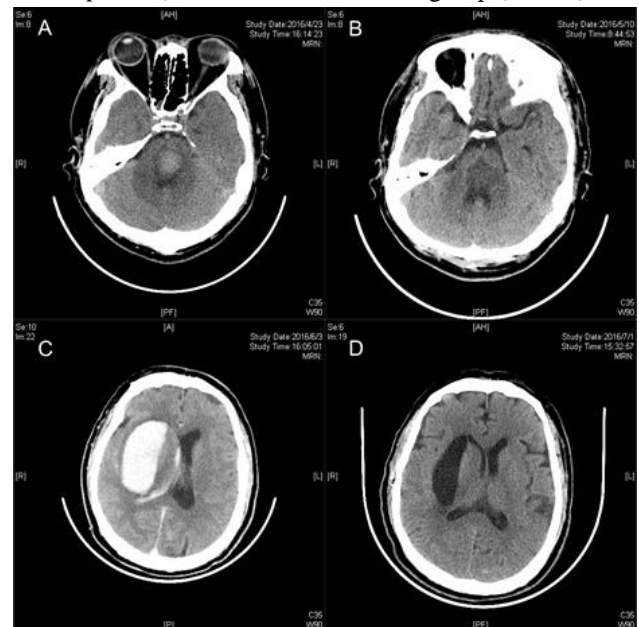
## STATISTICAL ANALYSIS

Statistical analysis with SPSS 21.0 was performed. The data should be presented by mean  $\pm$  standard deviation ( $\bar{x} \pm s$ ); comparison among groups was conducted with independent-test or non-parametric test; Enumeration data was tested by chi-square; and  $p < 0.05$  was regarded as significant.

## RESULTS

### Comparison of two groups of patients in clinical treatment effect

The total effective rate of the observation group was 90.6% and the mortality rate was 3.1%. The total effective rate of the control group was 62.5% and the mortality rate was 9.4%. The total effective rate in the observation group was significantly higher ( $p < 0.05$ ) than that in the control group, and the mortality rate was significantly lower ( $p < 0.05$ ) than that of the control group (table 2).



**Fig. 1:** Represented CT of patients with brain hematoma located in (A) brain stem, or (C) basal ganglia and the CT of patients with brain hematoma located in (B) brain stem, or (D) basal ganglia after treatment of minimally invasive intervention.

### Comparison of two groups before and after treatment in NIHSS and QOL score

After treatment, NIHSS and QOL scores in the two groups were both significantly improved ( $p < 0.05$ ) compared with those before treatment and the improved level of the observation group was significantly higher ( $p < 0.05$ ) than that of the control group (table 3).

## DISCUSSION

Cerebral hemorrhage performs high incidence, high morbidity and high mortality, which seriously affected the

**Table 1:** General comparison between two groups of patients

Groups	Age (x ± s)	Sex (n)	Hematoma location (n)	Mean Hematoma size (x ± s)
Experimental group (n=64)	55.86±3.55	Male (36) Female (28)	brain stem(24) basal ganglia (40)	55.35±4.36
Control group (n=64)	56.32±3.53	Male (38) Female (26)	brain stem (26) basal ganglia (38)	56.32±4.88
p	> 0.05	> 0.05	>0.05	>0.05
	0.17	0.14	0.14	0.13

**Table 2:** Comparison of two groups of patients in the clinical treatment effect of [n (%)]

group	Recovery [n (%)]	Effective [n (%)]	Invalid [n (%)]	Deteriorate [n (%)]	Total effective rate [n (%)]	Mortality [n (%)]
Experimental group (n=64)	24(37.5)	34 (53.12)	4 (6.25)	2 (3.12)	58 (90.6)	2 (3.1)
Control group (n=64)	10 (15.62)	30 (46.88)	14 (21.88)	10 (15.62)	40 (62.5)	6 (9.4)
t	–	–	–	–	12.973	8.748
p	–	–	–	–	<0.05	<0.05

life safety of patients. Related studies suggested that the mortality rate of brain swelling in the brain is more than 30% (Ziai *et al*, 2014 & Dey *et al*, 2014). Cerebral hemorrhage can lead to formation of hematoma and blood in solidification. Liquefaction and pyrolysis process will release a variety of thrombin active substances to the detriment of the brain tissue, but also easy to cause brain edema and brain tissue softening, pressure and necrosis (Basaldella *et al*, 2012 & Chen *et al*, 2013). Therefore, we must enhance the treatment of brain hematoma, of which the key to the treatment is seasonable cleared haematoma. Conservative treatment is mainly based on drug treatment through dehydration, nutritional support, treatment of complications and other measures. As for the formation of the hematoma or brain edema, there is no effective treatment. Surgical therapy was favorable in the brain tissues of patients caused by trauma minimum premise (Komatsu *et al*, 2010) and the traditional cortical bone flap forming operation is more complex. With the development of minimally invasive surgery, minimally invasive surgical treatment has become the main method of treatment of brain hematoma. Related research (Fiorella *et al*, 2015 & Spiotta *et al*, 2015) showed that minimally invasive interventional therapy effectively improved hematoma clearance rate in the reduction of intracranial pressure in brain tissue, relieved the toxic effects of hematoma degradation material, reduce brain edema, and promote the recovery of neural function, thereby reducing the patient morbidity and mortality, and reducing brain injury and brain disorders caused by open cranial surgery (Turner *et al*, 2015 & Mozaffarian *et al*, 2013). It was reported that minimally invasive interventional treatment in patients within 6h after the onset of treatment performed best effect on brain tissue and cerebral blood vessels and therefore benefiting the rescue and treatment time. In this study, conservative treatment and minimally invasive interventional treatment group were compared. The results showed that the total

efficiency was significantly higher in the observation group (90.6% vs 62.5%) than that in the control group, and the observation group on mortality was significantly lower ( $p<0.05$ ) than that of control group (3.1% vs 9.4%). It indicated that minimally invasive interventional therapy could effectively remove the hematoma, and reduce the patient's mortality. In addition, the results also showed that the minimally invasive interventional therapy significantly improved neural function defect score and life quality score compared with that before treatment. And improved level in minimally invasive interventional treatment group was significantly better ( $p<0.05$ ) than that in conservative treatment of patients. The results in Mendelow *et al*, 2013 are basically the same, which showed that minimally invasive interventional therapy in patients with brain hematoma could significantly improve the neurological function and improve the patient's quality of life in a large extent.

## CONCLUSION

Minimally invasive brain hematoma surgery can effectively remove the hematoma in the brain, decrease the mortality, improve the NIHSS and QOL and improved the nerve function of patients.

## REFERENCES

- Basaldella L, Marton E, Fiorindi A, Scarpa B, Badreddine H and Longatti P (2012). External ventricular drainage alone versus endoscopic surgery for severe intraventricular hemorrhage: A comparative retrospective analysis on outcome and shunt dependency. *Neurosurg. Focus*, **32**(4): E4.
- Chen CC, Liu CL, Tung YN, Lee HC, Chuang HC, Lin SZ and Cho DY (2011). Endoscopic surgery for intraventricular hemorrhage (IVH) caused by thalamic hemorrhage: Comparisons of endoscopic surgery and

- external ventricular drainage (EVD) surgery. *World Neurosurg.*, **75**(2): 264-268.
- Dey M, Stadnik A and Awad IA (2014). Spontaneous intracerebral and intraventricular hemorrhage: Advances in minimally invasive surgery and thrombolytic evacuation and lessons learned in recent trials. *Neurosurgery*, **74**: 142-150.
- Dey M, Stadnik A, Riad F, Zhang L, McBee N, Kase C, Carhuapoma JR, Ram M, Lane K, Ostapkovich N, Aldrich F, Aldrich C, Jallo J, Butcher K, Snider R, Hanley D, Ziai W and Awad IA (2015). CLEAR III Trial Investigators. Bleeding and infection with external ventricular drainage: A systematic review in comparison with adjudicated adverse events in the ongoing clot lysis evaluating accelerated resolution of intraventricular hemorrhage phase III (CLEAR-III IHV) trial. *Neurosurgery*, **76**(3): 291-300.
- Fiorella D, Gutman F, Woo H, Arthur A, Aranguren R and Davis R (2015). Minimally invasive evacuation of parenchymal and ventricular hemorrhage using the Apollo system with simultaneous neuronavigation, neuroendoscopy and active monitoring with cone beam CT. *J. Neurointerv. Surg.*, **7**(10):752-757.
- Komatsu F, Komatsu M, Wakuta N, Oshiro S, Tsugu H, Iwaasa M and Inoue T (2010). Comparison of clinical outcomes of intraventricular hematoma between neuroendoscopic removal and extra ventricular drainage. *Neurol. Med. Chir. (Tokyo)*, **50**(11): 972-976.
- Li Y, Zhang H, Wang X, She L, Yan Z, Zhang N, Du R, Yan K, Xu E and Pang L (2013). Neuroendoscopic surgery versus external ventricular drainage alone or with intraventricular fibrinolysis for intraventricular hemorrhage secondary to spontaneous supratentorial hemorrhage: a systematic review and meta-analysis. *PLoS. One.*, **8**(11): e80599.
- Mendelow AD, Gregson BA, Rowan EN, Murray GD, Gholkar A and Mitchell PM (2013). STICH II Investigators. Early surgery versus initial conservative treatment in patients with spontaneous supratentorial lobar intracerebralhaematomas (STICH II): A randomised trial. *Lancet.*, **382**(9890): 397-408.
- Morgan TC, Dawson J, Spengler D, Lees KR, Aldrich C, Mishra NK, Lane K, Quinn TJ, Diener-West M, Weir CJ, Higgins P, Rafferty M, Kinsley K, Ziai W, Awad I, Walters MR, Hanley D (2013). CLEAR and VISTA Investigators. The modified Graeb Score: An enhanced tool for intraventricular hemorrhage measurement and prediction of functional outcome. *Stroke*, **44**(3): 635-641.
- Mozaffarian D, Benjamin EJ, Go AS, Arnett DK, Blaha MJ, Cushman M, Das SR, de Ferranti S, Després JP, Fullerton HJ, Howard VJ, Huffman MD, Isasi CR, Jiménez MC, Judd SE, Kissela BM, Lichtman JH, Lisabeth LD, Liu S, Mackey RH, Magid DJ, McGuire DK, Mohler ER 3rd, Moy CS, Muntner P, Mussolino ME, Nasir K, Neumar RW, Nichol G, Palaniappan L, Pandey DK, Reeves MJ, Rodriguez CJ, Rosamond W, Sorlie PD, Stein J, Towfighi A, Turan TN, Virani SS, Woo D, Yeh RW and Turner MB (2016). American Heart Association Statistics Committee; Stroke Statistics Subcommittee. Executive summary: heart disease and stroke statistics-2013 update: A report from the American Heart Association. *Circulation*, **133**(4): 447-454.
- Naff N, Williams MA, Keyl PM, Tuhim S, Bullock MR, Mayer SA, Coplin W, Narayan R, Haines S, Cruz-Flores S, Zuccarello M, Brock D, Awad I, Ziai WC, Marmarou A, Rhoney D, McBee N, Lane K and Hanley DF Jr (2011). Low-dose recombinant tissue-type plasminogen activator enhances clot resolution in brain hemorrhage: The intraventricular hemorrhage thrombolysis trial. *Stroke*, **42**(11): 3009-3016.
- Newell DW, Shah MM, Wilcox R, Hansmann DR, Melnychuk E, Muschelli J and Hanley DF (2011). Minimally invasive evacuation of spontaneous intracerebral hemorrhage using sonothrombolysis. *J. Neurosurg.*, **115**(3): 592-601.
- Spiotta AM, Fiorella D, Vargas J, Khalessi A, Hoit D, Arthur A, Lena J, Turk AS, Chaudry MI, Gutman F, Davis R, Chesler DA and Turner RD (2015). Initial multi center technical experience with the Apollo device for minimally invasive intracerebral hematoma evacuation. *Neurosurgery*, **11**: 243-251.
- Turner RD, Vargas J, Turk AS, Chaudry MI and Spiotta AM (2015). Novel device and technique for minimally invasive intracerebral hematoma evacuation in the same setting of a ruptured intracranial aneurysm: Combined treatment in the neurointerventional angiography suite. *Neurosurgery*, **11**: 43-50.
- Wang WM, Jiang C and Bai HM (2015). New Insights in Minimally Invasive Surgery for Intracerebral Hemorrhage. *Front Neurol. Neurosci.*, **37**: 155-165.
- Ziai WC, Tuhim S, Lane K, McBee N, Lees K, Dawson J, Butcher K, Vespa P, Wright DW, Keyl PM, Mendelow AD, Kase C, Wijman C, Lapointe M, John S, Thompson R, Thompson C, Mayo S, Reilly P, Janis S, Awad I and Hanley DF (2014). CLEAR III Investigators. A multicenter, randomized, double-blinded, placebo-controlled phase III study of Clot Lysis Evaluation of Accelerated Resolution of Intraventricular Hemorrhage (CLEAR III). *Int. J. Stroke.*, **9**(4): 536-542.