

Combination of locking plate and anti-osteoporosis drug for the treatment of senior osteoporotic proximal humeral fractures

Hao Chen*, Qing Zhou and Jinlian Liu

Department of Orthopaedics, Suzhou Kowloon Hospital Affiliated to Shanghai Jiaotong University School of Medicine, Suzhou, China

Abstract: To analyze and evaluate the clinical efficacy of the combination of locking plate and anti-osteoporosis drug for the patients with senior osteoporotic proximal humerus fractures. 120 patients with senior osteoporotic proximal humerus fractures were selected as research objects. According to the differences of treatment options, they were divided into two groups, i.e., 60 patients in observation group accepting the treatment of combination of locking plate and anti-osteoporosis drug, the other 60 patients in the control group accepting simple locking plate treatment. The treatment effect and final result between the two groups were compared. The follow-up result showed that the average fracture healing time of observation group was (94.5±4.2) days, with excellent treatment rate reaching to 93.33% (56/60); the average fracture healing time of control group was (116.5±3.8) days, with excellent treatment rate of 75% (45/60). The intergroup difference was of statistical significance, wherein $p < 0.05$. The treatment efficacy of the combination of locking plate and anti-osteoporosis drug for senior osteoporotic proximal humeral fractures is faster and more precise, which is worth being applied in clinical practice.

Keywords: Locking plate, anti-osteoporosis drug, senior osteoporotic proximal humeral fractures, clinical efficacy.

INTRODUCTION

With the increase of age, the phenomenon of old people's bone calcium loss becomes more serious, which can easily occur the problems, such as the decline of bone density and quality, bone micro-structural damage and so on (fig. 1), resulting in the increase of bone fragility, so as to cause the body's bone disease (Zhao *et al.*, 2014). Most of the people who suffer from proximal humerus fractures are senior osteoporotic patients, in recent years, due to the continuous development of trend of population aging, the morbidity risk rate of this disease in clinical also shows a rising trend. Clinical studies show that the morbidity risk rate of senior osteoporotic proximal humeral fractures occupy 5-9% of the whole body's fracture (Sun *et al.*, 2012).

In addition, since the continuous weakening of each body function, the tolerance ability of old patients, who accept surgery treatment often is low, so the expected physical rehabilitation effect usually is unsatisfactory. The decline of old patients' bone strength increases the failure risk of fracture fixation surgery, or even seriously affect the normal life order of the old people, resulting in the serious decline of their life quality. After continuous development of clinical medical technology, locking plate has become a routine means to treat senior osteoporotic proximal humerus fractures and part of the clinical studies show that the effect of locking proximal humerus plate combines anti-osteoporosis treatment in senior osteoporosis patients is more precise, and compared with

the simple locking plate treatment, its effect exists obvious advantages (Cantarella *et al.*, 2015, Peng *et al.*, 2010).

In order to further improve the clinical treatment effect of osteoporotic proximal humerus fractures, for the clinical efficacy of the combination of locking plate and anti-osteoporosis drug for the treatment of senior osteoporotic proximal humeral fractures, the paper carries out a large number of samples retrospective analysis. Now the summary for the specific circumstances is made in the following parts.

MATERIALS AND METHODS

General materials

All these patients accepted medical treatment during the period from May 2013 to May 2016, and there were 120 people in total, including 81 men and 39 women; The age of patients were from 60 years old to 84 years old, and the average age was (73.5±4.2) years old; the days from fracture to accepting surgery varies from 1 day to 8 days, and the average time interval was (4.0±1.3) days; NEER (proximal humeral fractures four parts classification) classification results shown that: there were 66 patients with three-part fractures, and 54 patients with four-part fractures. According to the difference of treatment options, the patients were divided into two groups, comparing the basic materials to obtained $P > 0.05$, which shown there was no significant statistics difference (table 1).

*Corresponding author: e-mail: ch81@163.com

Inclusion and exclusion criteria

Inclusion criteria: The age of patients were over 60 years old. All the NEER classification (proximal humeral fractures four parts classification) were closed proximal humerus three-part fractures and four-part fractures; there was no surgical contraindications, have good tolerance and voluntary to accept surgery; fresh fractures; accept bone density meter dual-energy X-ray absorptiometry determination method to measure femoral neck portion (fig. 2). All patients were primary osteoporosis.

Exclusion criteria (Lee *et al.*, 2016): open proximal humerus fractures; blood vessels, nerves associated injuries; split humeral head fractures; glenohumeral joint dislocation fractures; disturbance of consciousness, cerebral infarction, cancer, serious medical illness (heart, lung, kidney failure) and so on; the patients with previous shoulder joint diseases.

Treatment methods

The patients in control group accepted the locking plate treatment simply, specific treatment methods are shown as follows:

Preparation before surgery: general improving various relevant examinations after hospitalization, asking the relevant sections for consultation, positive treatment coexisting underlying diseases. Improve and perfect the shoulder joint anteroposterior position of scapula plane, scapula lateral position (scapula Y position), axillary lateral position when patients lie supine and CT three-dimensional reconstruction to facilitate the surgical design before surgery. General prophylactic antibiotics before surgery.

Surgery method

The patients lie supine, accepting high brachial plexus analgesia or general anesthesia. Elevate shoulder and back 30 degrees, took the groove admission passage between deltoid muscle and pectoralis major muscle in front of the shoulder joint and separate layer by layer to protect the cephalic vein, exposed the fracture and humeral head. After that, explore rotator cuff injury, try not to cut the joint capsule, removed blood clot and embedded soft tissue between the fracture, clean up glenoid cavity. Regarding the long head tendon of biceps and intertubercular groove as the marks, avoid sub periosteal dissection, protect the blood supply, the anatomical relationship among big reset, small nodules and humeral head. Fixed temporarily with Kirschner wire and keep it 0.5 centimeters away from humerus large nodules. Placed proximal humerus anatomic locking compression plate with appropriate length on the outside of long head tendon of biceps. Finally fixed the humerus backbone on bone fracture plate, and pay attention that the head-shaft angle ≥ 120 degrees and the reset of medial humeral distance (fig. 3). If the metaphyseal bone mass is insufficient, filled in the bone particles. Carried out

several C-type arm X-ray machine examinations during the surgery to check the situation of fractures reset and whether the screws were cut out. For patients with combined rotator cuff injury, repaired rotator cuff and joint capsule according to the degree of injury, and then placed drainage strip and suture incision layer by layer.

After treatment

All the patients were fixed by abduction brace, as the case, pull the wick within 48 hours, in the second day after surgery, started the active motion of affected limbs' finger, elbow and wrist joints under the guidance of physician. After two weeks, started the shoulder joints passive rehabilitation activities, increased the amount of exercise and amplitude gradually, such as performed the pendulum motion and other exercises. After 4 weeks, have X-ray examinations, as the fracture healing situation, carry out climbing movement, outreach and raising activities based on the previous stage, paid attention that the range of activities was not too large. Six weeks later, in order to improve the strength of the affected limb muscles, the patients were further performed the exercises of the shoulder joints resistance and active range.

On the basis of this, in the observation group combined with the use of anti osteoporosis drugs for the patients: after hospitalization, the patients were treated with calcium + calcitriol + calcitonin. Drugs and methods: Xie Daly Calcium Carbonate Tablets (manufactures: Jilin Wantong Pharmaceutical Co. Ltd; approval number: state medical permitment number H10980201), 1-4 piles on day, taken them in each time after meals; Luo Gaiquan Calcitriol Soft Capsules (manufactures: Catalent Germany Eberbach GmbH; approval number: state medical permitment number J20150011), 1 capsules each time (0.25g), two times a day; Gu Taining Salmon Calcitonin Injection (manufacturer: Background Silver Valley Actual Pharmaceutical Co., Ltd.; approval number: state medical permitment number H20040495), adopt intramuscular or subcutaneous injection, the first week: once a day, 50 to 100 units each time; the second week: every other day, 50 to 100 units each time; the third week to the twelfth week: once a week, 50 to 100 units each time. According to the disease condition of the patients, arranged treatment time reasonably, and the minimum time is 12 months.

Clinical observation index

Compared the average fracture healing time, the treatment excellent rate of the patients in the two groups, and use NEER shoulder joints scores to evaluate the treatment effect synthetically (pain-35 points, function-30points, range of motion- 25points, anatomical position-10 points).

STATISTICAL ANALYSIS

The research on the specific effect of the combination of locking plate and anti-osteoporosis drug for the treatment of senior osteoporotic proximal humeral fractures, the

group use SPSS19.0 statistics software to analyze and process the relevant data, the count data by (n, %), which is tested by chi square, the measurement data is expressed by ($\bar{x} + s$) T, which is tested by t, only meeting $P < 0.05$, it can be considered that the difference is significant in statistics.

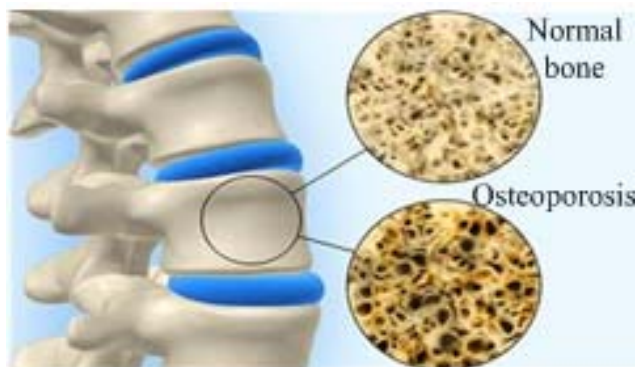


Fig. 1: The decline of bone density caused by osteoporosis.

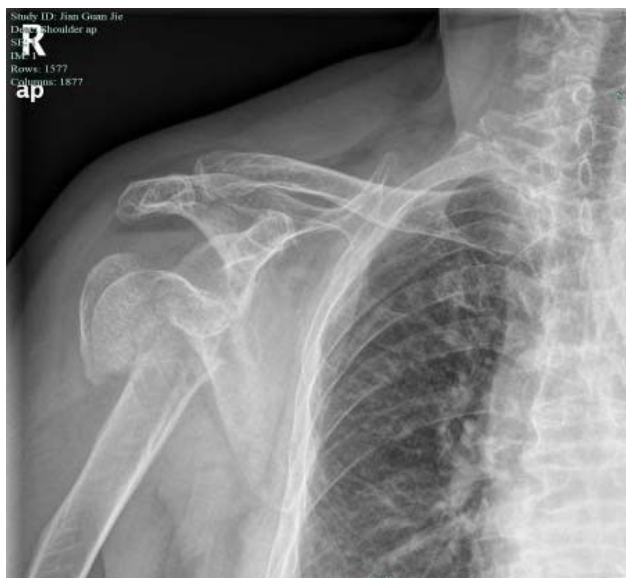

Fig. 2: Case of X-ray of senior osteoporotic proximal humeral fractures.

RESULTS

The average fracture healing time of observation group was (94.5 ± 4.2) days, while that of control group was (116.5 ± 3.8) days. The difference between the groups was statistical significance ($t=30.087$, $p=0.000 < 0.05$); the excellent treatment rate was in observation group (fig. 4) reached to 93.33% (56/60), while that of control group was 75% (45/60) The difference between the groups was statistical significance ($t=7.566$, $p=0.005 < 0.05$); the NEER (proximal humeral fractures four parts classification) average score of observation group was (94.6 ± 4.5), and the NEER average score of control group

was (81.5 ± 5.2). The intergroup difference of statistical difference was ($t=14.756$, $p=0.000 < 0.05$).

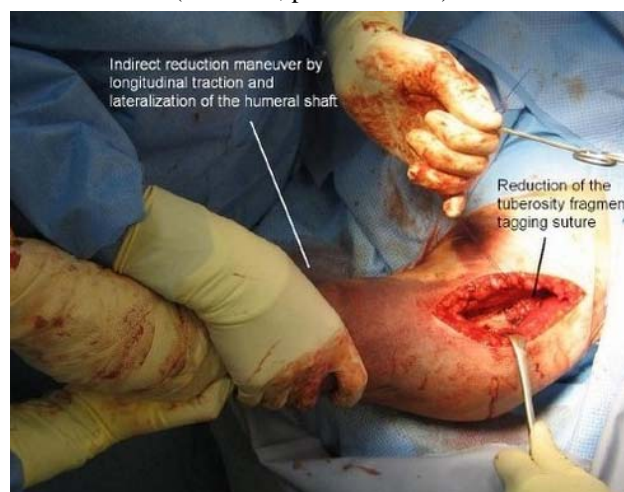


Fig. 3: Surgery of senior osteoporotic proximal humeral fractures.

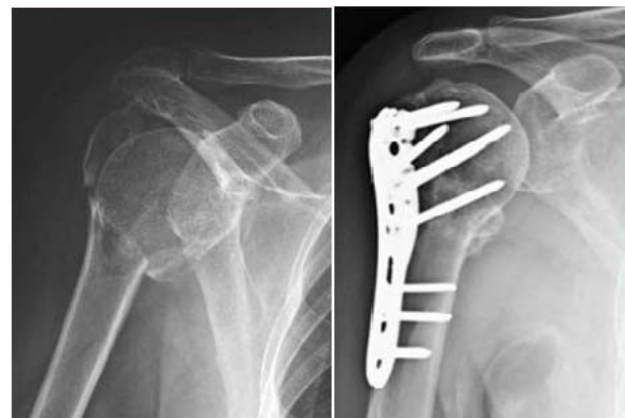

Fig. 4: One case fixed effect comparison of the patient before and after treatment (Note: fixed effect before treatment is shown on the left, fixed effect after treatment is shown on the right).

DISCUSSION

For the treatment of senior osteoporotic proximal humeral fractures, clinical result shows that locking plate has major advantages compared with traditional plate. The first advantage is higher fitness and sound stability; Secondly, the design of sutural pore increases the simplicity of operation; Moreover, the locking mode can prevent re-displacement after reduction of fracture, so as to reduce the pressure between plate and bone, and guarantee the blood supply for periosteum and fracture blocks; finally, locking humerus from different angles features excellent tensile resistance and anchor force, so that patients with severe osteoporosis or bony defects can be fixed effectively, and principle of minimal invasion can be reflected. Clinical results show that the application of locking plate can achieve good efficacy in treating patients with osteoporotic proximal humeral fractures (Al-

Table 1: Basic materials comparison between two groups of patients (n = 60)

Project	Observation group	Control group	P
Gender	43 men; 17women	38men; 22women	>0.05
Age	(72.5±2.3) years old	(71.7±3.2)years old	>0.05
Time from injury to surgery	(3.9±0.8) days	(4.1±1.1) days	>0.05
Three-part fractures	32	34	>0.05
Four-part fractures	28	26	>0.05

Hazmi, 2016). However, during treating fracture of patients with senile osteoporosis, the symptom of osteoporosis will be worsening due the lack of exercises, the fracture healing will be delayed or even failed. Therefore, it is very necessary to strengthen the treatment of senile osteoporosis. On the basis of surgery, using anti osteoporosis drugs can significantly inhibit bone absorption, thus effectively enhance the bone density and reduce new fracture, prevent re-fracture, enhance the effect of internal fixation and improve the prognosis of patients. The study points out that the effect of using combined drug is better than that of using single drug. Therefore, in the study of this group, the patients in observation group use three drugs in combination, which has a good effect. Compared the result with the control group, it is significantly better than the simple accepting surgery from the aspects of healing time and treatment effect, all the differences exist statistics differences (P<0.05).

In summary, the combination of locking plate and anti osteoporosis drugs in the treatment of senior osteoporotic proximal humeral fractures has significant effect, it is suggested to be widely used in clinical practice.

REFERENCES

- Abu-Taweel G (2016). Effects of curcumin on the social behavior, blood composition, reproductive hormones in plasma and brain acetylcholinesterase in cadmium intoxicated mice. *Saudi J. Biol. Sci.*, **23**: 219-228.
- Al-Hazmi A and Tariq Javeed M (2016). Effects of different inoculum densities of *Trichoderma harzianum* and *Trichoderma viride* against *Meloidogyne javanica* on tomato. *Saudi J. Biol. Sci.*, **23**: 288-292.
- Azra M and Ikhwanuddin M (2016). A review of maturation diets for mud crab genus *Scylla* broodstock: Present research, problems and future perspective. *Saudi J. Biol. Sci.*, **23**: 257-267.
- Cantarella G (2015). Clinical Case: Fatal Multi-organ Left Ventricular Embolism in a Patient with Beta Thalassemia Major undergoing Endovascular Treatment for Stenosis of the Sub-renal Abdominal Aorta. *Acta. Medica. Mediterranea.*, **31**: 1019-1021.
- Lee S, Hossaine M and Park S (2016). A potential anti-inflammation activity and depigmentation effect of *Lespedeza bicolor* extract and its fractions. *Saudi J. Biol. Sci.*, **23**: 9-14.
- Peng W, Wang L and Ma Y (2010). Efficacy analysis and comparison between locking compression plate and common locking plate on the treatment of senior osteoporotic proximal humeral fractures. *Chin. J. Osteoporos.*, **16**: 741-743.
- Sun G (2012). Implantation of locking humeral plate for osteoporotic fractures of the proximal humerus in the elderly: A 12 months' follow-up. *CHN Tissue Eng. Res.*, **16**: 2366-2369.
- Yang J, Yan S and Xiao S (2015). Efficacy observation of the combination of locking plate and MIPO technique for the treatment of senior osteoporotic proximal humeral fractures. *Contemp. Medi.*, **18**: 88-89.
- Zhao D, Zhao D, Ma C and Yang G (2014). Efficacy analysis of the combination of locking plate and anti-osteoporosis drug for the treatment of senior osteoporotic proximal humeral fractures. *J. Med. Postgrad.*, **6**: 619-622.
- Zhang Y (2013). Clinical analysis of locking proximal humerus plate combined with MIPO in the treatment of senile osteoporotic fractures of the proximal humerus. *Int. Med. & Health Guidance News*, **19**: 3595-3597.