

Pentoxifylline intervention and drug action in scalping forehead flap for large temporal cutaneous defects

Jing An, Xingqi Chen and Yuhang Sun*

Affiliated hospital of Hebei University of Engineering, Handan, China

Abstract: Pentoxifylline is widely used in the treatment of cerebrovascular disease, at present, there are a variety of drugs in the clinical expansion of the role of the skin flap, by improving or promoting blood circulation, to ensure the survival of the flap. We designed scalping forehead flap to reconstruct large temporal cutaneous defects. This flap is reliable and can give us excellent postoperative result. This design has several advantages and is worth to be promoted. The scalping forehead flap we designed is reliable. The posterior auricular artery and its branches provided enough blood supply to the scalp and forehead tissue of the flap. The frontal muscle also make the flap have a high survival rate. Large temporal cutaneous defects can be reconstructed by this novel scalping forehead flap we described. This technique is useful especially for patients who suffered malignant tumor and can not choose free flap.

Keywords: Pentoxifylline; scalping forehead flap; temporal defect; reconstruction.

INTRODUCTION

Pentoxifylline (PTX) is the extract from cocoa beans theobromine, then introducing ketone and is a kind of alkaloid, molecular formula $C_{13}H_{20}N_4O_3$, chemical name is two methyl xanthine, methyl xanthine derivatives, is a non selective phosphorus acid phosphatase inhibitor two (Iris *et al.*, 2009). It is widely used in the treatment of cerebrovascular disease, ischemic heart disease, diabetes, eye circulation, sexual dysfunction, sepsis and organ transplant rejection. Recently, PTX has been applied in the prevention of hepatic fibrosis, the treatment of portal hypertension and dilated cardiomyopathy (Liu *et al.*, 2017). With the development of skin repair technology, the clinical application of various flaps has been increasing, which is the best way to repair tissue defects (Vasilios *et al.*, 2007). The random flap with its simple, flexible, security has become the widely used a skin graft for repairing tissue defects, according to statistics, in the field of surgery, application of random flap to repair the skin and tissue defect flap in 79% accounted for (Patrick *et al.*, 2009). Random flap is no known vascular flap, the blood supply is completely dependent on concomitant, the flap containing only the skin and subcutaneous tissue, so skin flap is often due to a lack of nutrition and often leads to vascular flap blood supply disorder, surgical repair failure (Keigo *et al.*, 1983). According to the random flap donor skin and the skin area are different in distance divided into local flap, flap and distal flap, because most blood circulation disorders occurred in the distal flap, so this paper observe the distal after random flap transplantation to blood perfusion after pedicle (Takahashi, 2017). At present,

there are a variety of drugs in the clinical expansion of the role of the skin flap, by improving or promoting blood circulation, to ensure the survival of the flap. However, there is no relevant research on the effect of PTX on the microcirculation of skin flap.

Large temporal cutaneous defects can be reconstructed by local flaps or free flaps. Local flaps harvested from forehead or cheek are the preferred choices because they can excellently match the color and nature with nearby skin (Takahashi, 2017). Free flaps can always be used in large temporal defects which can not be reconstructed by local flaps (Fang *et al.*, 2017). But in some cases, for example elder patients with other diseases, free flaps are not the best choice. Here we introduce a new design of scalping forehead flap which had already been used in lip and nasal reconstructions to reconstruct large temporal defects (Keigo *et al.*, 1983; Vasilios *et al.*, 2007).

Plastic and reconstructive surgeons are doctors that create beauty, who must have extensive medical knowledge, rich clinical experience and solid basic surgical skills since trauma often causes damage to the normal tissue structure in patients; in ordinary times, they should learn various categories of knowledge concerned, draw on others' successful experience and take in everything, particularly strengthen their knowledge and accomplishment of human body aesthetics (Abu, 2017). Finally, emergency work is hard to do more often than not, so we should uphold the professional ethics to "heal the wounded and rescue the dying with dedication", and remain vigilant at all times "as if treading on eggs and on the brink of a deep abyss" to be careful and conscientious in work, so that our skills could achieve perfection gradually.

*Corresponding author: e-mail: 13315006126@163.com

MATERIALS AND METHODS

Patients and surgical techniques

The control group was randomly divided into control group and drug group, 18 cases in the control group and the other in the drug group (n = 27). The drug group was treated with drug intervention, the other two groups were treated with the same drugs. In 45 patients, there were 37 cases of abdominal flap, flap of the leg in 5 cases, and the flap of the arm in 3 cases. Informed consent of the patient and approved by the hospital ethics committee. Pentoxifylline and Sodium Chloride Injection production by Shijiazhuang siyao Co., specifications: 250 mL, pentoxifylline 0.1g, Sodium chloride 2.25 G. The drug groups in random flap second day after Pentoxifylline and Sodium Chloride Injection 250 mL intravenous 1 /d, 14 d after the operation until the skin flap on flap pedicle to stop treatment after first days again give Pentoxifylline and Sodium Chloride Injection 250 mL intravenously 1 /d, to the pedicle after 7d treatment is stopped. Approved by the ethics committee of the hospital, all patients signed informed consent before surgery.

There are one male and two female patients who suffered large squamous cell carcinoma in their temporal region. The mean age of them were 56.2 years old. A scalping forehead flap should be designed first. The flap is from the scalp of postauricular region and ends at the skin of the forehead with a shape of "C". The width of the flap is equal to the width of the temporal defect. Then make incisions along the border of the flap and undermine the scalping forehead flap between the layer of galea aponeurotica and periosteum. Lidocaine Hydrochloride and Epinephrine Injection can help us reduce the bleeding. The integrality of periosteum should be preserved during undermining the flap because skin graft can not survive on the surface of skull. Then we can rotate and advance the flap into the temporal defect and suture the flap with the border of the defect layer by layer. The secondary defect of the scalp and forehead can be repaired by split-thickness skin graft. The dog ear of the flap is better to be dealt with after 3-4 weeks.

As a concentration area of vital organs, the exposed facial region often gets damaged and receives emergency treatment. Any improper treatment of facial injuries will bring a heavy psychological burden to patients. Anatomically, the facial skin has strong assistance to infection due to abundant blood supply. In clinical practice, when some patients came to the Hospital to receive medical treatment, they had already undergone debridement and suturing of the wounded face in another hospital, and surgery had been performed in some of them for over 48 hours. But the apposition suturing was unsatisfactorily effective anatomically since the suture line was too thick and the edge distance was too large. For some cases with an extremely poor expected effect,

we also performed debridement and suturing in them, and achieved a good result as well as, with no infection or poor wound healing occurring in them. Aseptic operation and noninvasive technique are two fundamental principles of surgery that must be followed by all surgical specialties. As society progresses and people pursue an increasing high quality of life, the traditional emergency debridement and suturing technique is already far from being able to meet patients' needs. The principles of surgery should adapt to the progress of modern medicine, or they won't be able to guide clinical practice anymore. Plastic surgery is a branch of surgery, which is usually used to treat trauma, particularly the injury of facial superficial skin soft tissues. Plastic surgery has a unique effect on wound treatment, but we have noted that emergency work is basically in the charge of young doctors in lots of hospitals.

Method

Perfect tissue and organ functions are the basis of shape repair. For the treatment of facial traumas, we should determine first whether the functions would be affected. For the repair of ruptured muscles and nervous tissues, it should be clear whether there are fractured duct structures such as nasolacrimal duct and parotid duct, or defected bony structures such as orbitozygomatic bone and mandible or maxilla. Surgery should be performed promptly according to patients' traumatic condition as well as the existing medical equipment and technological capabilities. For the traumatic patients in whom important underlying anatomical structures are already caused by traumas, it is far from enough to repair the skin soft tissue structure alone. The principles and aim of plastic surgery should include two parts: shape repair and functional reconstruction.

Clinical report

A 57-year-old man with a large squamous cell carcinoma in his temporal region visited our hospital (fig. 1). First, an extended excision was made under general anesthesia. The ipsilateral arcus jugalis and parotid gland were excised in this step. The defect is 8cm×8cm in size, located from preauricular region to part of the eyelids in horizontal, from the hairline above the temple to the cheek of the middle face in vertical (fig. 2). Second, made a scalping forehead flap from the scalp of postauricular region to the skin of the forehead, rotated and advanced the flap into the defect, and suture the flap layer by layer. In this step, a 5mm horizontal incision should be made at appropriate position to reconstruct the outer canthus with normal length. A drainage tube was placed under the flap. Third, transplant split-thickness skin graft which was harvested from the lateral region of the thigh. Both the flap and the skin graft was survived very well (figs. 3-5). The dog-ear of the flap was excised after 4 weeks.

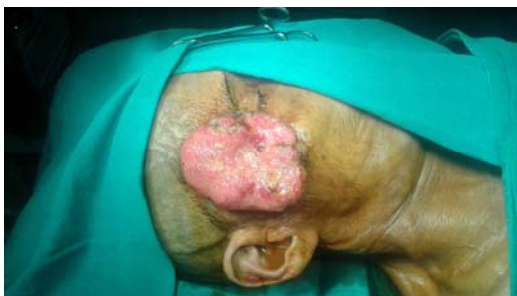

Fig. 1: Preoperative photo.

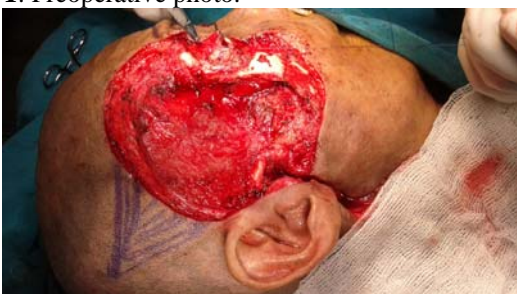

Fig. 2: The temporal defect.

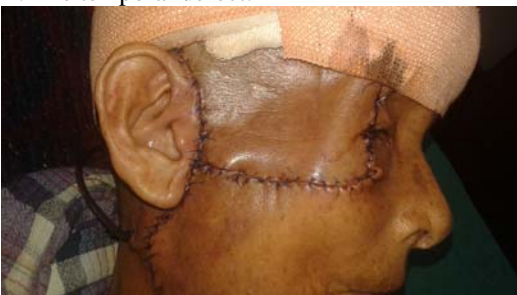

Fig. 3: 2 days after the surgery(lateral view)

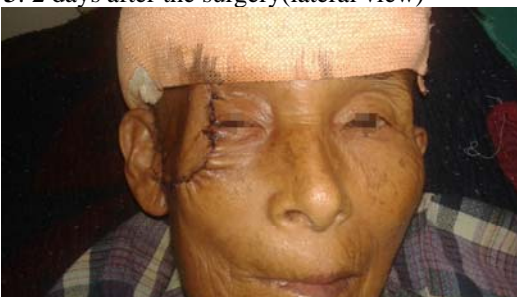

Fig. 4: 2 days after the surgery (anterior view); the length of both horizontal eye cleft is same

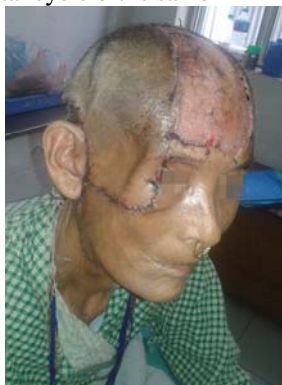

Fig. 5: 7 days after the surgery; the flap and the skin graft are survived.

RESULTS

Results according to the actual treatment analysis, 45 patients were involved in the result analysis, the general situation of the two groups of patients, see table 1. Because of the differences of the number of cases in two groups, and the number of cases involving the history of occupation without comparison, and other general information were not significant; in addition, patients in the comparison, in order to ensure the flaps survived, two groups of pedicle cut-off time is similar, the two time group had no significant difference, but the average duration of drug group is less than the control group, showed that PTX shortened the flap healing time.

Table 1: Two groups of patients with general information

Item	Control group (n=18)	Drug group (n=27)
Age	28.50±8.00	29.36±7.00
Male (%)	68	72
Female (%)	32	28
Duration	35±10	30±11
Profession(retired/worker/farmer)	2/6/6	1/13/11
Body mass index (x±s, kg/m2)	24.5±2.9	25.0±2.7
History (crush injury/electrical injury/traffic accident / severe burns)	7/2/5/0	16/3/5/1

Pedicledivision, drug group and control group PU value is more significant changes in the distal end of the flap, after 1 day began to increase, has gradually rising trend, see Figure 6, and the drug group was higher than the control group PU flap flap distal PU value after 7 days to the pedicle, drug group and control group the distal end of the flap PU value was significantly different (P, <0.05); in the pedicle, two groups of blood flow decreased, but no significant difference between the two groups (P >0.05).

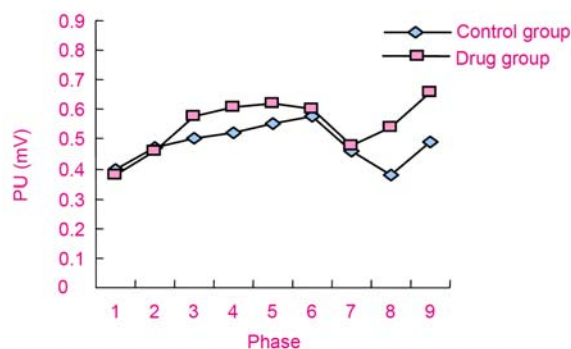


Fig.6: Distal flap PU value comparison

Two groups of pedicle PU values in each phase of

observation, pedicle, two groups of PU decreased after operation, the flap pedicle group gradually increased, PU value increased slowly and the drug control group, the pedicle PU value in 7 d after hemoperfusion into stable period, see fig. 7, two groups of PU comparison, there was no significant difference ($P > 0.05$); while in the pedicle surgery, two groups of PU decreased, the stage of drug group PU increased significantly, and the PU value of control group had significant difference ($P < 0.05$). All the two groups of random flaps survived, and all of them were repaired successfully.

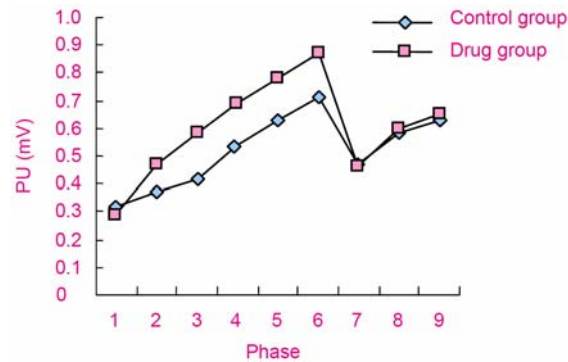


Fig. 7: flap pedicle of PU value comparison.

In all patients, the scalping forehead flaps were harvested easily and rotated to the temporal defects without any tension. All three scalping forehead flaps and the split-thickness skin graft survived very well. The forehead part of the flap is depilous and the reconstructed temples were aesthetically pleasing from the frontal and lateral view. The scalp part of the flap were located in the forehead which can be hidden by a hat. In all patients, no complications including flap necrosis, hematoma were noted. There were not distortion of the eyelids or eyebrow.

Compared with the emergency patients in other fields of surgery, the emergency patients in the field of plastic surgery usually suffer from slight traumas, mostly involving the injuries of surface skin soft tissues. Even so, due to associated injuries in them, treatment ought to be performed from an overall point of view. First, patients should be examined comprehensively and systematically, to identify whether there are life-threatening injuries in them. Never be anxious to treat some apparent body-surface injuries. Keep firmly in mind that explicit, correct diagnosis is prerequisite to proper, effective treatment.

Trauma usually leads to tissue defects, which shall not be excised rashly, while the tissues that are still viable should be retained as far as possible; in addition, Stage-II plastic surgery may inevitably be performed at times no matter how careful emergency medical workers are during emergency treatment. Therefore, the seemingly

excess tissues shouldn't be excised rashly, while the tissues that are still viable need to be sutured in situ after proper trimming, to pave way for Stage-II surgery.

For the patients with serious trauma, precise repair shall not last long. At the moment, the best way is to close the trauma promptly by a succinct, effective method. The precise plastic surgery will need to be performed half a year later. We should bring home to the patients and their family members the grounds for the above treatment approach, so as to be understood and trusted by them. If patients are badly wounded or their traumatic condition is complicated, hasty performance of surgery often "does not bring success". Moreover, if the preferred most effective repair materials are used up rashly, whereas the best surgical outcome isn't achieved, the patients will lose the opportunity to receive reconstructive surgery with the best repair materials. In a word, going too far is as bad as not going far enough, so do not do tomorrow's work today.

DISCUSSION

The effect of PTX on the random flap is mainly used the following function: the blood rheology and the vasodilation effect, can increase the amount of ATP deformation ability of cell membrane and improve the cell membrane (Liu *et al.*, 2017), prevent platelet micro vascular contractility and red blood cell aggregation, inhibition of superoxide release and platelet activating factor to stimulate, stimulate tissue plasminogen activator release, increase the plasma enzyme and antithrombin III levels, which can reduce blood viscosity, anticoagulation and fibrinolysis, vasodilator. To improve the function of tissue cells, to restore the decline of cell function, improve tissue oxygen supply, blood supply. The blood vessels and increase mechanism of microcirculation: vascular smooth muscle cAMP increased; endothelial cells release prostaglandin, reduce the secretion of tumor necrosis factor alpha; vascular smooth muscle relaxation and decreased blood viscosity, improve the arteriole, conducive to the establishment of the flap blood supply; immune inhibition, aggregation ability by reducing the adhesion of neutrophils (Patrick *et al.*, 2009). The expression of membrane C3 receptor inhibition of neutrophil, increase deformability of neutrophils and monocytes. It is because PTX has such a wide range of pharmacological effects, so it is different from the past to improve circulation, vasodilator drugs, PTX flap blood building role is not single, may be more effective than other drugs, which need further study to prove; in addition, PTX because of its extensive pharmacological effects suitable for a variety of complications, with skin flap to repair tissue defect of patients, then the less adverse reactions, the price is cheap, so PTX more than other drugs can be widely used in the field of plastic repair (Takahashi, 2017). The application of PTX in

clinical studies, flap pedicle surgery and postoperative patients, measured by regular PU, and carry on the comparison, found that the application of PTX in patients after flap operation, the distal PU value in 3 d after the operation began to rise significantly higher than the control group of patients with PU, a straight to prove that PTX pedicle, dilates blood vessels and other obvious rheological effect, so that the distal end of the flap in the postoperative period of ischemia and reperfusion period increased the flap blood perfusion, promote the establishment of the blood circulation of the distal flap.

It is a challenge for plastic surgeons to repair large temporal cutaneous defects. Skin graft transplant is an old method but can not be used when the skull was bared. Local flap which can provide similar tissue in color and nature is difficult to be used in these patients, because there is not enough hairless cutaneous reserve near the temporal region for large temporal defects. It is better to be repaired by expanded forehead flaps (Iris *et al.*, 2009; Patrick *et al.*, 2009). But large temporal defects after malignant tumor excision which do not give us time to make tissue expanded surgery. Free flaps can solve this problem. But free flaps have their own limits and maybe the surgeons in some primary hospitals can not master microsurgery techniques. In these situations, the scalping forehead flaps we designed can be a choice to reconstruct those large temporal defects.

Plastic and reconstructive surgeons are doctors that create beauty, who must have extensive medical knowledge, rich clinical experience and solid basic surgical skills since trauma often causes damage to the normal tissue structure in patients; in ordinary times, they should learn various categories of knowledge concerned, draw on others' successful experience and take in everything, particularly strengthen their knowledge and accomplishment of human body aesthetics (Vasilios *et al.*, 2007). Finally, emergency work is hard to do more often than not, so we should uphold the professional ethics to "heal the wounded and rescue the dying with dedication", and remain vigilant at all times "as if treading on eggs and on the brink of a deep abyss" to be careful and conscientious in work, so that our skills could achieve perfection gradually. The scalping forehead flap we designed is reliable. The posterior auricular artery and its branches provided enough blood supply to the scalp and forehead tissue of the flap. The frontal muscle also make the flap have a high survival rate.

CONCLUSION

The most important disadvantage of this flap is the dented deformity and hairless deformity in donor site and the hairline deformity of the temporal region. Subsequent soft tissue expanded surgery can help us solve dented and depilous deformities. Laser technique can help us remove

the hair in the reconstructed temples. It is lucky that these deformities can be hid very well by a hat. The postoperative result of the other face under the hat is perfect.

This technique also proved that using posterior auricular artery as the pedicle of ipsilateral scalp and forehead flap is reliable. The scalping forehead flap are always been designed taking supratrochlear artery as the pedicle to reconstruct the nose. Large temporal cutaneous defects can be reconstructed by this novel scalping forehead flap we described. This technique is useful especially for patients who suffered malignant tumor and can not choose free flap.

REFERENCES

- Abu A (2017). Video-assisted thoracoscopic surgery for non-small cell lung cancer. *Minim Inva. Surg. Oncol.*, **1**(1): 1-11.
- Fang W and Ruan W (2017). Advances in uniportal video-assisted thoracoscopic surgery for non-small cell lung cancer. *Minim Inva. Surg. Oncol.*, **1**(1): 20-30.
- Iris A and Lawrence J (2009). Reconstruction of scalp and forehead defects. *Clini. Pla. Surg.*, **36**(3):355-377.
- Keigo K, Mitsumasa Y and Yukio F (1983). Immediate reconstruction using a scalp-forehead flap for the entire upper lip defect with the application of lyophilized porcine skin to surgical wounds: A case report of a malignant melanoma in the upper lip and oral mucosa. *J. Maxil.Surg.*, **5**(11):275-278
- Liu Z, Yang R and Shao F (2017). Anastomosis using complete continuous suture in uniportal video-assisted thoracoscopic bronchial sleeve lobectomy. *Minim Inva. Surg. Oncol.*, **1**(1): 31-42.
- Patrick C and Angelos W (2009). Options for the management of forehead and scalp defects. *Facial Plas. Surg. Clin. North America.* **17**(3): 379-393.
- Takahashi Y (2017). Real-time intraoperative diagnosis of lung adenocarcinoma high risk histological features: a necessity for minimally invasive sublobar resection. *Minim Inva. Surg. Oncol.*, **1**(1):12-19.
- Vasilios T, Konstantinos S, Alik F, Dimitrios T, Antonios K and Ioannis T (2007). The Scalping Forehead Flap in Nasal Reconstruction: Report of 2 Cases. *J. Oral and Maxil. Surg.*, **65**(3):532-540.