

Analysis of the effect of paclitaxel-eluting stents and paclitaxel-eluting balloon in the treatment of in-stent restenosis

Jiangtao Cheng, Chuanyu Gao*, Yuhao Liu, Zhongmin Wang, Xiaohui Zheng and Datun Qi

Department of Cardiology, Zhengzhou University People's Hospital, Zhengzhou, Henan, PR China

Abstract: To compare and analyze the effect and the safety of the paclitaxel-eluting stents and paclitaxel-eluting balloon in the treatment for in-stent restenosis. 120 cases, who had been undergone percutaneous coronary intervention (PCI) in the Department of Cardiology of Henan Provincial People's Hospital from January 2012 to January 2014 were selected. All the patients were randomly treated with paclitaxel-eluting balloon or paclitaxel-eluting stents. The former were divided into different groups that named group A and the later group B. All the selected patients signed the informed consent on interventional therapy and be given anti-platelet drugs before operating. At the same time, they had routine examination, like chest X-ray, ultrasound, biochemical detection, Myocardial injury markers. (1) The two groups had no significant difference in the general information ($P>0.05$); (2) The success rate in the two groups reached 100% and (3) All the patients were visited in the 9th, 12th and 24th month to see if any of them was dead. The reexamination results in the 9th month showed that both drug-eluting balloon and drug-eluting stents were safe and effective in treating coronary artery in-stent restenosis. In addition, drug-eluting balloon was more effective than drug-eluting stents to prevent from the in-stent restenosis.

Keywords: Paclitaxel-eluting balloon, paclitaxel-eluting stents, in-stent restenosis.

INTRODUCTION

Percutaneous Coronary Intervention (PCI) has become more and more important to treat unstable coronary artery disease (CHD), since there are more than 20,000,000 patients with CHD need this treatment now. However, the occurrence rate of In Stent Restenosis (ISR) reached to 10%-15% during the process of PCI (Colombo *et al*, 2008), which greatly limited its therapeutic effect, especially in the patients combined with diabetes or CHD with multi-vessel lesions and how to cure ISR has become a focus in the current CHD field (Sui *et al*, 2012). Nowadays, the mainly clinical methods to treat ISR include general balloon angioplasty, intracavitary radiotherapy, cutting balloon, drug-eluting balloon (DEB), drug-eluting stent (DES), etc. each with different therapeutic effects and complications (Liu *et al*, 2015).

DEB can transport drug to the diseased region to inhibit neointimal hyperplasia, making the drug adhere to the vessel wall evenly, which can prevent from restenosis, and it will not stay in the vessel permanently. Therefore it has gradually become a focus in the PCI field. However, there still be some problems. For example, it can only be used once, which requires several DEBs in the long lesion (Thomas *et al*, 1998); the drug wastes a lot in the insufficient predilation disease (Cui *et al*, 2016); it cannot overcome the elastic retraction of the vessel wall and vascular dissection and acute thrombosis caused by these problems (Heldman *et al*, 2001); and what's more, it is very expensive in the first revascularization. Meanwhile, DES can also significantly reduce the incidence rate of

restenosis and target lesion-induced revascularization. In the treatment of the simple lesions, the incidence rate of restenosis remains is less than 10% (Oberhoff *et al*, 2001; Hong *et al*, 2001). DES can effectively inhibit intimal hyperplasia after implanting stent, keeping from the occurrence of ISR. However, it also affects the process of reendothelialization of the injured vessels, leading to the occurrence of delayed thrombosis and adverse vascular diseases (Brieger *et al*, 1997; Wang *et al*, 2004). In addition, the embedding 2-layer metal will delay the dual anti-platelet time, resulting in the high incident rate of bleeding.

Optical Coherence Tomography (OCT) was used in this study to evaluate the effect of paclitaxel-eluting stents and paclitaxel-eluting balloon in the treatment of coronary in-stent restenosis. This trail was aimed to provide a more comprehensive and precise evaluation to different ISR treatments, contributing to choosing a proper therapeutic schedule to ISR.

MATERIALS AND METHODS

Material

This research was reviewed and rectified by the Medical Ethics Committee of Henan Provincial People's Hospital, conforming to the principle of voluntary participation. 120 cases who had been undergone PCI in the Department of Cardiology of our hospital from January 2012 to January 2014 were selected.

Inclusion criteria

120 cases were with more than 50% luminal loss in the stent implanting segment or within 5mm of the stent edge

*Corresponding author: e-mail: hlheditor@163.com

detected by coronary angiography, combined with one of the following condition: (1) recurrence of stenocardia, which was supposed to be related to the target vessel; (2) myocardial ischemia in the quiescent state or motion state shown in the electrocardiogram, which was also supposed to be related to the target vessel and (3) the Fractional Flow Reserve (FFR) of the target vessel was less than 0.80 detected by the pressure wire or the minimum lumen area of target vessel segment was less than 4mm^2 examined by Intravascular Ultrasound (IVUS).

Clinical data

This study adopted the foresight and parallel control test. 120 cases undergone PCI during January 2012 to January 2014 were divided according to their surgery methods into the two groups. And there were 60 cases with ISR who had been undergone DEB, aging from 50 years to 85 years. There were 60 cases with ISR who had been undergone DES, aging from 51 years to 84 years. There was no statistical significance in the general information like gender, age, illness condition ($P>0.05$). Therefore, the two groups were comparable.

Operation methods

The included patients had been undergone a series of preoperative clinical examinations and preparations. The operation was strictly conformed to the standards in the *Guideline of percutaneous coronary intervention*. The balloon used in this study was made up with COMAX, with the cover painted with $3\mu\text{g}/\text{mm}^2$ paclitaxel, which had been approved clinically. The paclitaxel-eluting stents referred to the paclitaxel was painted onto the stent, using the general balloon to transport the drug into the diseased region. Before surgery, each patient had to take aspirin 300mg/d (not late for preoperative 24h), 300mg clopidogrel (not late for preoperative 6 h). After surgery, each patient was required to take aspirin 100-300mg/d, and clopidogrel at least 75mg/d and was injected with 100u/kg low-molecular-weight heparins according to their clinical features. The hospitalized patients were observed to see the condition of acute myocardial infarction, cerebrovascular events or death. The two groups were observed by the coronary angiogram or clinical follow-up in the 9th month, 12th month and 24th month. The late lumen loss, stent intimal coverage, in-stent newborn plaque, late stent malapposition, late thrombosis, and using OCT to detect the rate of in-stent restenosis of the two groups. The major adverse cardiac events (MACE) of the patients were observed by clinical follow-up in the 12th and 24th month including recurrence of angina, non-fatal myocardial infarction, malignant arrhythmia, congestive heart-failure, cardiac death and revascularization.

STATISTICAL ANALYSIS

SPSS 19.0 software was used for statistical processing. The comparison among groups adopted T test and intra-

group comparison used ANOVA. And the data was expressed in percentage which was checked and revised by χ^2 . And $P<0.05$ was determined as statistically significant.

RESULTS

ALL the patients were visited in the 9th, 12th and 24th month during the whole experiment without one losing follow-up. As shown in fig. 1.

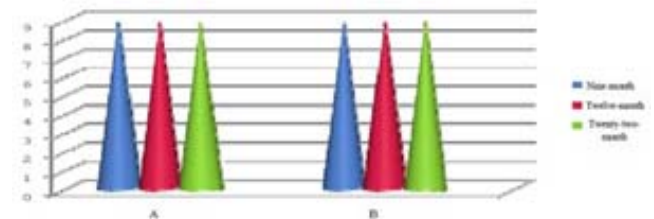


Fig. 1: the condition of the general follow-up

Evaluation of therapeutic effect

If there was one lesion in the patients selected in this experimental, their data was analyzed by patient number; if there were many lesions in one patient, selecting a proper lesion in the patient.

The statistics of the disease in the postoperative 9th month

There were total 120 cases detected by radiography in the postoperative 9th month in the two groups, and the data was shown in table 1.

The late lumen loss refers to the difference value between the immediately Minimal Lumen Diameter (MLD) after the implantation of balloon or stent and the MLD detected by coronary radiography in the 9th month follow-up, which is the index of absolute degree through radiography of rest enosis. The delayed healing and insufficient function caused by the drugs after balloon or stent implantation might induce the activation of cell activity and adhesion of mononuclear cells which could cause atherosclerosis. In addition, the late stent malapposition means there is at least one obvious detachment of stent from the vessel wall detected by the OCT through vessel, and there is sparkling bloodstream at the rear of the stent, and there are no branches in the occurrence site. These factors would cause the formation of late thrombosis as well as the in-stent restenosis. The findings showed that the condition of in-stent intimal coverage, in-stent new patches, late stent malapposition and occurrence of late thrombus and in-stent restenosis in group A was better than group B, while on the terms of the late lumen loss, the latter group was better than the former.

Success rate of operative treatment

Table 2 shows the success rate of drug-balloon and drug-stent in two groups. Then, the rate of operation success

Table 1: Condition of the lesion region in the postoperative 9th month

	Late lumen loss (mm)	Stent intimal coverage	In-stent newborn patches (%)	Late stent malapposition (%)	Late thrombosis	Incidence rate of in-stent restenosis
Group A	0.56±0.06	Good	3.1	6.8	0	7.8
Group B	0.42±0.07	Good	3.5	7.5	0	8.5

Table 2: Success rate of operation

	Group A	Group B
Success rate	100% (60/60)	100% (60/60)
P	P=1	

Table 3: Success rate of operation

	Group A	Group B	P
The 9 th month	0	0	P>0.05
The 12 th month	0	0	P>0.05
The 24 th month	1/60	2/60*	P>0.05

Note: *The operation failed if there occurred adverse cardiac events.

and the major adverse cardiac events (MACE) were observed in the two groups in the operative 9th month, 12th month and 24th month. The MACE included the recurrence of angina, non-fatal myocardial infarction, malignant arrhythmia, congestive heart-failure, cardiac death, revascularization (table 3).

DISCUSSION

Paclitaxel belongs to a kind of specific drug in the cell cycle, which can inhibit cell replication by affecting cell microtubule function (Wang, 2012). Paclitaxel can also inhibit neointima hyperplasia by inhibiting the proliferation of vascular smooth muscle cells and growth factor to activate the migration (Yang *et al*, 2015). Some related experiments showed that paclitaxel had a significant effect on reducing neointimal hyperplasia (Cortese *et al*, 2010). However, it had a huge side effect when given to the whole body that it might induce myelosuppression in the patients with poor liver and kidney function, so it was usually given to the local part to reduce the side effects largely (Wöhrle *et al*, 2011).

The findings in Scheller *et al*. study showed that the paclitaxel-coated balloon implanted into the coronary artery in pig could reduce 63% ISR, without the occurrence of acute thrombosis, sub-acute stent thrombosis or adverse cardiovascular events after postoperative 5 weeks (Scheller *et al*, 2004). Therefore, using balloon as the drug carrier can release the drug in a short time as well as effectively and securely inhibit the occurrence of ISR. Wen Zhang and Xin Shu had compared and analyzed the short-term and long-term effect of the interventional therapy of DES on the Left Main Disease in the patents with CHD and the results showed that DES had brought satisfactory short-term and long-term effect (Zhang *et al*, 2016).

The pathomechanism of in-stent restenosis are mainly the formation of thrombosis and inflammation response. The mechanism of DEB and DES are both transporting the anti-proliferation drugs to the local lesion by balloon or stent. At present, DES is a more mature treatment in the clinical treatment for in-stent restenosis but without an ideal effect. However, there is no need to implant a stent in the treatment of DEB to prevent from re-implanting-stent-induced luminal stenosis and extraneous stimulus. Many research centers in the world had conducted a number of related researches and concluded that the effect of drug-balloons and drug-eluting in the treatment of ISR were equally safe and effective, both with a low occurrence of restenosis.

Based on the above ideas, this experiment studied the effect and safety of drug balloon and drug-eluting stents in the treatment of in-stent restenosis lesions. The patients in this test were rechecked in the postoperative 9th month by coronary angiography to see the specific condition of the diseased vessels and the occurrence of restenosis, with the data collected and analyzed statistically.

This experiment adopted paclitaxel-eluting balloon and paclitaxel-eluting stents. From the results we could see that paclitaxel-eluting balloon is effective in the treatment of rest enosis. During the 2-year observation the occurrence of the major adverse cardiac events between the two groups were similar. Therefore, paclitaxel-eluting balloon and paclitaxel-eluting stents are both effective and safe.

CONCLUSION

This study analyzed the difference of the effect and safety of paclitaxel-eluting balloon and paclitaxel-eluting stent in the treatment of coronary restenosis. The evaluation criteria were mainly depended on the coronary

angiography in the postoperative 9th month. And the results showed that both the paclitaxel-eluting balloon and paclitaxel-eluting stent were effective and safe in the treatment of in-stent restenosis lesions. And the clinical follow-up results in different time nodes between the two groups had verified the effectiveness and safety of paclitaxel-eluting balloon. Therefore, paclitaxel-eluting balloons are safe and effective in the treatment of in-stent restenosis lesions and can be used as the intervention therapy in the clinical treatment of in-stent restenosis.

ACKNOWLEDGMENT

This paper is supported by 2016 Henan Province Science and Technology Key Project, with the title of Strategic research on intervention treatment of in-stent restenosis evaluated by OCT. No.162102310034

REFERENCES

- Brieger D and Topol E (1997). Local drug delivery systems and prevention of restenosis. *Cardiol. Res.*, **35**(3): 405.
- Colombo A and Latib A (2008). Treatment of drug-eluting stent restenosis with another drug-eluting stent: Do not fail the second time. *Rev. Esp. Cardiol.*, **61**: 1120-1122.
- Cortese B, Micheli A and Picchi A *et al* (2010). Paclitaxel-coated balloon versus drug-eluting stent during PCI of small coronary vessels, a prospective randomised clinical trial. The PICCOLETO study. *Heart*, **96**: 1291-1296.
- Cui KY, Lv SZ, Liu H and Song XT (2016). Advances in Current Research on in-stent restenosis with drug-eluting balloon. *J. Cardio. Pulm. Dis.*, **35**(3): 246-250.
- Heldman AW, Cheng L, Jenkins GM, Heller PF, Kim DW and Ware M Jr *et al* (2001). Paclitaxel stent coating inhibits neointimal hyperplasia at 4 weeks in a porcine model of coronary restenosis. *Circulation*, **103**: 2289.
- Hong MK, Kornowski R, Bramwell O, Ragheb AO and Leon MB (2001). Paclitaxel-coated Gianturco-Roubin II(GRII) stents reduce neointimal hyperplasia in a porcine coronary in-stent restenosis model. *Coron. Artery Dis.*, **12**: 513.
- Liu GZ, Xu LX and Shi XM *et al* (2015). Preparation of drug-eluting balloon technology to explore. *Applied Chemical Industry*, **44**: 502-505.
- Oberhoff M, Kunert W, Herdeg C, Kuttner A, Kranzhofer A and Horch B *et al* (2001). Inhibition of smooth muscle cell proliferation after local drug delivery of the antimitotic drug paclitaxel using a porous balloon catheter. *Basic Res. Cardiol.*, **96**: 275.
- Scheller B, Speck U and Abramjuk C *et al* (2004). Paclitaxel balloon coating, a novel method for prevention and therapy of restenosis. *Circulation*, **110**: 810-814.
- Sui YG and Wu YJ (2012). Current Research in Restenosis of Drug-Eluting Stent. *Advances in Cardiovascular Diseases*, **33**(4): 474-477.
- Thomas JW, Kuo MD and Chawla M *et al* (1998). Vascular gene therapy. *Radiographics*, **18**(6): 1373.
- Wang TW, Yang HS, Chen Y and Zhao YS (2004). Immunohistochemical analysis on restenosis prevention of canine with paclitaxel-eluting BIS. *Chin. J. Lab. Diagn.*, **8**: 346-350.
- Wang H (2012). The use of paclitaxel-coated balloon in the treatment of coronary in-stent restenosis: Its current situation. *J. Interv. Radiol.*, **21**(7): 614-616.
- Wöhrle J, Birkemeyer R and Markovic S *et al* (2011). Prospective randomised trial evaluating a paclitaxel-coated balloon in patients treated with endothelial progenitor cell capturing a tents for denovo coronary artery disease. *Heart*, **97**: 1338-1342.
- Yang X, Lei H and Huang W (2015). A Meta-analysis of effect of paclitaxel-eluting balloon in the treatment of stent restenosis. *J. Mod. Med. Health*, **31**(9): 1300-1304.
- Zhang W and Shu X (2016). Study of clinical therapies on left main coronary artery stenosis with drug eluting stent and coronary bypass surgery. *Chin J. Clin. Res.*, **29**(1): 68-71.