

Drug effect of atorvastatin on middle cerebral atherosclerotic stenosis and high resolution NMR diagnosis

Xingchi Chen**, Sainan Wang**, Lulu Lin, Yu Li and Hui Zhang*

Department of Neurology, The Second Hospital of Dalian Medical University, Dalian, Liaoning, China

Abstract: Atherosclerosis (AS) is a chronic inflammatory reaction with the pathological changes in the lipid deposition of arterial intima. The disorder of blood lipid metabolism is the main factor of the occurrence and development of AS, and the inflammatory reaction and autoimmune reaction also run through the development of AS. In this study, we compared the efficacy and safety of atorvastatin, simvastatin, pravastatin and rosuvastatin in the treatment of AS. At the same time, we used high resolution magnetic resonance imaging (MRI) to assess the changes in plaque area in the middle cerebral artery and the patch area before and after drug treatment. After 6 months of treatment, the number of intima-media thickness (IMT), plaque and plaque in each group were significantly lower than that before the same group. The results showed that statin treatment of AS could significantly reduce the level of blood lipids, but rosuvastatin and atorvastatin had better effects on anti inflammation and maintaining plaque stability and the drug safety was good.

Keywords: Atorvastatin, statins drugs, anti-inflammatory mechanisms, atherosclerosis, high resolution NMR.

INTRODUCTION

Atherosclerosis (AS) is a chronic inflammatory reaction with the pathological changes in the lipid deposition of arterial intima (Abu, 2017). The disorder of blood lipid metabolism is the main factor of the occurrence and development of AS, and the inflammatory reaction and autoimmune reaction also run through the development of AS (Chen, 2012; Antonova *et al.*, 2015). For example, Toll like receptors (TLRs), especially TLR4, can activate intracellular signal transduction pathways, induce immune activation and release inflammatory factors, and play an important role in the occurrence and development of AS (Damyanov *et al.*, 2015). A large number of studies have shown that statins have a significant effect on the prevention and treatment of adverse cardiovascular events (Fang *et al.*, 2017). In recent years, it has been found that statins can not only reduce the level of blood lipid, but also inhibit smooth muscle proliferation and inflammatory reaction and stabilize the plaque in AS (Ghoneum *et al.*, 2015). But the effect of different kinds of statins on the treatment of AS and the intervention effect on the inflammatory reaction are rarely reported (Fang *et al.*, 2016). Therefore, in this study, we compared the efficacy and safety of atorvastatin, simvastatin, pravastatin and rosuvastatin in the treatment of AS, so as to provide references for clinical practice.

The recurrent episodes of cerebral ischemia caused by intracranial atherosclerosis are very high, and the risk of stroke in patients with symptomatic MCA (middle cerebral artery) stenosis is about 10% per year (Guo *et al.*, 2015). Most of the stroke caused by MCA occlusion is caused by rupture, abscission and embolism of carotid

artery, or due to arrhythmia and cardiac embolism (Hisato *et al.*, 2014; Chen *et al.*, 2015). Therefore, the experimental model of MCA occlusive stroke, the explanation of pathophysiology and the treatment plan are based on the above two reasons (Hou *et al.*, 2015). The primary cause of endogenous MCA atherosclerotic stroke mechanisms are poorly understood, but also the lack of clinical assessment of ICAD (Intracranial atherosclerotic disease) severity of the disease prevention and control standards, even though there have been many attempts, but the overall drug therapy and interventional effect is not very satisfactory (Chen *et al.*, 2012; Zhigang *et al.*, 2017). In terms of morphology, atherosclerotic damage is manifested by eccentricity caused by thickening of the arterial wall and decreasing the area of the lumen. High resolution MRI has been successful in the clinical application of blood vessels

Intracranial atherosclerosis often occurs in the basilar artery and the middle cerebral artery, and the middle cerebral artery is the most concerned (Cheol *et al.*, 2012; Lin *et al.*, 2014). In Asia, intracranial atherosclerosis is more common than that of the extracranial arteries, and the form and mechanism of cerebral infarction caused by atherosclerosis are not yet clear (Meryem *et al.*, 2015). Some studies have been considered to be related to the hemodynamics of small intracranial vessels, especially severe vascular stenosis (Liu *et al.*, 2017). The bottleneck of these studies is that the current technology does not have enough resolution for the narrow cavity. The current inspection methods have certain limitations on the diagnosis of middle cerebral artery plaques. For example, DSA (digital subtraction angiography), MRA (magnetic resonance angiography) and CTA (CT angiography) can

*Corresponding author: e-mail: nmyl2001@163.com

**Xingchi Chen and Sainan Wang contributed equally to this work.

only display lumen stenosis, and can not display information of tube wall, such as plaques. Ultrasound can measure blood flow to evaluate vascular stenosis. HR-MRI can not only observe lumen structure, but also observe tube wall structure. In this study, 3.0T high resolution MRI was used to evaluate plaque changes in middle cerebral artery and plaque area before and after drug treatment.

MATERIALS AND METHODS

Research object

During January 2016 to February 2017, 180 AS patients in our hospital were selected and divided into A group (45 cases), B group (45 cases), C group (45 cases) and D group (45 cases) according to the random number table method. The patients in group A use atorvastatin, group B patients use simvastatin, group C patients use pravastatin, and group D patients use rosuvastatin. The difference of sex, age and course of disease of each group was not statistically significant ($P>0.05$), which was comparable in comparison with table 1. This study was approved by the medical ethics committee of the hospital, ethical committee number as 15SHDMU-11 and all patients signed the informed consent.

Inclusion and exclusion criteria

Inclusion criteria: (1) The relevant diagnostic criteria in the guidelines for the primary prevention of cerebrovascular disease in China were confirmed and confirmed by imaging examination. (2) Total cholesterol (TC) ≥ 5.70 mmol/L, three glycerol (TG) ≥ 2.25 mmol/L, low density lipoprotein cholesterol (LDL-C) ≥ 3.10 mmol/L, high density lipoprotein cholesterol (HDL-C) ≤ 1.96 mmol/L; (3) After lipid-lowering drug washout period of 1 month.

Therapeutic method

All the patients were given low-fat diet, and metoprolol tartrate tablets 50 mg at the same time. They were given oral nifedipine tablets + 5mg before going to bed at night, and they were taken orally before bedtime and nifedipine tablets 100mg. On this basis, the A group was treated with atorvastatin calcium tablets, 20 mg; group B was treated with Simvastatin tablets, 40 mg; group C was treated with pravastatin sodium tablets, 20 mg; group D was treated with rosuvastatin calcium tablets, 10 mg. The course of treatment in each group was 6 months.

Statistical analysis

The SPSS 17 statistical software was used to analyze the data. The measurement data is expressed as $\bar{x} \pm s$, and Shapiro-Wilk test is used to detect data normality. Levene test or F test is used. Counting data is expressed by chi square. The difference of $P<0.05$ was statistically significant.

RESULTS

Before treatment, there was no significant difference in TC, TG, LDL-C and HDL-C levels in each group ($P > 0.05$). After treatment, the levels of TC, TG and LDL-C in each group were significantly lower than that before the same group, and the level of HDL-C was significantly higher than that before the same group. The level of TC, TG and LDL-C after 3 months of treatment, group B $<$ A $<$ C and D group, HDL-C level B group $>$ A group $>$ C and D group; After 6 months of treatment, TC, TG, LDL-C level B, C group $<$ A and D group, the difference was statistically significant ($P<0.05$), as shown in table 2. After 6 months of treatment, the number of IMT, plaque and plaque in each group were significantly lower than that before the same group and in group A and D in group IMT, group B and C group. The number of plaques in group A $<$ D group $<$ group B and group C, the difference was statistically significant ($P<0.05$) and in table 3.

The study shows that 3.0T magnetic resonance scanner is necessary for MCA tube wall imaging examination. When scanning and locating the MCA wall, we should follow the vertical sagittal plane along the vertical direction. These sequences can be used to image the stenosis section on the basis of MCA images, evaluate the degree of stenosis and explore the nature of plaques. The high-resolution NMR diagnostic example is shown in fig. 1. is a DSA(digital subtract angiography) and CTP(CT perfusion scan) image of right middle cerebral artery stenosis in a 69 year old male patient. fig. A is DSA image, and B is CT plain scan image. C-G is CBF (cerebral blood flow), CBV (cerebral blood volume), TTP (time to peak), and MTT (mean transi-time) image respectively.

Before treatment, there was no significant difference in the levels of MCP-1, TGF- and MMP-9 in each group ($P > 0.05$). After treatment, the average MCP-1, TGF- and MMP-9 water in each group were significantly lower than that before the same group and the details were shown in table 4. There was no significant difference in the incidence of ADR in each group ($P>0.05$) and in table 5.

DISCUSSION

In the course of the occurrence and development of AS, blood lipid has a decisive role, and LDL-C(Low density lipoprotein cholesterol) is the key. Statins are 3- hydroxyl -3- methyl glutaryl two acyl coenzyme A (HMG-COA) reductase inhibitors, which can inhibit the HMG-COA reductase, reduce cholesterol synthesis, promote LDL-C catabolism, thereby reducing blood lipids (Kitano *et al.*, 1994; Niu *et al.*, 2007). Statins, including atorvastatin, simvastatin, pravastatin and rosuvastatin, are commonly used in clinic. However, the lipid-lowering effects of these statins are rarely reported, or are limited to 2 or 3 drugs (Zheng *et al.*, 2015).

Table 1: Basic data of each group

Group	Male / female	Age	Course of disease	Smoking
A group	25/20	59.2±7.4	11.5±2.8	12
B group	27/18	61.3±8.2	10.6±3.7	17
C group	24/21	62.8±7.9	10.4±2.9	20
D group	23/22	60.2±5.7	12.3±3.4	19

Table 2: Comparison of TC, TG, LDL-C and HDL-C

Group	Time interval	TC	TG	LDL-C	HDL-C
A group	Before treatment	6.12±0.75	2.45±0.42	3.94±0.75	1.22±0.30
	After 3 months of treatment	5.78±0.61	1.98±0.35	3.77±0.64	1.35±0.29
	After 6 months of treatment	5.41±0.51	1.64±0.28	3.40±0.35	1.67±0.18
B group	Before treatment	6.25±0.68	2.34±0.37	4.52±0.71	1.25±0.33
	After 3 months of treatment	5.41±0.61	2.05±0.27	3.74±0.97	2.54±0.45
	After 6 months of treatment	5.12±0.35	1.24±0.19	2.83±0.45	1.51±0.38
C group	Before treatment	6.70±0.64	2.54±0.17	3.81±0.96	1.30±0.33
	After 3 months of treatment	5.76±0.71	2.19±0.23	3.90±0.67	1.27±0.40
	After 6 months of treatment	4.89±0.62	1.85±0.21	3.01±0.42	1.33±0.19
D group	Before treatment	6.42±0.83	2.54±0.25	4.13±0.67	1.35±0.28
	After 3 months of treatment	5.96±0.74	2.34±0.42	3.85±0.58	1.39±0.24
	After 6 months of treatment	5.38±0.51	1.79±0.18	3.49±0.38	1.65±0.32

Table 3: Comparison of IMT, plaque number and patch area

Group	Time interval	IMT, mm	Plaques	Patch area, mm ²
A group	Before treatment	1.42±0.47	2.05±0.42	26.94±5.72
	After 6 months of treatment	1.05±0.42	1.74±0.36	23.12±4.36
B group	Before treatment	1.65±0.62	1.54±0.35	24.51±6.71
	After 6 months of treatment	1.18±0.37	1.13±0.17	22.64±5.45
C group	Before treatment	1.68±0.54	2.14±0.37	26.81±6.91
	After 6 months of treatment	1.29±0.32	1.65±0.26	22.15±5.32
D group	Before treatment	1.72±0.53	2.14±0.36	27.63±6.43
	After 6 months of treatment	1.06±0.31	1.56±0.28	20.34±3.38

Table 4: Comparison of MCP-1, TGF-β and MMP-9 levels

Group	Time interval	MCP-1	TGF-β	MMP-9
A group	Before treatment	552.6±35.7	192.3±15.6	230.1±25.6
	After 6 months of treatment	264.3±27.9	150.4±12.8	96.3±11.5
B group	Before treatment	571.2±41.3	183.2±13.5	213.6±29.8
	After 6 months of treatment	261.3±24.6	161.5±15.8	112.3±15.2
C group	Before treatment	562.2±39.5	195.4±16.2	195.2±25.3
	After 6 months of treatment	248.3±22.5	165.2±13.9	142.6±20.4
D group	Before treatment	573.9±40.2	196.3±15.2	207.8±29.6
	After 6 months of treatment	216.8±28.4	159.4±13.8	86.3±11.5

Table 5: Comparison of the incidence of adverse reactions

Group	Headache	Nausea and vomiting	Muscle pain	Abdominal pain	Proteinuria	Total incidence
A group	4	3	1	3	0	24.4
B group	2	6	0	1	1	22.2
C group	3	2	2	1	2	22.2
D group	4	1	3	2	0	26.6

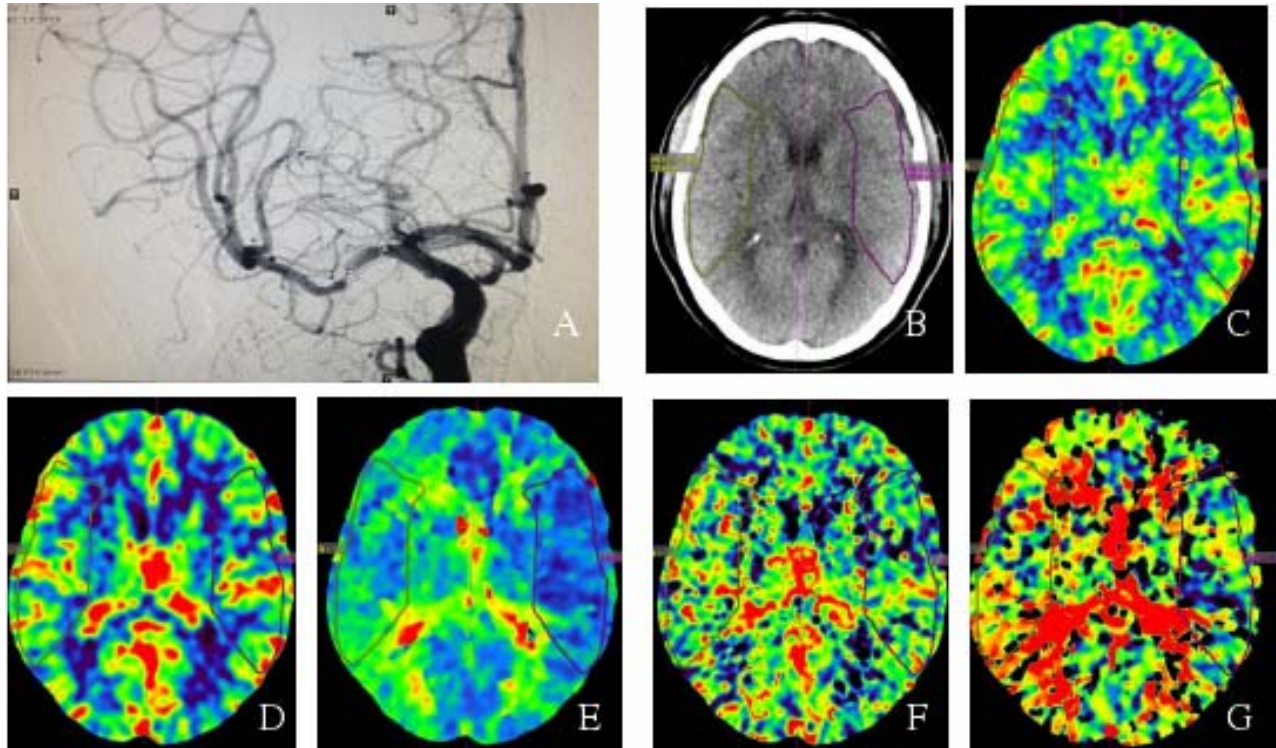


Fig. 1: DSA and CTP images of moderate arterial stenosis

After 6 months of statins treatment, the levels of TC, TG and LDL-C in the rosuvastatin group were significantly lower than those of atorvastatin group after 6 months of statins. The results of this study showed that the levels of TC, TG and LDL-C in each group were significantly lower than those before the same group, and the level of HDL-C was significantly higher than that before the same group. And after 3 months of treatment, TC, TG, LDL-C level B group <A group <C group, D group, HDL-C level B group >A group >C, D group; After 6 months of treatment, TC, TG, LDL-C level B, C group <A, D group, the difference was statistically significant.

Inflammatory response is another important cause of the development of AS (Liu *et al.*, 2012). Studies have found that TLR4 is abnormally expressed in a variety of cells in the vascular wall of AS and the most highly expressed AS is infiltrated by fat macrophages (Phillips *et al.*, 2013; Shinohara *et al.* 2013). In recent years, the study found that statins have lipid-lowering effect (Zhou *et al.*, 2016), but also can inhibit the inflammatory response, stability of atherosclerotic plaque, but the anti-inflammatory mechanism is not clear (Sandri *et al.*, 2015). The abnormal expression of TLR4 caused by activation of nuclear factor and then makes the signal transmission, up regulation of downstream MCP-1 and TGF- beta cell factor and promotes aggregation and inflammation in macrophages the start (Sheng *et al.*, 2015). The results showed that after treatment, the levels of MCP-1, TGF-, MMP-9 and water in each group were significantly lower

than those in the same group before treatment (Wang *et al.*, 2015). Many studies confirmed that activation of inflammatory reaction is one of the main causes leading to unstable atherosclerotic plaques (Li *et al.*, 2013). Extra cellular matrix (ECM) is the main substance to maintain the stability of atherosclerotic plaque.

CONCLUSION

The results of this study show that after 6 months of treatment, patients in each group were intima-media thickness (IMT), patch number, patch area were significantly lower than the same group before treatment. Headache, dizziness, nausea and vomiting and other adverse reactions of statins is common, use of high doses can cause muscle dissolution, proteinuria and other serious adverse reactions. The results of this study showed that there was no significant difference in the incidence of adverse reactions between each group. To sum up, on the basis of routine treatment, statins treatment can significantly reduce the level of blood lipids, but rosuvastatin and atorvastatin are more effective in anti inflammation and maintaining plaque stability, and the safety of the 4 drugs is better than that of AS.

ACKNOWLEDGEMENTS

We would like to thank The Second Hospital of Dalian Medical University for providing the equipment.

REFERENCES

- Abu A (2017). Video-assisted thoracoscopic surgery for non-small cell lung cancer. *Mini. Invas. Surg. Oncol.*, **1**(1): 1-11.
- Antonova O, Toncheva D and Grigorov E (2015). Bladder cancer risk from the perspective of genetic polymorphisms in the carcinogen metabolizing enzymes. *J. Buon*, **20**(6): 1397-1406.
- Cheol W, SuJin K, Jung A, Hae G and Jong L (2012). Comparison of Effects of Atorvastatin (20 mg) Versus Rosuvastatin (10mg) Therapy on Mild Coronary Atherosclerotic Plaques (from the ARTMAP Trial). *The Amer. J. Card.*, **109**(12): 1700-1704.
- Chen J (2012). Research progress of TCM in treating acute soft tissue injury. *Chi. J. Med. Guide.* **2**(2): 217-219.
- Chen X, Yang J and Peng J (2015). Case-matched analysis of combined thoracoscopic-laparoscopic versus open esophagectomy for esophageal squamous cell carcinoma. *Int. J. Clin. Exp. Med.*, **8**(8): 13516-13523.
- Chen L and Zhu X (2012). Research Progress of Aquaporin 3. *J. Med. Res.*, **6**: 8-10.
- Damyantov D, Koynov K, Naseva E and Bichev S (2015). EGFR mutations in patients with non small-cell lung cancer in Bulgaria and treatment with gefitinib. *J. Buon*, **20**(1): 136-141.
- Fang W, Ruan W (2017). Advances in uniportal video-assisted thoracoscopic surgery for non-small cell lung cancer. *Mini. Invas. Surg. Oncol.*, **1**(1): 20-30.
- Fang Q, Li Z and Zhou J (2016). Low-frequency pulsed electromagnetic fields promotes rat osteoblast differentiation in vitro through cAMP/PKA signal pathway. *J. Sout. Med. Univ.*, **36**(11): 1508-1513.
- Ghoneum M, Felo N, Nwaogu OM, Fayanju IY, Jeffe JA, Margenthaler DB (2015). Clinical trials in surgical oncology. *Asia. Pac. J. Surg. Oncol.*, **1**(2):73-82.
- Guo C, Zhang Z, Ren B, Men X (2015). Comparison of the long-term outcomes of patients who underwent laparoscopic versus open surgery for rectal cancer. *J. Buon*, **20**(6):1440-1446.
- Hisato T and Takuya U (2014). A Meta-Analysis of Randomized Head-to-Head Trials for Effects of Rosuvastatin Versus Atorvastatin on Apolipoprotein Profiles. *The Amer. J. Card.*, **113**(2): 292-301.
- Hou Z, Zhang H, Gui L, Wang W and Zhao S (2015). Video-assisted thoracoscopic surgery versus open resection of lung metastases from colorectal cancer. *Int. J. Clin. Exp. Med.*, **8**(8): 13571-13577.
- Kitano S, Iso Y, Moriyama M and Sugimachi K (1994). Laparoscopy-assisted Billroth I gastrectomy. *Surg. Laparosc Endosc.*, **4**(2): 146-148.
- Li Q, Shao X, Liu Z, Yan W and Li Y (2013). Effect of curing-injury cataplasma on expression of AQP-3 in skeletal muscles of rat model with acute injury in soft tissues. *J. Cent. South Univ.* **38**(1): 60-65.
- Liu X and Li D (2012). Wnt β -catenin Signal pathway activated by COX-2/PGE2 to regulate the expressions of human intestinal cancer cells. *Aca. J. Sec. Mil. Med. Univ.*, **11**(33): 1178-1181.
- Lin J, Huang C, Zheng C, Li P, Xie J, Wang J and Lu J (2014). A matched cohort study of laparoscopy-assisted and open total gastrectomy for advanced proximal gastric cancer without serosa invasion. *Chin. Med. J. (Engl)*, **127**(3): 403-407.
- Liu Z, Yang R and Shao F (2017). Anastomosis using complete continuous suture in uniportal video-assisted thoracoscopic bronchial sleeve lobectomy. *Minim Invasive Surg. Oncol.*, **1**(1): 31-42.
- Meryem U, Nazif A, Bulent B and Ali U (2015). Comparative effects of high-dose atorvastatin versus moderate-dose rosuvastatin on lipid parameters, oxidized-LDL and inflammatory markers in ST elevation myocardial infarction. *Atherosclerosis*, **239**(2): 439-443.
- Niu L and Li C (2007). cAMP-PKA Signal pathway and Axon Regeneration. *J. Inter. Neur. Neur.*, **34**(3): 290-293.
- Phillips JD, Nagle AP and Soper NJ (2013). Laparoscopic gastrectomy for cancer. *Surg. Oncol. Clin. N. Am.*, **22**(1): 39-57.
- Sandri A, Brunelli A, Rzyman W, Hubbard RB, Wang XF, Fraser S, Routledge T and Scarci M (2015). Pathology of non-small cell lung cancer and small cell lung cancer. *Asian Pac. J. Surg. Oncol.*, **1**(3): 113-124.
- Shinohara T and Satoh S (2013). Laparoscopic versus open D2 gastrectomy for advanced gastric cancer: A retrospective cohort study. *Surg. Endosc.*, **27**(1): 286-294.
- Sheng W, Zhang B, Chen W, Gu D and Gao W (2015). Laparoscopic colectomy for transverse colon cancer: comparative analysis of short- and long-term outcomes. *Int. J. Clin. Exp. Med.*, **8**(9): 16029-16035.
- Wang W, Zhou Y, Feng J and Mei Y (2015). Oncological and surgical outcomes of minimally invasive versus open esophagectomy for esophageal squamous cell carcinoma: A matched-pair comparative study. *Int. J. Clin. Exp. Med.*, **8**(9): 15983-15990.
- Zheng YF, Tan LK, Tan BH, Sterling H and Kane R (2015). Principles of surgical oncology. *Asian Pac. J. Surg. Oncol.*, **1**(1): 17-26.
- Zhou L, Zhang Z, Li J and Zhang Y (2016). Minimally invasive esophagectomy for early esophageal carcinoma. *Asian Pac. J. Surg. Oncol.*, **2**(4): 271-280.
- Zhigang L, Baoyi L, Dewei Z, Ben W, Yupeng L, Yao Z and Borui L (2017). Omentin-1 prevents cartilage matrix destruction by regulating matrix metalloproteinases. *Biome. & Phar.*, **92**: 265-269.