

# Clinical efficacy and safety of S-1 monotherapy in the treatment of advanced breast cancer in elderly patients

Shunyu Cui<sup>1#</sup>, Qinglong Zhao<sup>2#</sup>, Mingshi Ye<sup>1</sup>, Dehui You<sup>1</sup> and Yu Sun<sup>1\*</sup>

<sup>1</sup>Department of Breast Surgery, Jilin Cancer Hospital, Changchun, China

<sup>2</sup>Jilin Provincial Center for Disease Control and Prevention, Changchun, China

**Abstract:** To observe and analyze the therapeutic efficacy of S-1 monotherapy in the treatment of advanced breast cancer in elderly patients. A total of 180 elderly patients diagnosed as advanced breast cancer and treated at our hospital were enrolled. All patients were randomized into study group and control group, with 90 patients in each group. Of those, capecitabine monotherapy was administered in control group, while S-1 monotherapy was applied in study group. Clinical efficacy and safety of both groups were compared. By comparing recent therapeutic effects, results showed that the overall treatment efficacy was 51.11% in study group, while the value was 35.56% in control group, suggesting a higher therapeutic efficacy in study group ( $P < 0.05$ ). Also, the incidence of side effects was significantly lower in study group compared with control group ( $P < 0.05$ ). Moreover, quality of life was better preserved in study group ( $P < 0.05$ ). S-1 monotherapy was relatively effective and safe in the treatment of advanced breast cancer in elderly patients.

**Keywords:** S-1 monotherapy, advanced breast cancer in elderly patients, clinical efficacy, safety.

## INTRODUCTION

Female mammary glands consist of skin, fibrous tissue, mammary glands and fats and breast cancer is a kind of malignant tumor occurred in mammary glandular epithelium. According to relevant data, female patients accounted for 99% cases of breast cancer while male patients were only 1% (Xiao, Hu, 2016; Jiao, *et al.*, 2016; Pang, 2017). Breast cancer has become a major problem of public health due to its malignancy, threatening women's health and life safety as well as causing great impact on patients' physical and mental condition.

Patients with advanced breast cancer present with various clinical symptoms. Some of the more common symptoms are breast lumps (as shown in fig. 1), paroxysmal sticking or dull pain, nipple discharge (as shown in fig. 2), changes in mammary skin and appearance, etc. Currently, a more effective treatment for advanced breast cancer is chemotherapy combined with bio-immunotherapy. For those chose chemotherapy, tumor response, symptoms alleviation and toxic action must be considered scrupulously for a scientific choice (Iwata, *et al.*, 2016). Adopting effective chemotherapy drugs with lower toxicity for maintenance treatment can guarantee higher therapeutic efficacy and safety. In this research, we perform a rigorous analysis on the clinical efficacy and safety of S-1 in the treatment of advanced breast cancer in elderly patients. Results are presented as below.

## MATERIALS AND METHODS

### General data

A total of 180 elderly patients who had been diagnosed as

advanced breast cancer and treated at Jilin Cancer Hospital from January 2014 to March 2018 were enrolled as research objects.

All patients were clinically reviewed and definitely diagnosed. All patients were at stage IIIB-IV, with life expectancy of more than 3 months. Patients with cardiac, hepatic or renal dysfunction and patients who had contraindications for chemotherapy were excluded. All selected patients have signed informed consents. This study obtained approval from Ethical Committee of hospital. All patients were randomized into study group and control group, with 90 patients in each group. Of those, there were 35 cases of invasive ductal carcinoma, 36 invasive lobular carcinoma and 19 medullary carcinoma and mucinous carcinoma in study group, all presented with distant metastases. The average age of the study group was  $68.3 \pm 3.4$  years, ranging from 60 to 75 years. Moreover, there were 30 cases of invasive ductal carcinoma, 32 invasive lobular carcinoma and 28 medullary carcinoma and mucinous carcinoma in control group, all presented with distant metastases. The average age of the control group was  $67.5 \pm 3.8$  years, ranging from 62 to 75 years. Data obtained from both groups were comparable ( $P > 0.05$ ).

### Methods

All patients were subjected to chemotherapy. Symptomatic treatment like antiemetic drugs was performed and the dosage of chemotherapy drugs was calculated by body surface area. On this basis, capecitabine was administered in control group, while S-1 was applied in study group. Control group: capecitabine was administered at a dosage of  $2000 \text{mg/m}^2$ , bid, for 14 consecutive days. Then this regimen was repeated at day

\*Corresponding author: e-mail: sy1988sy@yeah.net

21. Study group: 80mg S-1 was applied in patients with body surface area less than  $1.25\text{m}^2$ , while 100mg was applied in those with body surface area between  $1.25\text{m}^2$  and  $1.5\text{m}^2$  and 120 mg was applied in those with body surface area more than  $1.5\text{m}^2$ . It was administered twice a day, after breakfast and dinner, for 14 consecutive days. Then this regimen was repeated at day 21.

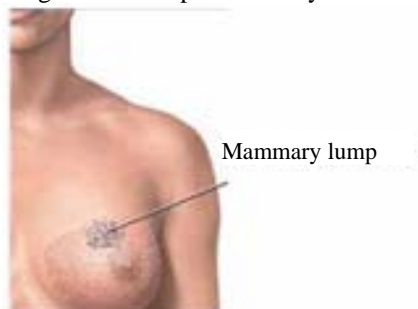

Fig. 1: Mammary lump

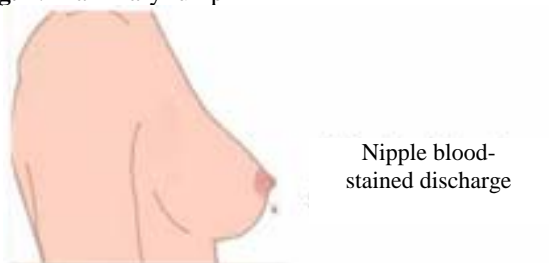


Fig. 2: Nipple discharge

### Observational indexes

First, recent overall therapeutic effects of both groups were evaluated. According to the uniform standard, The therapeutic effect of the two groups was judged strictly, including 4 levels, namely complete remission, partial remission, progression and stabilization (Lee, *et al.*, 2017). Of those, complete remission refers to almost complete disappearance of lesion after treatment, no recurrence within 4 weeks; partial remission refers to reduction of more than 30% lesion area, no newly developed lesion within 4 weeks; stabilization refers to reduction of less than 30% lesion area, no newly developed lesion within 4 weeks; progression refers to no reduction or even enlargement of lesion area, newly developed lesion was observed. The time of disease progression begins from the date of the first treatment of this protocol to the date when disease progresses were proved by objective evidence. The total survival time begins from the date of the first treatment of this protocol to the date of death or the date of the last follow-up visit. Second, the incidence of side effects was evaluated. Toxic reactions were strictly observed and classified by the manifestation of acute and sub-acute toxicity and grading standards for anticancer drugs. Finally, a health status questionnaire (SF-36) (Hao, 2018) was used to investigate the patients' physiological scores, psychological scores, social scores, and overall quality of life scores.

## STATISTICAL ANALYSIS

Statistical analyses were performed using SPSS21.0. All quantitative data were expressed as mean  $\pm$  standard variance ( $\pm s$ ), and inter group comparisons were carried out with t-test. Enumeration data were expressed as natural number (n) and percentage (%), and inter group comparisons were made with chi-square test.  $P < 0.05$  was considered as statistically significant.

## RESULTS

### Comparisons of recent total therapeutic efficacy between both groups

As shown in table 1, after different treatment regimen, study group had higher therapeutic efficacy compared with control group ( $P < 0.05$ ).

Stages of Breast Cancer

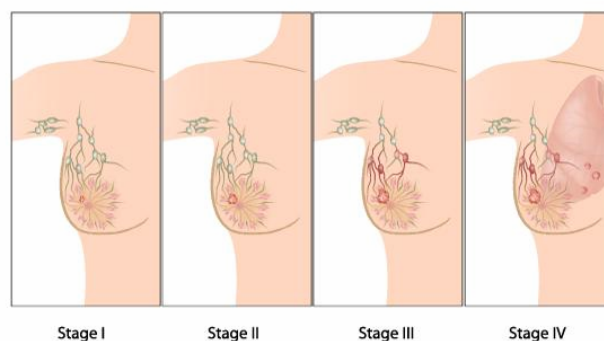


Fig. 3: Distant metastasis of breast cancer

### Comparisons of the incidence of side effects between both groups.

As shown in table 2, compared with control group, patients in study group had lower incidences of nausea and vomiting, hand-foot syndrome and anemia ( $P < 0.05$ ). But no significance difference in other side effects (bone marrow depression, thrombocytopenia, liver damage, etc.) was observed between both groups ( $P > 0.05$ ).

### Comparisons of the quality of life between both groups

As shown in table 3, quality of life was better preserved in study group ( $P < 0.05$ ).

## DISCUSSION

Currently, there is not any standard of accurate diagnosis and treatment for patients with advanced breast cancer. As shown in fig. 3, surgical treatment program is not that meaningful because distant metastasis occurs in most patients. Even worse, it can increase the chance of infection and the rate of trauma. Therefore, conservative treatment measures are relatively ideal. Paclitaxel-based or anthracycline-based combination chemotherapy is the main therapeutic approach. However, due to the poor

**Table 1:** Comparisons of recent total therapeutic efficacy ( $\bar{x} \pm s$ )

Group	Complete remission	Partial remission	Stabilization	Progression	Recent total therapeutic efficacy
Study group (n=90)	10	36	20	24	46(51.11)
Control group (n=90)	8	24	28	30	32(35.56)
t					12.20
P					<0.05

**Table 2:** Comparisons of the incidence of side effects [n (%)]

Side effects	Study group (n=90)	Control group (n=90)	$\chi^2$	P
Bone marrow depression	50(55.56)	55(61.11)	0.23	>0.05
Thrombocytopenia	60(66.67)	62(68.89)	0.10	>0.05
Nausea and vomiting	30(33.33)	76(84.44)	15.08	<0.05
Hand-foot syndrome	22(24.44)	74(82.22)	12.17	<0.05
Anemia	48(53.33)	80(88.89)	10.29	<0.05
Diarrhea	55(61.11)	52(57.78)	0.09	>0.05
Liver damage	48(53.33)	50(55.56)	0.32	>0.05
Angular cheilitis	39(43.33)	45(50.00)	1.06	>0.05

**Table 3:** Comparisons of the quality of life ( $\bar{x} \pm s$ )

Group	Cases	Physical function	Psychological function	Social function	Overall life quality
Study group	90	0.97±0.32	1.30±0.52	1.29±0.15	4.81±0.55
Control group	90	0.43±0.29	1.01±0.05	0.82±0.23	3.26±1.20
t		3.58	5.31	5.09	8.36
P		<0.05	<0.05	<0.05	<0.05

physical condition and poor tolerance, patients with advanced breast cancer possibly could not withstand chemotherapy toxicity. It is particularly critical to adopt safe and effective treatment programs for long-term use (Zhang, 2015; Danishada, *et al.*, 2017).

S-1 is a compound preparation made by a certain proportion of tegafur, gimeracil and oteracil potassium (Sharma, *et al.*, 2017; Fei, *et al.*, 2018; Zhang *et al.*, 2011). Among these, tegafur can be converted into fluorouracil *in vivo*, thus it can exert better availability by oral administration. Furthermore, gimeracil can inhibit the catabolism of fluorouracil caused by dihydropyrimidine dehydrogenase, resulting in a higher concentration of fluorouracil in the blood of tumor tissue. In addition, oteracil potassium can effectively prevent the phosphorylation of fluorouracil and greatly reduce the toxicity of drugs. Currently, S-1 has been widely used in the treatment of breast cancer. In this study, results showed that after taking different treatment options, the overall treatment efficacy was higher in the study group treated with S-1 compared with the control group, accompanied with less side effects. So S-1 is more reliable.

## CONCLUSION

In summary, application of S-1 in the treatment of elderly patients with advanced breast cancer could produce

relatively better results, and simultaneously reduce side effects, supplying more safety and reliability. Therefore, S-1 is worth for popularization and application.

## ACKNOWLEDGEMENTS

The first two authors (Shunyu Cui, Qinglong Zhao) contributed equally to this work.

## REFERENCES

- Danishada KKA, Sharma U and Saha RG (2017). Assessment of therapeutic response of locally advanced breast cancer (LABC) patients undergoing neoadjuvant chemotherapy (NACT) monitored using sequential magnetic resonance spectroscopic imaging (MRSI). *NMR in Biomedicine*, **23**(3): 233-241.
- Fei F, Chen C, Xue J, Di GH, Lu JS, Liu GY, Shao ZM, Wu J (2013). Efficacy and safety of docetaxel combined with oxaliplatin as a neoadjuvant chemotherapy regimen for Chinese triple-negative local advanced breast cancer patients: A prospective, open, and unicentric phase II clinical trial. *American Journal of Clinical Oncology: Cancer Clinical Trials*, **36**(6): 545-551.
- Hao XL (2018). Observation on clinical efficacy of tegafur monotherapy in the treatment of advanced breast cancer. *China Practical Medical*, **13**(09): 109-

110.

- Iwata H, Masuda N and Ohno S (2016). A randomized, double-blind, controlled study of exemestane versus anastrozole for the first-line treatment of postmenopausal Japanese women with hormone-receptor-positive advanced breast cancer. *Breast Cancer Res. Treat.*, **139**(2): 441-451.
- Jiao Y, Ning J, Wang F and Gu KS (2016). Orally administered fluorinated pyrimidines (S-1 versus capecitabine) in women with metastatic breast cancer in Chinese patients. *Chinese Journal of Cancer Prevention and Treatment*, **23**(07): 452-456.
- Lee DS, Kim SH and Kim S (2017). Prognostic significance of breast cancer subtype and p53 over expression in patients with locally advanced or high-risk breast cancer treated using upfront modified radical mastectomy with or without post-mastectomy radiation therapy. *Int. J. Clin. Oncol.*, **17**(5): 447-455.
- Pang ZJ (2017). Observation on efficacy and safety of tegafur monotherapy in the treatment of advanced breast cancer. *Chinese Journal of Modern Drug Application*, **11**(23): 79-81.
- Sharma U, Danishad KKA and Seenu V (2017). Longitudinal study of the assessment by MRI and diffusion-weighted imaging of tumor response in patients with locally advanced breast cancer undergoing neoadjuvant chemotherapy. *NMR in Biomedicine*, **22**(1): 104-113.
- Xiao Y and Hu G (2016). Comparisons of clinical effect and safety of the treatment with S-1 and capecitabine for the elderly patients with advanced breast cancer. *World Latest Medicine Information*, **16**(30): 16-17.
- Zhang Q, Huang ZS, Wang B, Wu Y, Ma QL and Wang CZ (2011). Comparison of clinical characteristics of chronic rhinitis and sinusitis-related cough and gastroesophageal reflux cough. *Chinese Journal of Respiratory and Critical Care Medicine*, **5**: 462-465.
- Zhang WP (2015). Feasibility research of tegafur and capecitabine for the elderly patients with advanced breast cancer. *Strait Pharmaceutical Journal*, **27**(07): 165-166.