

# Effect of *Lactobacillus casei* on serum interleukins following enteropathogenic *E. coli* infection in experimental rabbits

Iqra Fayyaz<sup>1</sup>, Muhammad Asif Zahoor<sup>1\*</sup>, Muhammad Shahid<sup>2</sup>,  
Muhammad Hidayat Rasool<sup>1</sup> and Zeeshan Nawaz<sup>1</sup>

<sup>1</sup>Department of Microbiology, Government College University, Faisalabad, Pakistan

<sup>2</sup>Department of Bioinformatics and Biotechnology, Government College University, Faisalabad, Pakistan

**Abstract:** In the present study we investigated the pro-inflammatory and anti-inflammatory effect of *Lactobacillus casei* following infection with multi-drug resistant enteropathogenic *Escherichia coli* infection in experimental rabbits. For this purpose, 40 adult rabbits were divided into different groups and were infected with multi-drug resistant *E. coli* AZ1 strain except the control groups. The rabbits were orally administered with *L. casei* SABA6 strain in two different ways i.e. pre-treatment and post-treatment and both were continued for 7 days. The rabbits were sacrificed sequentially at 0, 4, 7 and 10 days post infection (dpi). Serum and intestinal tissue samples were collected from each rabbit. Intestinal tissue samples were subjected to histopathological examination that showed microscopic lesions at 4 and 7 dpi among infected group. The serum samples were processed for determination of Interleukin-6 (IL-6, pro-inflammatory) and Interleukin-10 (IL-10, anti-inflammatory) using ELISA. It was found that oral administration of *L. casei* SABA6 reduces the eruption of intestinal epithelial cells and reduces the incidence of diarrhea. Further, *L. casei* SABA6 also resulted in immuno modulation by significant increase in concentration of IL-6 and IL-10 particularly at 4 and 7 dpi and protects against *E. coli* AZ1 infection. Altogether, it was concluded that increased IL-6 and IL-10 levels were responsible for protection against EPEC infections. The sequential sacrifice of experimental animals could be adopted for future studies to find out pathogenesis and virulence mechanism of EPEC infections along with protective efficacy of different probiotics.

**Keywords:** *Lactobacillus casei*, diarrhea, Interleukin-6, Interleukin-10, *Escherichia coli*.

## INTRODUCTION

The members of the family *Enterobacteriaceae* have a substantial impact in the gastrointestinal tract (GIT) (Moura *et al.*, 2009). While, enteropathogenic *Escherichia coli* (EPEC) is one of the top ranked bacterium in this family and is responsible for several disorders including diarrhea in infants, children and adults throughout the world (Allard *et al.*, 2017, Gallardo *et al.*, 2017). This is also a well-established fact that EPEC associated diarrhea is the second highest cause of mortalities among infants following the rotavirus infections (Lanata *et al.*, 2013). EPEC does not produce any toxins and only exerts the pathogenic effects by attachment/effacement (A/E) lesions in the intestines (Agin *et al.*, 2005, Das *et al.*, 2013). At present, significantly increased antimicrobial resistance has been reported among EPEC isolates in different regions of the world. For example, the antimicrobial resistance or multi-drug resistance is particularly high in developing countries (Qadri *et al.*, 2005, Das *et al.*, 2013). This increased resistance resulted in research on alternative control strategies including probiotics.

In general, the probiotics are beneficial bacteria which do not invade the intestinal epithelial cells and are helpful in

regaining the microbial flora of GIT (Llewellyn and Foey, 2017). *Lactobacillus* is an important probiotic with almost 140 identified species including *L. casei* (Abriouel *et al.*, 2017; Jacouton *et al.*, 2017). Intestinal microflora can be altered by oral introduction of *L. casei*. It also aids in the treatment of different intestinal infections. It also decreases the chances of development of bacterial carcinoma in GIT (Brown and Valiere, 2004). Previous studies showed the beneficial role of probiotics in diarrhea associated with bacterial infections or diarrhea caused by rotavirus infections among children and infants (Baldi *et al.*, 2012). *L. casei* also has a beneficial role in the large intestine by normalizing the intestinal microflora as well as by modulating the mucosal immunity (Jandhyala *et al.*, 2015; Coqueiro *et al.*, 2017; Jacouton *et al.*, 2017). This immunity is also enhanced by the oral administration of *Lactobacillus* due to production of bioactive soluble molecules e.g. organic acids, bacteriocins, hydrogen peroxide and fatty acids (Nobe *et al.*, 2009, Long *et al.*, 2010, Berings *et al.*, 2017). Effective probiotics help in the removal of other microorganism after adherence to cells.

At present, very less information is available about the systemic effects of *L. casei* including modulation of Interleukin-6 (IL-6, a pro-inflammatory cytokine) and Interleukin-10 (IL-10, an anti-inflammatory cytokine). Few studies described that the concentration of IL-6 and

\*Corresponding author: e-mail: drasifzahoor@gcuf.edu.pk

IL-10 is increased or altered following *L. casei* treatment (Sharma *et al.*, 2014, Yang *et al.*, 2017). However, the effect of *L. casei* on the serum concentration of IL-6 and IL-10 along with its protective effect following EPEC infection is not well defined. Therefore, in this study, we have focused on the beneficial effects of *L. casei* following the EPEC infection in experimental rabbit model, a simulatory model to human. The protective effect by *L. casei* was investigated by histopathological examination of intestinal epithelium by sacrificing the experimental rabbits in sequential manner. Further, the systemic anti-inflammatory effect of *L. casei* was estimated by monitoring serum concentrations of IL-6 and IL-10 in experimental rabbits following the infection with EPEC.

## MATERIALS AND METHODS

### *Enteropathogenic Escherichia coli*

Well characterized multi-drug resistant EPEC was used in the current study. The strain was recently characterized (*Escherichia coli* AZ1 strain, GenBank Accession Number= MF185146.1). The *E. coli* AZ1 strain was re-cultured using brain heart infusion broth (Oxoid™, UK) and the final bacterial count adjusted to  $1 \times 10^8$  CFU/mL as described (Ogawa *et al.*, 2001). Briefly, the turbid growth was centrifuged and bacterial pellet was dissolved in 3-5 mL of phosphate buffered saline (PBS) and subjected to spectrophotometry at 600 nm wave length.

### *Lactobacillus casei*

Well characterized strain (*Lactobacillus casei* SABA6, GenBank Accession Number= KX599358) was used in the current study. The strain was re-cultured using MRS broth (Oxoid™, UK). The concentration of *L. casei* SABA6 was also adjusted to  $1 \times 10^8$  CFU/mL as described for *E. coli* AZ1 strain.

### *Experimental Rabbits and in vivo Studies*

For the experimental trails, a total of 40 adult rabbits (1 year old) were purchased from local market. The rabbits were housed in animal room and were provided with green fodder and clean drinking water ad-lib. The rabbits were provided 2 weeks of adaptation time prior to the start of study. The rabbits were divided into different groups and were orally infected with *E. coli* AZ1 strain followed by *L. casei* SABA6 treatment. The details were described in table 1. *E. coli* AZ1 infection was given orally once to the rabbits. The described concentration of *L. casei* SABA6 was administered orally to the rabbits twice a day for a period of 7 days. *L. casei* SABA6 administration was started in Group-V (pre-treatment group) two days prior to the infection. The rabbits were routinely monitored for any clinical signs. Two animals from each group were sequentially sacrificed on 0, 4, 7 and 10 day of post infection (dpi) as described in previous animal studies (Zahoor *et al.*, 2011). The sequential

sacrifice was conducted to access the impact of *E. coli* AZ1 infection and protection efficacy of *L. casei* SABA6 strain. Blood and intestinal tissue samples were collected from each rabbit on each day of sacrifice.

### *Histopathological examination*

During the sequential sacrifice, the whole intestine was evaluated for the presence of any abnormality and small piece of intestine having lesions was collected and placed in 10% buffered formalin and processed for histopathological examination as described (Zahoor *et al.*, 2011). The intestinal tissues were subsequently embedded in paraffin blocks and were processed for slicing using microtome (Shandon AS 325 Retraction, China). 4-5  $\mu$ m slices were directly placed on surface of clean glass slides and were placed in an incubator at 37°C overnight. The slides were then processed for hematoxylin and eosin staining (H and E). In the first step, paraffin was removed from tissue by placing the slides in xylene container followed by removal of water contents using ethanol and finally subjected to H and E staining. For this purpose, the slides were dipped in hematoxylin container for 4 minutes followed by rinsing with tap water. The slides were subjected to acid-alcohol solution to remove extra stain and again rinsed with tap water. After that, slides were subjected to eosin stain for 2 minutes and rinsed with tap water. At the end, the cover slips were placed and the slides were fixed.

## STATISTICAL ANALYSIS

### *Cytokine Analysis*

Serum was isolated from each blood sample. All of the sera samples were processed for evaluation of IL-6 and IL-10 using two different commercially available ELISA kits (Rabbit Interleukin-6 ELISA Kit and Rabbit Interleukin-10 ELISA Kit, USA) according to the protocol described by the manufacturer. For each ELISA, in the first step, 100  $\mu$ L of standard solutions and each serum sample were added in respective wells of ELISA plate followed by 2 hours incubation at 37°C. Later on, all of the fluid was removed from each well without washing. In the next step, 100  $\mu$ L of 1X Biotin antibody was added in each well and incubated at 37°C for 1 hour followed by three times washing using 200  $\mu$ L of washing buffer. 100  $\mu$ L of HRP-avidin was then added to each well followed by 1 hour incubation at 37°C followed by washing. 90  $\mu$ L of TMB substrate was added to each well followed by incubation for 15-30 minutes at 37 °C. Finally, 50  $\mu$ L of stop solution was added to each well and optical density was measured at 450 nm wavelength.

## RESULTS

The multi-drug resistant *E. coli* AZ1 strain was used in the current study which was originally isolated from a five years old child suffering from severe diarrhea. The

strain was resistant to amoxicillin-clavulanic acid, ciprofloxacin, gentamicin, cefoperazone and ofloxacin. The probiotic *L. casei* SABA6 strain was isolated previously from continental yogurt (Dahi) sample. The strain was tolerant to bile salts and acidic pH and showed *in vitro* antagonistic activity against multi-drug resistant *E. coli* and *Salmonella typhi* isolates.

None of the rabbits showed any clinical signs among Group-I (control group) and Group-II (probiotic group). However, the rabbits in Group-III (*E. coli* AZ1 strain infection group) showed signs of mild diarrhea. The diarrhea started as early as on day 3 which continued up to day 7. Similarly the Group-IV and Group-V (*L. casei* SABA6 treatment groups) showed very mild signs of diarrhea. The diarrhea started as early as on day 3 which continued up to day 4 or 5. Gross lesions were observed in intestine from Group-III on 4, 7 and 10 dpi. However, the Group IV and V showed mild haemorrhages only on day 4 post infection. Histopathological examination of intestinal tissue showed proliferation of different cells including lymphocytes, monocytes, basophils and neutrophils in *E. coli* AZ1 infection group whereas, the protective effect was observed among *L. casei* SABA6 treatment groups as shown in fig. 1(A-D).

The serum concentration of IL-6 was found to be

increased among the Group-III, IV and V at 4 and 7 dpi, whereas, no alterations were observed in Group-I and Group-II as described in table 2. The serum concentration of IL-10 was found to be increased among the Group-III at 4 and 7 dpi. However, among the Group-II, IV and V significant increase was observed at 4 and 7 dpi as described in table 3. Both of the cytokines i.e. IL-6 and IL-10 concentrations were found to be significantly altered among different groups as described in table 2 and table 3, respectively.

## DISCUSSION

This is a well established fact that GIT of human and animals harbors a diverse microflora ranging from normal to pathogenic bacteria and the significant impact is primarily due to the family *Enterobacteriaceae* (Moura et al., 2009). Among these, the EPEC strains are the main etiological agent for acute and chronic diarrhea in infants and children as well as in adults throughout the world (Lanata et al., 2013; Dupont et al., 2016). Further, the probiotics has significant impact in the GIT environment of the host (Jandhyala et al., 2015, Coqueiro et al., 2017). *Lactobacillus* is among the most important probiotic (Abriouel et al., 2017, Jacouton et al., 2017). Therefore, in the current study we investigated the pro-inflammatory and anti-inflammatory potential of indigenous isolated

**Table 1:** Treatment plan of experimental rabbits

Groups	Treatments
I	Control
II	<i>L. casei</i> SABA6 treatment
III	<i>E. coli</i> AZ1 infection
IV	<i>E. coli</i> AZ1 infection followed by <i>L. casei</i> SABA6 treatment
V	Pre-treatment with <i>L. casei</i> SABA6 followed by oral infection with <i>E. coli</i> AZ1

**Table 2:** Levels of IL-6 (pg/mL) at 0, 4, 7 and 10 dpi

Interleukin-6 pg/mL						
Dpi	Group-I	Group-II	Group-III	Group-IV	Group-V	P-Value
0	248	240	245	249	252	0.000
4	250	248	510	490	502	0.003
7	247	260	320	310	322	0.000
10	246	252	252	238	242	0.000
P-Value	0.238	0.000	0.013	0.012	0.012	

**Table 3:** Levels of IL-10 (pg/mL) at 0, 4, 7 and 10 dpi

Interleukin-10 pg/mL						
Dpi	Group-I	Group-II	Group-III	Group-IV	Group-V	P-Value
0	80	78	84	80	78	0.000
4	75	150	118	161	172	0.002
7	78	217	143	203	209	0.003
10	83	189	95	184	179	0.003
P-Value	0.000	0.013	0.004	0.011	0.011	

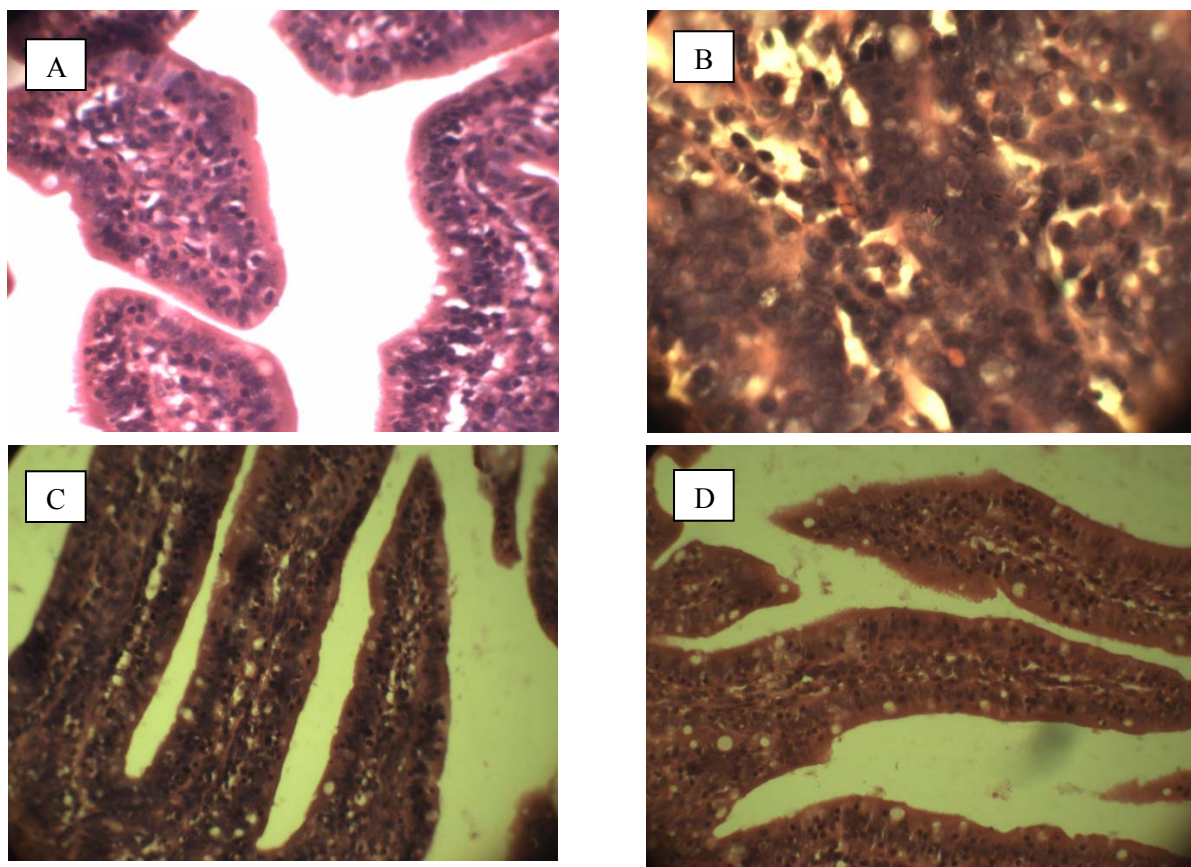
probiotic strain *L. casei* SABA6 following the indigenously isolated multi-drug resistant enteropathogenic strain *E. coli* AZ1 in experimental rabbits.

The experimental rabbits were used to investigate the pathogenesis and progression of *E. coli* AZ1 strain and the systemic immuno-modulatory effects of *L. casei* SABA6 were monitored by estimating IL-6 and IL-10 concentration in the serum. The range of animal for experimental studies to demonstrate pathogenesis and progression of *E. coli* infection is limited to pigs, rabbits or mice (Sharma *et al.*, 2014; Crepin *et al.*, 2016, Rafiq *et al.*, 2018). It has been described previously that development of disease could be monitored by evaluation of clinical signs of diarrhea, blood and serum profiles and cytokines analysis along with histopathological examination of intestinal tissue (Nobe *et al.*, 2009, Saravia *et al.*, 2017). Similarly, the efficacy of *Lactobacillus* could be studied *in vitro* or in experimental mice or rabbits. This beneficial impact ranged from competitive exclusion of pathogenic bacteria from GIT to systemic immunomodulation by alterations of certain cytokines (Mazaya *et al.*, 2015). The efficacy of *Lactobacillus* could be evaluated by determining different parameters including blood and serum profiles and cytokines analysis along with histopathological

examination of intestinal tissue (Sharma *et al.*, 2017). The infectious dose of *E. coli* AZ1 was administered orally once during the study, whereas, *L. casei* SABA6 treatment was continued up to 7 dpi. However, the pre-treatment of *L. casei* was started 2 days prior to infection among Group-V. The concept of pre-treatment or post-treatment is described recently (Feng *et al.*, 2017, Tzang *et al.*, 2017). The rabbits were routinely monitored for any clinical signs. Two animals from each group were sacrificed at 0, 4, 7 and 10 day of post infection (dpi). The sequential sacrifice of experimentally infected animals was previously described (Zahoor *et al.*, 2011). However, the concept of sequential sacrifice following the *E. coli* infection along with probiotic treatment is a new approach adopted in this study.

One of the recent findings has shown the significance of histological examination for determination of microscopic lesions of intestine following the treatment of colorectal cancer using probiotics in mice (Jacouton *et al.*, 2017) or to investigate the systemic or intestinal *E. coli* infection in rabbits (Saravia *et al.*, 2017) or reduction in liver damage in pigs (Zhao *et al.*, 2017).

The postmortem examination of the intestinal tissue indicated few gross lesions including hemorrhages on



**Fig. 1:** Microscopic Examination of Intestinal Tissue at 7 dpi. A= Group-I, B= Group-II, C= Group-IV, D= Group-V

intestinal mucosa. The histopathological investigations showed proliferation of different cells including lymphocytes, monocytes, basophils and neutrophils at intestinal epithelium. However, the epithelial cells were found intact except *E. coli* AZ1 infection group at 4 and 7 dpi. This indicated that *L. casei* SABA6 strain has potential impact at intestinal mucosa to competitively exclude the *E. coli* infection. Further, attachment and effacement lesion were also not observed during histological examinations. Previous studies also described that probiotics particularly *L. casei* has beneficial impact at intestinal epithelium of rabbits or mice (Agin et al., 2005).

In the final phase of the current study, serum samples were subjected to find out the concentration IL-6 (pro-inflammatory) and IL-10 (anti-inflammatory) as described in different studies (Sharma et al., 2014; Yang et al., 2017). The concentration of IL-6 was increased among Group-III, IV and V at 4 and 7 dpi, whereas its concentration decreases at 10 dpi. This indicated that IL-6 was secreted as pro-inflammatory during early phase of infection. One of the previous studies showed that an increased concentration of IL-6 was associated with decreased duration of EPEC infection (Long et al., 2010). In the current study, the concentration of IL-6 was found slightly decreased among the *L. casei* SABA6 treatment group (Group-II). A similar trend of reduced IL-6 levels has been reported recently following the treatment with *Lactobacillus* in mice model (Tzang et al., 2017). One of the previous studies described that IL-6 was required to control systemic *E. coli* infection (Darrymples et al., 1996). It could be concluded that IL-6 has potential pro-inflammatory response and increased concentrations are associated with decreased duration of EPEC infection.

The concentration IL-10 was found to be increased among the *E. coli* AZ1 infected group (Group-III) at 4 and 7 dpi. However, among the Group-II, IV and V significant increase was observed at 4 and 7 dpi. This indicated that *L. casei* SABA6 strain showed strong anti-inflammatory activity at GIT as described in previous studies (Fidan et al., 2008, Long et al., 2010). However, one of the previous studies described decreased levels of IL-10 in mice following the infection with EPEC (Sharma et al., 2014). In conclusion, increased concentration of IL-10 has association with asymptomatic infection at gastric mucosa and decreased concentration of IL-10 was found to be associated with symptomatic EPEC infection as described recently (Sharma et al., 2014).

## CONCLUSION

The microscopic lesions at intestinal epithelium were developed between 4 to 7 days following the oral infection with multi-drug resistance EPEC. The oral administration of *L. casei* SABA6 strain has modulated

the IL-6 and IL-10 levels and is responsible for protection against EPEC infection. That indicated a potential of probiotics to treat diarrhea associated with bacterial infections. Further, the sequential sacrifice could be adopted for future studies to find out detailed pathogenesis, virulence mechanism of EPEC infection along with protective efficacy of different probiotics among experimental animals.

## REFERENCES

- Abriouel H, Perez Montoro B, Casimiro-Soriguer CS, Perez Pulido AJ, Knapp CW, Caballero Gomez N, Castillo-Gutiérrez S, Estudillo-Martínez MD, Gálvez A, and Benomar N (2017). Insight into potential probiotic markers predicted in *Lactobacillus pentosus* MP-10 Genome Sequence. *Front. Microbiol.*, **8**: 891.
- Agin TS, Zhu C, Johnson LA, Thate TE, Yang Z and Boedeker EC. (2005). Protection against hemorrhagic colitis in an animal model by oral immunization with isogenic rabbit enteropathogenic *Escherichia coli* attenuated by truncating intimin. *Infect. Immun.*, **73**: 6608-19.
- Allard MW, Bell R, Ferreira CM, Gonzalez-Escalona N, Hoffmann M, Muruvanda T, Ottesen A, Ramachandran P, Reed E, Sharma S, Stevens E, Timme R, Zheng J, and Brown EW (2017). Genomics of foodborne pathogens for microbial food safety. *Curr. Opin. Biotechnol.*, **49**: 224-229.
- Baldi DL, Higginson EE, Hocking DM, Praszkiar J, Cavaliere R, James CE, Bennett-Wood V, Azzopardi KI, Turnbull L, Lithgow T, Robins-Browne RM, Whitchurch CB and Tauschek M (2012). The type II secretion system and its ubiquitous lipoprotein substrate, SsIE, are required for biofilm formation and virulence of enteropathogenic *Escherichia coli*. *Infect. Immun.* **80**: 2042-2052.
- Berings M, Karaaslan C, Altunbulakli C, Gevaert P, Akdis M, Bachert C and Akdis CA (2017). Advances and highlights in allergen immunotherapy: On the way to sustained clinical and immunologic tolerance. *J. Allergy Clin. Immunol.*, **140**: 1250-67.
- Brown AC and Valiere A (2004). Probiotics and medical nutrition therapy. *Nutr. Clin. Care*, **7**: 56-68
- Coqueiro AY, de Oliveira Garcia AB, Rogero MM and Tirapegui J (2017). Probiotic supplementation in sports and physical exercise: Does it present any ergogenic effect?. *Nutr. Health.* **23**: 239-249.
- Crepin VF, Collins JW, Habibzay M and Frankel G (2016). *Citrobacter rodentium* mouse model of bacterial infection. *Nat. Protoc.*, **11**: 1851-76.
- Darrymples S, Slattery R, Aud D, Krishna M, Lucian LA and Murray R (1996). Interleukin-6 is required for a protective immune response to systemic *Escherichia coli* Infection. *Infect. Immun.* **64**: 3231-3235.
- Das JK, Tripathi A, Ali A, Hassan A, Dojosoeandy C and Bhutta ZA (2013). Vaccines for the prevention of

- diarrhea due to *Cholera*, *shigella*, ETEC and rotavirus. *BMC Public Health*, **13**(Suppl 3): S11.
- Dupont A, Sommer F, Zhang K, Repnik U, Basic M, Bleich A, Kühnel M, Bäckhed F, Litvak Y, Fulde M, Rosenshine I, and Hornef MW (2016). Age-Dependent Susceptibility to Enteropathogenic *Escherichia coli* (EPEC) Infection in Mice. *PLoS Pathog.*, **12**: e1005616.
- Feng JR, Wang F, Qiu X, McFarland LV, Chen PF, Zhou R, Liu J, Zhao Q and Li J (2017). Efficacy and safety of probiotic-supplemented triple therapy for eradication of *Helicobacter pylori* in children: a systematic review and network meta-analysis. *Eur. J. Clin. Pharmacol.* **73**: 1199-1208.
- Fidan I, Kalkan A, Yesilyurt E, Yalcin B, Erdal B, Kustimur S and Imir T (2008). Effects of *Saccharomyces boulardii* on cytokine secretion from intraepithelial lymphocytes infected by *Escherichia coli* and *Candida albicans*. *Mycoses*, **52**: 29-34.
- Gallardo P, Izquierdo M, Vidal RM, Chamorro-Veloso N, Rossello-Mora R, O'Ryan M and Farfán MJ (2017). Distinctive gut microbiota is associated with diarrheagenic *Escherichia coli* infections in Chilean children. *Front. Cell. Infect. Microbiol.*, **7**: 424.
- Jacouton E, Chain F, Sokol H, Langella P and Bermudez-Humaran LG (2017). Probiotic strain *Lactobacillus casei* B123 Prevents colitis-associated colorectal cancer. *Front. Immunol.* **8**: 1553.
- Jandhyala SM, Talukdar R, Subramanyam C, Vuyyuru H, Sasikala M and Reddy DN (2015). Role of the normal gut microbiota. *World J. Gastroenterol.* **21**: 8787-8803.
- Lanata CF, Fischer-Walker CL, Olascoaga AC, Torres CX, Aryee MJ and Black RE (2013). Global causes of diarrheal disease mortality in children <5 Years of Age: A Systematic Review. *PLoS One.*, **8**: e72788.
- Llewellyn A and Foey A (2017). Probiotic modulation of innate cell pathogen sensing and signaling events. *Nutrients*. **9**: 1156.
- Long KZ, Rosado JL, Santos JI, Haas M, Al Mamun A, DuPont HL, Nanthakumar NN and Estrada-Garcia T (2010). Associations between mucosal innate and adaptive immune responses and resolution of diarrheal pathogen infections. *Infect. Immun.*, **78**: 1221-1228.
- Mazaya B, Hamzawy MA, Khalil MA, Tawkol WM and Sabit H (2015). Immunomodulatory and antimicrobial efficacy of Lactobacilli against enteropathogenic infection of *Salmonella typhi*: *In-vitro* and *in-vivo* study. *Int. J. Immunopathol. Pharmacol.* **28**: 469-478.
- Moura RA, Sircili MP, Leomil L, Matte MH, Trabulsi LR, Elias WP, Irino K, and Pestana de Castro AF (2009). Clonal relationship among atypical enteropathogenic *Escherichia coli* strains isolated from different animal species and humans. *Appl. Environ. Microbiol.*, **75**: 7399-7408.
- Nobe R, Nougayrède JP, Taieb F, Bardiau M, Cassart D, Navarro-Garcia F, Mainil J, Hayashi T, Oswald E. (2009). Enterohaemorrhagic *Escherichia coli* serogroup O111 inhibits NF- $\kappa$ B-dependent innate responses in a manner independent of a type III secreted OspG orthologue. *Microbiology*. **155**: 3214-3225.
- Ogawa M, Shimizu K, Nomoto K, Takahashi M, Watanuki M, Tanaka R, Tanaka T, Hamabata T, Yamasaki S and Takeda Y (2001). Protective effect of *Lactobacillus casei* strain Shirota on shiga toxin-producing *Escherichia coli* O157:H7 infection in infant rabbits. *Infect. Immun.*, **69**: 1101-8.
- Qadri F, Svennerholm A-M, Faruque ASG and Sack RB (2005). Enterotoxigenic *Escherichia coli* in developing countries: epidemiology, microbiology, clinical features, treatment, and prevention. *Clin. Microbiol. Rev.*, **18**: 465-83.
- Rafiq S, Ahmad S, Ahmed F, Batool Z, Ahmed SB, Saleem S, Naqvi F, Liaquat L, Afzal A and Haider S (2018). Anticholinergic drug atropine diminishes newly formed fear memory in male rats. *Pak. J. Pharm. Sci.*, **31**(3(Suppl.)): 1075-1079.
- Saravia M, Segovia C, Valderrama K and Santander J (2017). Colibacillosis in a New Zealand white rabbit (*Oryctolagus cuniculus*). *J. Infect. Dev. Ctries.* **11**: 203-206.
- Sharma C, Singh BP, Thakur N, Gulati S, Gupta S, Mishra SK and Panwar H (2017). Antibacterial effects of *Lactobacillus* isolates of curd and human milk origin against food-borne and human pathogens. *3 Biotech.* **7**: 31.
- Sharma R, Kapila R, Dass G and Kapila S (2014). Improvement in Th1/Th2 immune homeostasis, antioxidative status and resistance to pathogenic *E. coli* on consumption of probiotic *Lactobacillus rhamnosus* fermented milk in aging mice. *Age (Dordr)*, **36**: 9686.
- Tzang BS, Liu CH, Hsu KC, Chen YH, Huang CY and Hsu TC (2017). Effects of oral *Lactobacillus* administration on antioxidant activities and CD4+ CD25+ forkhead box P3 (FoxP3)+ T cells in NZB/W F1 mice. *Br. J. Nutr.* **118**: 333-342.
- Yang M, J Wang, C Chen, Y Ma, S He and Wang C (2017). The expression and significance of IL-6 and IL-10 in the process of clinical common bacteria bloodstream infection in the mouse models analyzed by the Luminex\_xMAPTM System. *Front. Lab. Med.* **1**: 55-58.
- Zahoor MA, Liebhart D and Hess M (2011). Progression of histomonosis in commercial chickens following experimental infection with *in vitro* propagated mono-eukaryotic *Histomonas meleagridis*. *Avian Dis.* **55**: 29-34.
- Zhao D, Wu T, Yi D, Wang L, Li P, Zhang J, Hou Y and Wu G (2017). Dietary Supplementation with *Lactobacillus casei* alleviates lipopolysaccharide-induced liver injury in a porcine model. *Int. J. Mol. Sci.*, **18**: 2535.