

# The value of erythromycin pleurodesis in treatment of spontaneous pneumothorax

Zhenjie Sun<sup>1</sup>, Xia Gao<sup>2</sup>, Qinghua Meng<sup>3</sup>, Naihua Ma<sup>4</sup>, Kai Han<sup>1</sup> and Gang Du<sup>5\*</sup>

<sup>1</sup>Department of Critical Care Medicine, The Fourth People's Hospital of Zibo, Zibo, China

<sup>2</sup>The Department of Oncology, The Fourth People's Hospital of Zibo, Zibo, China

<sup>3</sup>Anesthesia Department, The Fourth People's Hospital of Zibo, Zibo, China

<sup>4</sup>The Medical Department of Neurology, The Fourth People's Hospital of Zibo, Zibo, China

<sup>5</sup>The Department of Emergency, People's Liberation Army Joint Service Support Unit 960 Hospital, Zibo, China

**Abstract:** The research was carried out to observe the effect of erythromycin pleural fixation in treatment of spontaneous pneumothorax. The 160 patients who had been treated for spontaneous pneumothorax were selected as research objects. They were treated with erythromycin pleural fixation. Statistics were made on the intraoperative blood loss, analgesic dosage, thoracic drainage volume and postoperative hospital stay of the patients. In addition, the overall treatment efficiency of the patients was calculated, and VAS score and SF-36 scale were used to observe the pain degree and quality of life of the patients. The overall treatment efficiency was 87.50% (140/160). Intraoperative blood loss was (106.18±19.03) mL, analgesic dosage was (145.90±20.16) mg, chest drainage was (205.27±34.23) mL and postoperative hospital stay was (4.7±1.2) days. The white blood cell count, neutrophil cell count and mononuclear cell count were recorded. The results showed there were no significant differences in these three indexes before and after the treatment,  $p>0.05$ . None of the patients had serious adverse reaction problems. Hence the conclusion was drawn that erythromycin pleurodesis can be used to treat spontaneous pneumothorax patients, and achieve good results.

**Keywords:** Erythromycin pleurodesis, spontaneous pneumothorax, pleural hardener, therapeutic effect, value.

## INTRODUCTION

Pleural cavity is a closed cavity between visceral and parietal pleura. Due to elastic retraction force in the lungs, it is a negative pressure cavity, with value of -0.29-0.49 kPa (-3.5 cm H<sub>2</sub>O) (Wang, 2015; Zhang *et al.*, 2015). If there is an inducement that leads to rapid elevation of pressure in the alveolar, pulmonary rupture of the diseased lung, pleura will be caused (Gao *et al.*, 2017; Hashem *et al.*, 2016). Pleural cavity is connected to the atmosphere, and air flows into the chest cavity, resulting in spontaneous pneumothorax. In general, spontaneous pneumothorax is secondary, including closed (simple) pneumothorax, traffic (open) pneumothorax, tension (high-pressure) pneumothorax, etc. (Hong and Huang, 2015; Cai and Zhao, 2016). Spontaneous pneumothorax is very difficult to be healed, while recurrent pneumothorax and limited pneumothorax are more common, and simple closed pneumothorax is relatively less (Xu *et al.*, 2018; Yildiz *et al.*, 2017).

For spontaneous pneumothorax (fig. 1), conservative treatment or exhaust therapy is usually used. Meanwhile, for patients with closed thoracic drainage or recurrent pneumothorax, pleural fixation (fig. 2) is applied. The usual pleural hardener was tetracycline, which has been discontinued due to major side effects (Iwata *et al.*, 2016). In subsequent development, the application of talc as a

pleural hardener was controversial due to side effects as well. Therefore, adoption of new, safe and effective sclerosing agent is of critical significance to the treatment of recurrent and refractory pneumothorax (Alnaim and Almaz, 2017; Cansu *et al.*, 2017). In 1995, Carvalho *et al.* observed through animal models that injection of lactated erythromycin into chest cavity resulted in an inflammatory response to pleural adhesion, so lactoerythromycin is generally recognized as an effective chest hardener. This study observes and analyzes the therapeutic value of erythromycin pleurodesis for spontaneous pneumothorax, with the purpose of providing valuable reference for clinical treatment.

## MATERIALS AND METHODS

### General data

The 160 patients who had been diagnosed as spontaneous pneumothorax and treated from January 2016 to August 2018 were selected as research objects. The imaging examination diagram of 1 patient is shown in fig. 3. All the patients were clearly diagnosed by clinical examination with typical clinical manifestations, such as dyspnea, irritant cough, chest pain, palpitation, etc. All patients in this study had the right to know and signed the informed consent. This study was approved by the hospital ethics committee. Of the 160 patients, 90 were male and 70 were female, with age ranging from 20 to 78 years, averaging at (45.2 ± 0.9) years old.

\*Corresponding author: e-mail: 382800539@qq.com

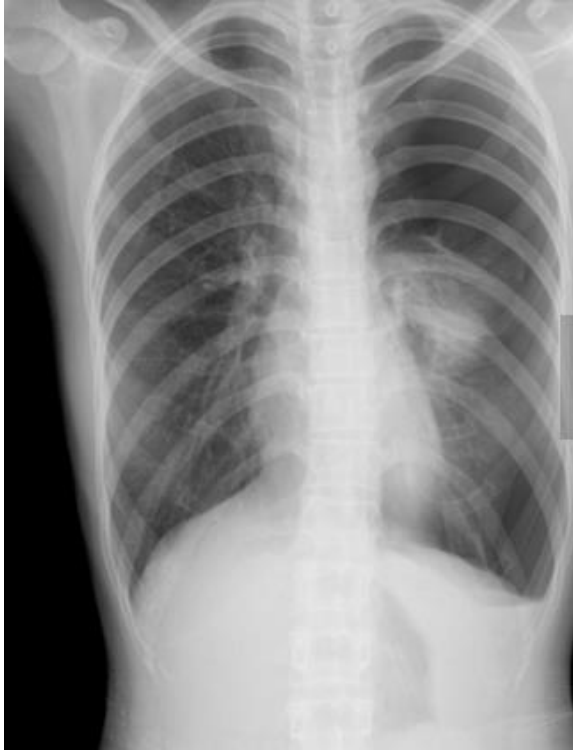

Fig. 1: Spontaneous pneumothorax

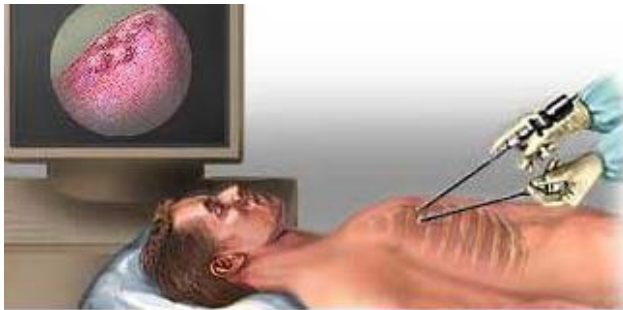

Fig. 2: Pleurodesis

### Method

All the patients in this study were treated with erythromycin pleural fixation, and rigorous blood routine examinations were performed before and after pleural fixation. The patients were treated with an intercostal intubation with closed drainage, and a rigorous erythromycin pleural fixation was performed. Lactate erythromycin (1 g) was dissolved in water for injection (4 mL), followed by addition of 50 mL of saline before mixing fully. 20 mL of 2% lidocaine was added into normal saline, resulting the lidocaine solution to be injected into pleural cavity via drainage tube. The patient was guided to spin 360° at recumbent position, and the pleural surface was anesthetized. Five minutes later, the solution of erythromycin was slowly injected into the pleural cavity through the thoracic drainage tube. The patient was allowed to change position in multiple directions, so that liquid medicine spread evenly on the

pleural surface. After that, we connected the drainage tube and checked whether there was gas discharge in the water seal bottle. In case of gas discharge, drainage tube was closed for 2h and connected to the water seal bottle drainage after fully exhausting the gas (Lee *et al.*, 2018). After surgery, routine treatment was applied. Patients in this study were given follow-up examination of six months to a year.

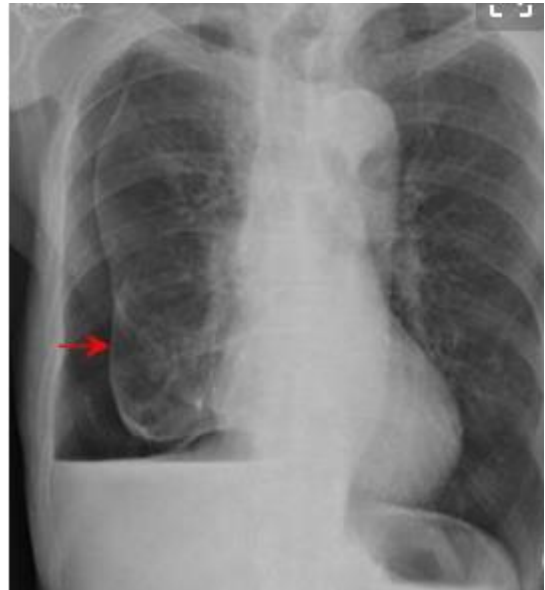

Fig. 3: Spontaneous pneumothorax imaging figure

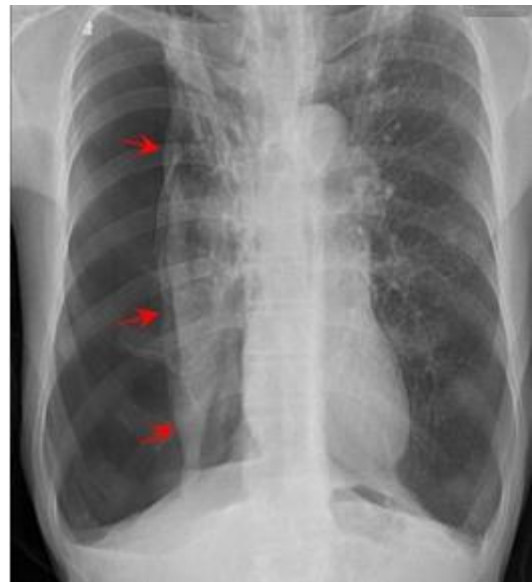
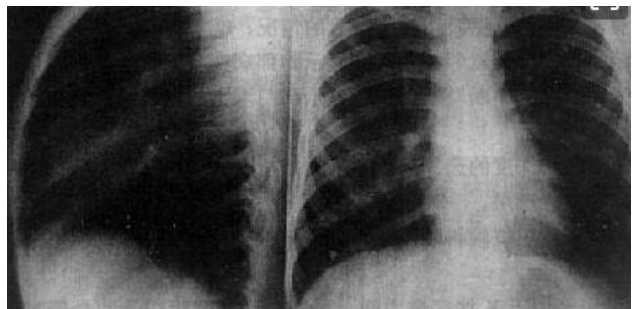


Fig. 4: Spontaneous pneumothorax before treatment

### Observational index

Indices such as intraoperative blood loss, analgesic dosage, thoracic duct drainage and postoperative hospital stay were recorded and analyzed. The white blood cell count, neutrophils cell count and monocyte cell count were recorded. The overall treatment efficiency of the patients includes three criteria: significant effective,

effective and ineffective. VAS and SF-36 scale were used to observe the pain degree and quality of life of the patients. For VAS evaluative criteria: 0 point represents no pain; 1-3 point represents slight pain; 4-6 point represents significant pain and affected sleep; 7-10 point represents intense pain. SF-36 evaluative criteria were divided into 8 dimensions: physiological function (PF), role physical (RP), body pain (BP), general health knowledge (GH), vigor (VT), social function (SF), role emotional (RE), and mental health (MH). The higher the score is, the more the patient is healthy.



**Fig. 5:** The thoracic lateral projection and posterior anterior projection after treatment

## STATISTICAL ANALYSIS

Statistical analysis software SPSS21.0 was used to process data. The measurement data were expressed by mean  $\pm$  average ( $x \pm s$ ), with t test conducted for intergroup comparison. Enumeration data were expressed by natural (n) and percentage (%), with  $\chi^2$  used for intergroup comparison. The intergroup difference is of statistical value when  $p < 0.05$ .

## RESULTS

Table 1 shows the leukocyte count, neutrophil count and monocyte count before and after treatment. It can be seen that there were no significant differences in such three indices before and after treatment,  $p > 0.05$ .

As shown in table 2, the intraoperative blood loss was ( $106.18 \pm 19.03$ ) mL, analgesic dosage was ( $145.90 \pm 20.16$ ) mg, chest drainage was ( $205.27 \pm 34.23$ ) mL, postoperative hospital stay was ( $4.7 \pm 1.2$ ) d, and the overall effective rate was 87.50% (140/160). The images of the patients before and after treatment are shown in figs. 4 and 5. As shown in table 3, the improvement of SF-36 score was significant after treatment,  $p < 0.05$ . The VAS score was lower after operation.

## DISCUSSION

Spontaneous pneumothorax refers to the rupture of lung tissue and visceral pleura due to pulmonary diseases, or spontaneous rupture of pneumobula and subtle pneumosis near the surface of the lung, causing air in the lungs and

bronchi to escape into the pleural cavity. Spontaneous pneumothorax is more common in young men or those with chronic bronchitis, emphysema and tuberculosis. This disease is one of the pulmonary emergencies, which can endanger life or can be cured with timely treatment (Li and Li, 2017).

Since the 1990s, erythromycin has been widely used as a pleural hardener and has been effective. Erythromycin is a common and relatively inexpensive antibiotic, and its injection preparation is lactose acid salt, which has a high stimulation. Some scholars showed that the same pleural adhesion effect as tetracycline could be achieved by injecting erythromycin into the pleural cavity of New Zealand white rabbits (Cantey *et al.*, 2017). The mechanism of pleural adhesion induced by erythromycin is significantly associated with its production of pleural chemical inflammation. As revealed by animal experiment (Badal *et al.*, 2016), when erythromycin was injected into the pleural cavity, the white blood cell count in pleural effusion increased significantly, inflammatory reaction occurred to the pleural surface, and the fibroblast phenomenon was significantly increased.

For pneumothorax patients, after the gas is exhausted, a relatively high concentration of erythromycin is injected into the pleural cavity and applied on the pleural surface, so that a stronger stimulus effect is realized, which causes the visceral parietal pleura to become chemically inflamed and adhere to each other. In addition, after the patient received erythromycin, chest pain and pleural effusion were formed, and the amount of effusion was about 100 mL, the white blood cell count in the effusion was above  $5000 \times 10^6/L$ , the protein content was above 30g/L, the pleural LDH/ blood LDH was above 0.6, the LDH value significantly increased, and the white blood cell count, LDH and protein content increased with time. This indicates that the drainage liquid was inflammatory effusion.

In this study, white blood cell count, neutrophil cell count and mononuclear cell count in patients' blood routine did not change significantly before and after adhesion, and no serious adverse reaction problems were found in patients. This indicates that erythromycin as an adhesive mainly causes inflammatory reactions in the pleura, and does not make a significant effect on the organism. This result is consistent with results of relevant studies (Markovska *et al.*, 2017).

## CONCLUSION

A conclusion has been reached that using erythromycin pleurodesis for treating spontaneous pneumothorax can achieve good therapeutic effect. A relevant study shows that approximately 70% of patients with pneumothorax are likely to have recurrence on the same side or continue

**Table 1:** Leukocyte count, neutrophil count and monocyte count before and after treatment ( $\bar{x} \pm s$ )

Time	Leukocyte count ( $\times 10^9/L$ )	Neutrophil count ( $\times 10^9/L$ )	Monocyte count ( $\times 10^9/L$ )
Before treatment	6.20 $\pm$ 1.29	3.68 $\pm$ 0.83	0.32 $\pm$ 0.06
After treatment	6.22 $\pm$ 1.56	3.79 $\pm$ 0.92	0.34 $\pm$ 0.08
t	0.29	0.16	0.20
p	> 0.05	> 0.05	> 0.05

**Table 2:** Statistics of various treatment indexes

Index	Number of case	Evaluation result
Intraoperative blood loss (mL)	160	106.18 $\pm$ 19.03
Analgesic dosage (mg)	160	145.90 $\pm$ 20.16
Chest drainage (mL)	160	205.27 $\pm$ 34.23
Postoperative hospital stay (d)	160	4.7 $\pm$ 1.2
Overall effective rate (%)	160	87.50% (140/160)

**Table 3:** Comparison of VAS score and SF-36 score before and after treatment ( $\bar{x} \pm s$ )

Time	Postoperative VAS score	SF-36 score							
		PF	RP	BP	GH	VT	SF	RE	MH
Before treatment	-	43.20 $\pm$ 3.10	25.79 $\pm$ 3.25	29.03 $\pm$ 5.02	36.94 $\pm$ 4.24	40.11 $\pm$ 2.93	40.63 $\pm$ 3.72	80.28 $\pm$ 10.29	29.02 $\pm$ 1.26
After treatment	2.01 $\pm$ 1.03	56.80 $\pm$ 3.28	43.69 $\pm$ 3.47	60.78 $\pm$ 4.26	50.48 $\pm$ 2.93	57.93 $\pm$ 3.25	60.28 $\pm$ 5.24	90.26 $\pm$ 2.18	42.18 $\pm$ 4.52
t	-	9.03	12.49	9.35	11.26	15.33	11.03	8.42	10.38
P	-	<0.05	<0.05	<0.05	<0.05	<0.05	<0.05	<0.05	<0.05

with closed drainage within two years, resulting in repeated chest pain and shortness of breath. If there is already severe pulmonary dysfunction, it will have a greater impact on respiration and circulation. In severe cases, respiratory failure and shock can occur. Therefore, pleural fixation for the treatment of recurrent or refractory pneumothorax is also an important measure for the prevention and control of pneumothorax recurrence. After using erythromycin pleural fixation, the amount of intraoperative blood loss, analgesic dosage, thoracic drainage volume and the length of postoperative hospital stay can be significantly reduced, the overall effective rate can be improved and the adverse reaction problems can be reduced. As the sample data of this study is small, more large sample studies are needed to support the results.

## REFERENCES

Alnaim L and Almaz S (2017). A study of barriers and facilitators of clinical practice guidelines implementation among physicians. *Indian J. Pharm. Sci.*, **79**: 923-929.

Badal RE, Bouchillon SK and Lob SH (2016). Extended-spectrum  $\beta$ -lactamase rates and antimicrobial susceptibility of gram-negative bacilli causing intra-abdominal infections in patients in general pediatric and pediatric intensive care units - Global data from the study for monitoring antimicrobial resistance trends

2008 to 2010. *Pediatr Infect Dis J*, **32**(6): 636-40.

Cai CH and Zhao J (2016). Therapeutic effect of erythromycin pleurodesis in treatment of refractory pneumothorax. *Qinghai Med J*, **45**: 24-25.

Cansu GB, Taskiran B, Dizen H and Cengiz BP (2017). Parathyroid hormone in washout fluid seems to be superior to cytology for localization of the lesion in mibi-negative patients with primary hyperparathyroidism. *Turk. J. Med. Sci.*, **47**(6): 1703-1707.

Cantey JB, Sreeramoju P and Jaleel M (2017). Prompt control of an outbreak caused by extended-spectrum  $\beta$ -lactamase-producing *Klebsiella pneumoniae* in a neonatal intensive care unit. *Journal Pediatr*, **163**(3): 672-679.

Gao W, Baig AQ, Ali H, Sajjad W and Farahani MR (2017). Margin based ontology sparse vector learning algorithm and applied in biology science. *Saudi J. Biol. Sci.*, **24**(1): 132-138.

Hashem A, Abd Allah EF, Alqarawi AA and Egamberdieva D (2016). Bioremediation of adverse impact of cadmium toxicity on cassia italica mill by arbuscular mycorrhizal fungi. *Saudi J. Biol. Sci.*, **23**(1): 39-47.

Hong B and Huang LH (2015). Observation of curative effect of thoracoscopic erythromycin dry powder pleural fixation in treatment of refractory spontaneous pneumothorax. *Chongqing Med*, **14**: 1964-1966.

Iwata H, Masuda N and Ohno S (2016). A randomized, double-blind, controlled study of exemestane versus anastrozole for the first-line treatment of

- postmenopausal Japanese women with hormone-receptor-positive advanced breast cancer. *Breast Cancer Res. Tr.*, **139**(2): 441-451
- Lee DS, Kim SH and Kim S (2018). Prognostic significance of breast cancer subtype and p53 over expression in patients with locally advanced or high-risk breast cancer treated using upfront modified radical mastectomy with or without post-mastectomy radiation therapy. *Int. J. Clin. Oncol.*, **15**: 447-455.
- Li QS and Li HL (2017). Observation of therapeutic effect of tail catheter drainage combined with chest perfusion in treatment of chronic obstructive pulmonary disease combined with refractory pneumothorax. *J Huaihai Med*, **36**: 73-75.
- Markovska RD, Stoeva TJ and Bojkova KD (2017). Epidemiology and molecular characterization of extended-spectrum beta-lactamase-producing enterobacter spp., *Pantoea agglomerans* and *Serratia marcescens* isolates from a Bulgarian hospital. *Microb Drug Resist: MDR: Mech Epidem Dis*, **20**(2): 131-137.
- Wang W (2015). Effects of different pleural fixation on postoperative pain and quality of life after pulmonary bullous resection. *China Health Ind*, **28**: 138-139.
- Xu K, He G, Qin J, Cheng X, He H, Zhang D and Peng W (2018). High-efficient extraction of principal medicinal components from fresh phellodendron bark (*Cortex phellodendri*). *Saudi J. Biol. Sci.*, **25**(4): 811-815.
- Yildiz Y, Kucukzeybek Y, Alacacioglu A, Taskaynatan H, Yildiz I, Varol U, Demir L, Akyol M, Salman T, Oflazoglu U, Kalkan T and Tarhan MO (2017). Serum levels of omentin-1 in patients with advanced epithelial ovarian cancer: the izmir oncology group (izog) study. *Acta Med Mediterr*, **33**: 549-555.
- Zhang P, Tan ZM and Wang Z (2015). Clinical value of video-assisted thoracoscopic pleural fixation in treatment of malignant pleural effusion. *Med. J. West China*, **27**: 420-422.