

# Efficacy of calcium hydroxide and chlorhexidine in pulp revascularization after trauma in young permanent teeth

Jingjing Zhang<sup>1</sup>, Weican Chen<sup>2</sup>, Xuena Xi<sup>3</sup>, Guoliang Han<sup>3</sup> and Lin Liu<sup>3\*</sup>

<sup>1</sup>Department of Stomatology, Hebei Provincial Eye Hospital, Xingtai, China

<sup>2</sup>Department of No. 1 Stomatology, Baoding No.1 Central Hospital, Baoding, China

<sup>3</sup>Department of Stomatology, Harrison International Peace Hospital, Hengshui, China

**Abstract:** The objective of this study is to observe and analyze the efficacy of calcium hydroxide and chlorhexidine in pulp revascularization after trauma in young permanent teeth. A total of 120 patients who were treated in our hospital for pulp revascularization after trauma in young permanent teeth were enrolled as research objects in the study. The patients were treated with calcium hydroxide and chlorhexidine and the overall treatment efficiency was statistically observed. The improvement in various indicators before and after treatment was observed, including pain symptom score, gum swelling symptom score, tooth looseness score. The overall treatment efficiency was recorded. The results showed that there were 70 cases of significant effective treatment, 42 cases of effective treatment, and 8 cases of ineffective treatment, respectively, with overall treatment efficiency of 93.33%. Compared with the pain score, gum swelling score and teeth looseness score before treatment, these indicators showed a significant improvement after treatment,  $p < 0.05$ . The application of calcium hydroxide and chlorhexidine during pulp revascularization after trauma in young permanent teeth can significantly improve the therapeutic effect and achieve higher therapeutic efficiency, demonstrating huge application value.

**Keywords:** Calcium hydroxide, chlorhexidine, pulp revascularization after trauma in young permanent teeth, efficacy.

## INTRODUCTION

There are different opinions on whether to use antibacterial triple paste as root canal drug or calcium hydroxide as root canal drug in the current study of pulp revascularization (Zhou *et al.*, 2018; Yang, 2015). The pulp necrosis caused by changes in periodontal ligaments and papillary cells after trauma in young permanent teeth is different from carious pulp necrosis (Pan, 2017; Xue, 2015). The periodontal ligament in the young permanent teeth and undifferentiated stem cells in the dental papilla are of critical significance for pulp revascularization. In this study, the efficacy of calcium hydroxide and chlorhexidine in pulp revascularization after trauma in young permanent teeth was analyzed.

## MATERIALS AND METHODS

A total of 120 patients who were treated in our hospital from June 2015 to December 2018 for pulp revascularization after trauma in young permanent teeth were enrolled as research objects in the study. The inclusion criteria include those aged over 8 years and below 12 years old; those with alveolar bone fractures and partial dislocation of the teeth due to trauma in maxillary and mandibular anterior teeth; those with cheek swelling symptoms, gingival redness, swelling and pain symptoms, as well as fistulas; those with occlusal pain and spontaneous pain symptoms after trauma. The exclusion

criteria include those with significant organ function defects; those with systemic comorbidities. Those with drug allergy. For all selected 120 patients, 65 were male and 55 were female. The age was between 8 and 12 years old, and the mean age was recorded as  $(9.01 \pm 2.14)$  years. Patients and their families had the right to know, signed the informed consent form for this study. This study was approved by the Hospital Ethics Association.

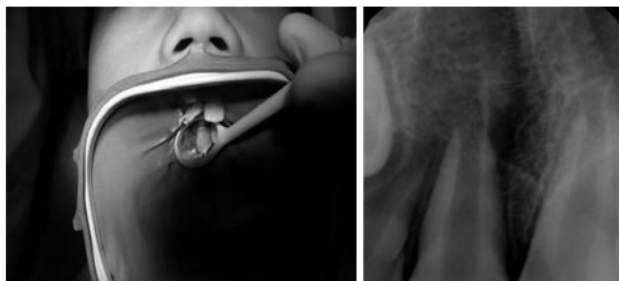*All patients were treated with calcium hydroxide and chlorhexidine. The main contents are as follows*

Lidocaine (2%) was used to perform nerve block anesthesia. The maxillary anterior teeth underwent infraorbital foramen nerve block anesthesia and the mandibular anterior teeth underwent inferior alveolar nerve block anesthesia. Afterwards, the pulp was opened using rubber dam. After the access to the root canal was opened, grasp the pulp state, probe the root canal using No. 25 K file, detect and record the depth of the retained vital pulp in the root canal using root apex locator. Then, perform multiple alternating douche of root canal using sodium chloride solution (0.9%) and sodium hypochlorite solution (2.50%-5.25%). Implement extirpation of pulp, root canal preparatory treatment, followed by root canal drying using sterilized absorbent points.

Calcium hydroxide and chlorhexidine gel (2%) were mixed into a paste with a ratio of 1:1. Slowly feed it in the root canal through the auger conveyor, determine depth of the drug delivery according to the depth measured by the root apex locator. The depth measured by the root apex

\*Corresponding author: e-mail: wanjia31@163.com

locator is preferably controlled within 3 mm. Afterwards, the cavity was sealed using sterile cotton pellet and temporary sealing material.



**Fig. 1:** Preoperative X-ray images of pulp revascularization



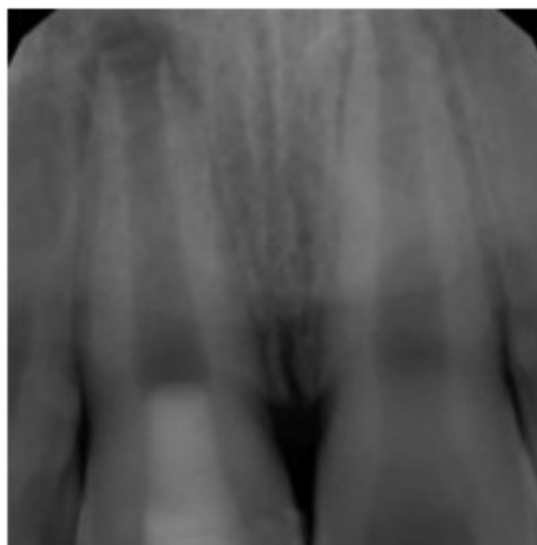
**Fig. 2:** 18 months after pulp revascularization

The patient will be followed up after 21 days. If the offending tooth has symptoms including percussion pain, pain, fistula, redness and swelling of the gum, repeat the above treatment. If the clinical symptoms disappear and no massive inflammatory exudate is produced in the root canal, thoroughly rinse the root canal, apply sodium hypochlorite solution (2.50%-5.25%) and wash the root canal wall for 3 minutes using 3mL of disodium edetate dihydrate (17%). Finally, rinse the disodium edetate dihydrate in the root canal using sodium chloride solution (0.9%), dry the root canal with sterilized absorbent points. Lightly puncture the apical pulp and tissue with a disinfected large root canal file to make it bleed. When the blood was filled to about 2 mm below the cemento-enamel junction, root canal closure was performed after the blood clot was generated, and the crown was repaired using light cured composite resin.

#### **Observation indicators**

The overall treatment efficiency was recorded, including significantly effective, effective and ineffective. Significant effectiveness is defined upon no complains of o pain, disappearance of the tooth percussion pain, the degree of looseness is I°, no gum swelling or fistula, increased root length, thickened wall, narrowed lumen

and apical gathering in X-ray examination (Stephanie, 2015; Pontoh *et al.*, 2016). Effectiveness is defined upon disappearing of pulp necrosis after treatment, no abnormalities in clinical examinations, and no obvious signs of continued development of the tooth root in X-ray examination. Ineffectiveness is defined upon no improvement after three root canal irrigation and root dressing, percussion pain with looseness II° swollen fistula. periapical lesions and no continued development of the roots. In addition, statistics was made for pain symptoms, gum swelling symptoms, degree of tooth looseness before and after treatment and post-treatment recovery was observed. 0-10 points are given for each symptom. Only the pain symptoms are assessed by the patient according to their own feelings. The gum swelling and tooth looseness are evaluated by the medical staff according to the review results. A higher score suggests more serious symptoms (Cheng *et al.*, 2016; Zhao *et al.*, 2017).



**Fig. 3:** X-ray film at 18 months after the surgery

#### **STATISTICAL ANALYSIS**

The statistical analysis software SPSS 21.0 was adopted for data analysis. Measurement data were expressed as mean  $\pm$  standard deviation ( $\bar{x} \pm s$ ), with t-test used for inter-group comparison; count data were expressed using natural numbers (n) and percentages (%), with Chi-square used for comparison. The difference was considered statistically significant when  $p < 0.05$ .

#### **RESULTS**

##### **Overall treatment efficiency**

As shown in table 1, the overall treatment efficiency of the patients is 93.33%. After 6 months of treatment, the patients were found to have no abnormal clinical manifestations and the crown color was normal. X-ray

**Table 1:** Statistics of overall treatment efficiency [n (%)]

Number of cases	Significantly effective	Effective	Ineffective	Total efficiency (%)
120	70	42	8	112(93.33)

**Table 2:** Comparison of symptom scores before and after treatment ( $\bar{x} \pm s$ )

Time	Pain score	Gum swelling score	Tooth looseness score
Before treatment	6.70±2.14	7.88±1.90	7.98±0.83
After treatment	2.35±1.02	3.02±1.36	0.80±0.31
t	8.03	12.37	15.21
p	<0.05	<0.05	<0.05

examination showed that periapical ghost was normal and the roots had no significant development. There was no abnormal clinical manifestation at 12 months and 18 months after treatment. The crown color was normal, the root length was increased, the root canal wall was thickened, and the lumen was reduced, as shown in fig. 2 and fig. 3. As shown in table 2, improvement of the symptom scores is more significant after treatment,  $p < 0.05$ .

## DISCUSSION

Dental trauma, especially crown fracture, looseness, displacement and dislocation of the anterior teeth, can cause damage to the periodontal ligament and the nerve vessel bundle of the teeth. A common complication after dental trauma is pulpal vascular nerve necrosis, which is more common after trauma in young permanent teeth (Liu *et al.*, 2016). The ligaments and dental papilla cells around the apical foramen will be affected after the young permanent teeth are injured, which then affects further roots development to a certain extent (Zhang *et al.*, 2017). In the past, the treatment for pulp necrosis was mainly apexification represented by root canal drug therapy, or apical closure represented by root-end filling with trioxide polymer (MTA). The current research on pulp revascularization studies new treatment mode for pulp necrosis after trauma in young permanent teeth, which can promote the further development of roots.

The incidence of adolescent dental trauma is clinically high. Pulp revascularization has gradually become one of the new measures for clinical treatment of young permanent teeth trauma. This treatment can promote continued development of the root tip, increase dentinal tubules in the apical part and reduce the occurrence of root fracture (Mansour and Vahid, 2016; Pontoh *et al.*, 2016; McCann *et al.*, 2016). In this study, calcium hydroxide and chlorhexidine gel were applied in pulp revascularization after trauma in young permanent teeth. The calcium hydroxide and 2% chlorhexidine gel were co-used as root canal disinfection and sterilization drug, which achieved ideal clinical treatment effect. Where,

chlorhexidine can remove the antibacterial peptide remaining in the dentinal tubule.

The statistical results showed that there were 70 cases of significant effectiveness, 42 cases of effectiveness and 8 cases of ineffectiveness, respectively, with the overall treatment efficiency reaching 93.33%. Compared with the pain score, gum swelling score and tooth looseness score before treatment, the several indicators showed significant improvement after treatment,  $p < 0.05$ . This indicates that the combined application of calcium hydroxide and chlorhexidine can achieve an ideal result in pulp revascularization after trauma in young permanent teeth.

## CONCLUSION

In this study, the calcium hydroxide and chlorhexidine gel were co-used as intracanal disinfection and sterilization drug, which demonstrated satisfactory effect in pulp revascularization caused by pulp necrosis after young permanent teeth trauma. Moreover, no crown discoloration occurred in the existing successful cases. Considering the effect of strong alkalinity of calcium hydroxide on root tip stem cells, the sealing depth should be 3mm shorter than the actual working length measured by the root apex locator when intracanal medicament is used. In order to prevent periapical dental papillary stem cells from being damaged by sodium hypochlorite, sterile saline washing was adopted to reduce the damage of chemical flushing liquid to the residual stem cells in the root tip. The combined application of calcium hydroxide and chlorhexidine is effective in pulp revascularization after trauma in young permanent teeth, which is worthy of being popularized clinically.

## REFERENCES

- Cheng L, Liu QM and Wang J (2016). Clinical application of pulp revascularization in the treatment of trauma-induced pulp necrosis in young permanent teeth. *Chinese Remedies & Clinics*, **16**(9): 1345-1347.
- Liu CL, Liu F and Guo QY (2016). Bibliometric analysis of Chinese research results on young permanent teeth

- trauma. *Oral Medicine*, **36**(10): 938-941.
- Mansour F and Vahid V (2016). Effect of liquid nano material and hydrated lime in improving the moisture behaviour of HMA. *Transportation Research Procedia*, **17**(21): 34-39.
- McCann M, Fitzpatrick F, Mellotte G and Clarke M (2016). Is 2% chlorhexidine gluconate in 70% isopropyl alcohol more effective at preventing central venous catheter-related infections than routinely used chlorhexidine gluconate solutions: A pilot multicenter randomized trial. *AJIC*, **44**(8): 123-126.
- Pan XM (2017). Therapeutic effect of different irrigation and disinfection drugs on periodontal pulp combined lesions in root canal therapy. *Chinese Journal of Pharmaceutical Economics*, **12**(11): 69-71.
- Pontoh LA, Gatam R and Suryo T (2016). Rotational comparison between double bundle ACL reconstruction and single bundle ACL reconstruction combine with antero lateral ligament (ALL) reconstruction. *Asia-Pacific Journal of Sports Medicine, Arthroscopy, Rehabilitation and Technology*, **6**(18): 69-75.
- Pontoh LA, Gatam R and Suryo T (2016). Rotational comparison between double bundle ACL reconstruction and single bundle ACL reconstruction combine with antero lateral ligament (ALL) reconstruction. *Asia-Pacific Journal of Sports Medicine, Arthroscopy, Rehabilitation and Technology*, **6**(29): 324-328.
- Stephanie C (2015). Cancer Center's Experience Converting from Chlorhexidine Gluconate Impregnated Wipes to Chlorhexidine Gluconate Shower on Inpatient Blood & Marrow Transplant Unit. *AJIC*, **43**(6): 120-125.
- Xue Y (2015). Analysis of *in vitro* antibacterial activity of chlorhexidine and calcium hydroxide on *Enterococcus faecalis*. *Modern Medicine Journal of China*, **17**(10): 85-87.
- Yang BB (2015). Clinical efficacy of ornidazole and calcium hydroxide combined with chlorhexidine in intracanal medicament. *China Medical Herald*, **18**: 146-148, 157.
- Zhang DD, Fang LX and Yu JJ (2017). Clinical efficacy and satisfaction of autologous crown rejoining in the treatment of young permanent teeth trauma. *Chinese Journal of Aesthetic Medicine*, **20**(12): 90-93.
- Zhao NN, Peng H and Cai J (2017). Clinical application of pulp revascularization in the treatment of trauma-induced pulp necrosis in young permanent teeth. *Medical Innovation of China*, **14**(10): 104-107.
- Zhou Y, Wu J and Cheng J (2018). The efficacy of calcium hydroxide and chlorhexidine in pulp revascularization after trauma in young permanent teeth. *Anhui Medical Journal*, **39**(1): 57- 59.