

# Evaluation of anti-inflammatory and wound healing potential of tannins isolated from leaf callus cultures of *Achyranthes aspera* and *Ocimum basilicum*

Madieha Ambreen and Safdar Ali Mirza

Botany Department, Government College University, Lahore, Pakistan

**Abstract:** Herbal medicines are important in treatment of inflammation as they are safe and nontoxic. Tannins are important bioactive compounds used as anti-inflammatory agents and possess wound healing potential. Anti-inflammatory activity of tannins extracted from seedling leaf tissue and callus culture extracts of *Achyranthes aspera* L. and *Ocimum basilicum* L. were determined using Carrageenan induced paw edema model. Wound healing potential of tannins from callus cultures of leaf explants of both plants were evaluated using four models in rabbits i.e. excision, incision, dead space and burn wound. Group I acted as control, Group II treated with Povidone iodine as standard drug. Groups III and IV were experimental groups treated with creams which consisted of tannins of callus cultures of leaf; cream A (*A. aspera*) and cream O (*O. basilicum*). The results of anti-inflammatory activity of callus cultures of leaf explants were comparable with standard drug Indomethacin. Seedling leaf tissue and callus culture extracts of *A. aspera* and *O. basilicum* plant showed decrease in paw edema thickness, size and maximum percentage inhibition of paw edema respectively. Among four wound models burn wound showed the best wound contraction by Cream O. Hydroxyproline content and tensile strength of dead space and incision wounds exhibited good result also respectively. Cream O exhibited best results as compared to cream A. Histopathological examination showed that cream O showed faster rate of fibroblast and collagen formation as compared to cream A. The results showed that condensed tannins of callus cultures of leaf of *A. aspera* exhibited the best anti-inflammatory activity while tannins from callus cultures *O. basilicum* showed the best results for wound healing. These findings may enable use of both plants for formulation of new phytomedicine.

**Keywords:** *Achyranthes Aspera*, *Ocimum basilicum*, tannins, inflammation, wound healing

## INTRODUCTION

Inflammation is common phenomenon after any kind of injury to living tissue characterized by swelling, redness and pain (Burke *et al.*, 2005). Steroidal and non-steroidal drugs are used as anti-inflammatory agents modulated to reduce the inflammation despite they have side effect (Mukherjee and Houghton, 2009). Studies show that 6 million peoples are affected from wounds worldwide. The development of pharmacological medicine for wound healing is not satisfactory due to low availability, high cost and many side effects (Kumar *et al.*, 2007). Therefore medicinal plants can be used as alternative approach, because of effectiveness, low cost and reliability (WHO, 2002). According to WHO, 70 to 80% population of world depends on plant-based medicines (Vines, 2004).

Research on wound healing is one of the most important areas in modern biomedical sciences. The study on wound healing agents is a challenge in medicine because the process involved in repair of damaged tissue is not completely understood (Singer and Clark, 1999; De Fatima *et al.*, 2008).

Plants produce large variety of secondary metabolites which are used as source of medicine for various

\*Corresponding author: e-mail: madiha.ambreen@yahoo.com

ailments. Tannins are one of the most important polyphenolic components found in leaves, roots and fruits. The selected plants *Achyranthes aspera* of family Amaranthaceae and *Ocimum basilicum* of Lamiaceae possess tannins. Binding of tannins with the proteins in injured membrane, coagulates them (Fernandez *et al.*, 2002) and forms protective layer (Neto *et al.*, 1996), thus separating injured area from the outer part and decrease the permeability of membrane at wound site (Brown and Dattner, 1998; Bedi 2002) leading to acceleration of wound repair. Tannins increase vasoconstriction and decrease vascular permeability in wound and function as anti-inflammatory agents (Kapu *et al.*, 2001; Lopes *et al.*, 2005) Tannins accelerate contraction of wound (Favaretto *et al.*, 1985) and increase formation of epidermis, helping in re-epithelialization process (Palermo *et al.*, 2002; Lopes *et al.*, 2005). This process includes multiplication and migration of cells from wound site and is integrated by process involving growth factors, genes, integural and extracellular matrix proteins (Santoro and Gaudino, 2005).

Advancement in plant tissue culture act as commercial processing of rare, endangered plants and the chemicals they provide. *In vitro* culture is powerful tool for conservation of endangered and threatened species. Cell and callus cultures play a special role in production of

medicinal and phytochemical compounds from plants. Therefore present study was planned to optimize culture conditions for *in vitro* callus production as an essential alternative for biomass production for extraction of medicinal compounds.

## MATERIALS AND METHODS

### *In vitro* seed germination and callus induction

*In vitro* seed germination of *O. basilicum* and *A. aspera* was carried out according to method described by Koné *et al.* (2015). Seeds were surface sterilized with 0.5% sodium hypochlorite solution containing a few drops of Tween<sup>20</sup> for 3 minutes and were thoroughly washed with sterile water and employed on cotton pads in glass jars for germination under standard conditions of temperature and light. Explants from *in vitro* grown seedlings were used for callus formation on MS medium with different combinations of growth regulators.

### Preparation of seedling tissue and callus culture extracts

Seedling tissues and callus masses obtained under different combinations of plant growth regulators were collected separately, wrapped in Whatman filter paper and oven dried at 40°C. Dried callus cultures were ground using pastel and mortar. One g powder of leaf callus cultures of both plants were extracted in 10 ml methanol Matthew *et al.* (2013) and their percentage yields were determined. Extracts were concentrated on rotary evaporator. Methanolic extracts of tannins from seedling leaf tissues and callus cultures of leaf explants of *A. aspera* and *O. basilicum* were concentrated by using rotatory evaporator and stored at 4°C in refrigerator.

### Anti-inflammatory activity

Anti-inflammatory potential of tannins from seedling leaf tissues and leaf callus cultures of both plants was evaluated according to procedure of Moosophon *et al.* (2010) by paw induced edema using prescribed dose of Carrageenan.

### Animal preparation

Healthy rabbits of either sex weighing 1.6 to 2.2 Kg with no prior drug treatment were used for monitoring anti-inflammatory activity. The animals were kept in clean environment under optimum conditions of temperature, light and humidity before testing. They were given ad libitum access to food and water.

### Ethical approval

The animals were procured after approval of Board of Studies and Advance Study Research Board of GCU Lahore. Experiments are conducted according to guidelines of laboratory use and care of animals.

### Treatments

Rabbits were divided into V1 groups for anti-inflammatory activity. Each group contained four animals.

Group I: Control

Group II: Treated with standard drug Indomethacin 10 mg/kg.

Group III: Treated with tannins from seedling leaf tissue extract of A (*A. aspera*) 300 mg/kg.

Group IV: Treated with tannins from callus extracts of leaf of A (*A. aspera*) 300 mg/kg.

Group V: Treated with tannins from seedling leaf tissue extract of O (*O. basilicum*) 300 mg/kg.

Group VI: Treated with tannins from callus extracts of leaf of O (*O. basilicum*) 300 mg/kg.

### Procedure

Methanolic concentrated extracts of leaf seedling tissues and callus culture of *A. aspera* and *O. basilicum* were dissolved in 0.9% normal saline solution. Plant extracts and standard drug were administered orally 30 min before Carrageenan injection. Carrageenan (1%) was prepared in normal saline. Injection of Carrageenan drug was inserted in sub-I anterior part of left paw. Reduction in paw size was determined with Vernier scale during 4 h and compared with standard drug and tannins from leaf seedling tissue and callus cultures extracts (methanol) of *A. aspera* and *O. basilicum*.

### Wound healing activity

#### Ointment formulation

Ointment was prepared by making homogenous mixture of each extract of callus culture 10% (w/w) in soft base paraffin separately.

#### Wound creation

Wound healing potential was investigated according to method of Dubay *et al.* (2016). One milli litre of IV injection of Ketamine hydrochloride (10 mg/kg body weight) was used to anaesthetized the rabbits before and during creation of wound (Mondal *et al.*, 2016). After anesthesia dose given to animals, hair were removed by hair removing cream at selected skin area and disinfected with spirit before wound induction. Four wound models' excision, incision, dead space and burn were used for determination of wound healing activity.

#### Excision wound

Wound was created on anterior dorsal surface of each rabbit by using sharp blade. Area of wound was measured by Vernier scale. Wound contraction was determined by following equation (Walker and Mason, 1968).

#### Incision wound

In this wound model, 1.5 to 2 cm diameter size of wound was formed from the midline on either side of vertebral column in cutaneous muscles aseptically. The wound was closed by using silk thread and needle No.11. The sutures were removed on 8<sup>th</sup> day and tensile strength was measured on 10<sup>th</sup> day.

**Dead space wound**

The dead space wound was prepared on either side of axilla after anesthesia. The hydroxyproline content was determined by (Woessner, 1961).

**Burn wound**

Burn wound was prepared using metal rod heated to 70 to 80°C for 15 s on dorsal side of rabbit (Bairy *et al.*, 2014). Wound contraction and epithelization time were determined.

**Treatments**

Rabbits were divided into IV groups for each wound model. Each group contained four animals.

*Group I:* Control.

*Group II:* Treated with standard drug Povidone iodine.

*Group III:* Treated with cream A (*A. aspera*) callus of leaf extract (10% w/w).

*Group IV:* Treated with cream O (*O. basilicum*) callus of leaf extract (10% w/w).

**Histopathological examination**

Animals were sacrificed after 12 days and wound biopsies were conducted for histopathological study. Tissues of wounds were fixed in 10% formalin buffer. After dehydration in alcohol, fixed in paraffin wax, 4-5 µm section was stained with hematoxylin and eosin for histopathological analyses. Fibroblast, collagen and re-epithelialization were evaluated through preparing wound slides (Vidinsky *et al.*, 2006).

**Measurements**

The appearance of each wound was analyzed by digital camera at 4x magnification and measurements were determined using Nikon’s Elements Imaging Software version 2.3.

**STATISTICAL ANALYSIS**

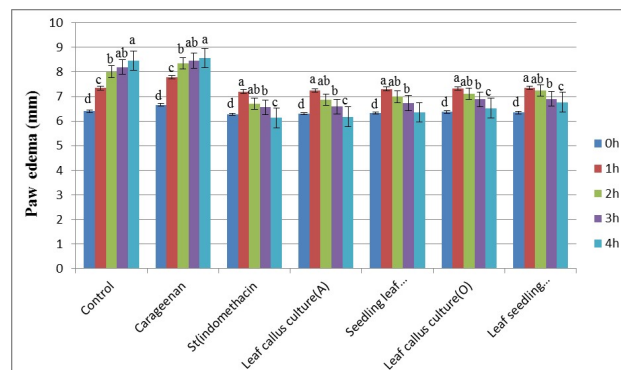
Data was expressed as mean ± SE at p ≤ 0.05 using Dunchen’s new multiple range test (SAS version 9.1 software program).

**RESULTS**

**Anti-inflammatory activity of seedling leaf tissue and callus culture extracts**

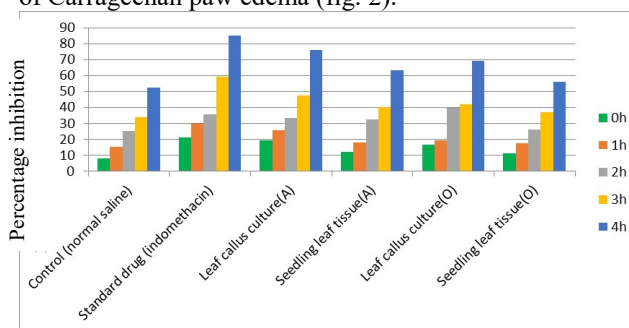
Among different callus cultures percentage yield of leaf callus culture extracts of *A. aspera* (MSDN) and *O. basilicum* (MSDK) was obtained as 22.5% and 24% respectively. Anti-inflammatory investigation of seedling leaf tissue and callus culture extracts evaluated by measuring reduction in paw edema size of rabbits showed 6.18±0.05 mm for *A. aspera* as compared to leaf callus culture of *O. basilicum* i.e. 6.53±0.08 mm and seedling leaf tissue extract of *O. basilicum* i.e. 6.77±0.09 mm.

Maximum reduction in paw edema recorded in case of leaf callus culture extract was comparable to anti-inflammatory activity of standard drug Indomethacin i.e. 6.13±0.07 mm (fig. 1).



**Fig. 1:** Reduction in paw edema (mm) by tannins from seedling leaf tissue and callus culture extracts of *A. aspera* and *O. basilicum*. All values with different letters are significantly different when P ≤ 0.05 using Duncan's new multiple range test using the SAS version 9.1 software program. (st =Standard drug, A= *A. aspera*, O= *O. basilicum*)

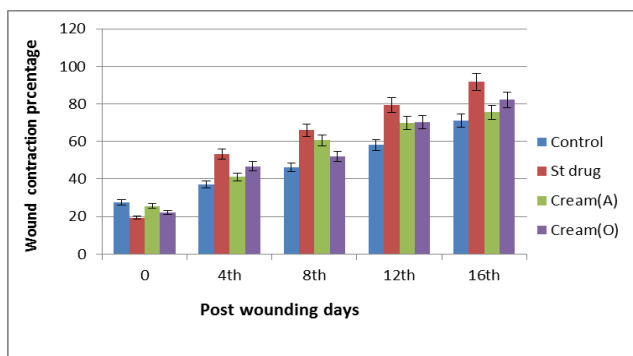
Among seedling leaf tissue and callus culture extracts of *A.aspera* and *O.basilicum*, maximum percentage edema inhibition was exhibited by the methanol extract of leaf callus culture of *A. aspera* i.e. 19.33% in 1h after extract administration as compared to methanol extract of leaf callus culture of *O. basilicum* i.e. 11.09% and standard drug Indomethacin i.e. 21.17% in 1<sup>st</sup> hour after induction of Carrageenan paw edema (fig. 2).



**Fig. 2:** Comparison of paw edema percentage inhibition shown by tannins extracted from seedling leaf tissue and callus culture extracts of *A. aspera* and *O. basilicum* against control at 0h, 1h, 2h, 3h and 4h. (A= *A. aspera*, O= *O. basilicum*).

**Wound healing potential of tannins of leaf callus culture extract**

Among wound models used, burn wound model showed the best results in form of contraction and closure of wound. Tannins from callus cultures of leaf of *O. basilicum* in form of Cream O showed comparatively better healing/closure of wound i.e. 87.09% as compared

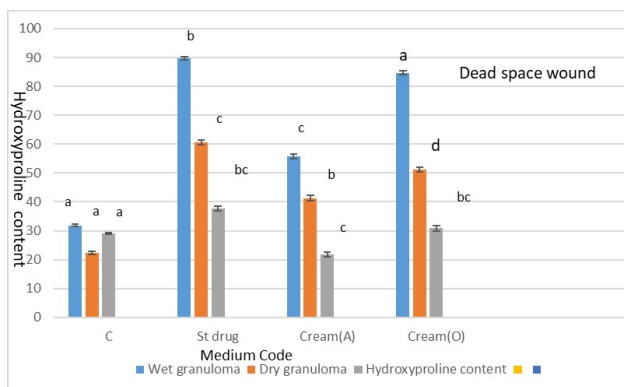


**Fig. 3:** Topical application of tannins from callus culture extracts of leaf of *A. aspera* and *O. basilicum* on burn wound model. Povidone iodine (1% w/w); and methanol extract of *A. aspera* and *O. basilicum* (1%w/w) compared with control. (Cream O, Cream A, St, C).

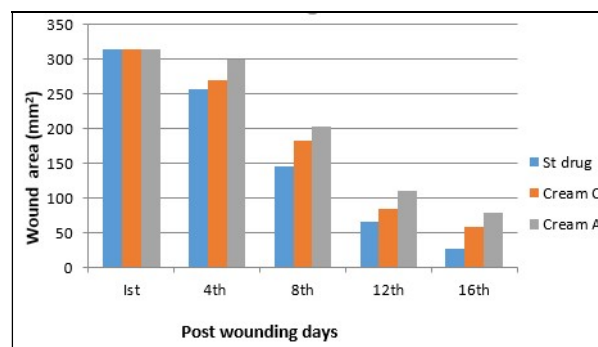
to cream A of *A. aspera* i.e. 82.44%. Wound healing potential of tannins from both plant extracts comparable to standard drug Povidone iodine with slight difference (fig. 3).

Wound area analysis (mm<sup>2</sup>) of burn wound model over the duration of 16 days showed that the standard drug Povidone iodine showed slightly better healing properties as compared to plant extracts. The cream O of wound area exhibited better healing result as compared to cream A (fig. 4).

Tannins in form of Cream O showed more hydroxyproline content i.e. 30.86±0.85µg than cream A i.e. 21.77±0.9 µg in dead space wound model. Povidone iodine showed hydroxyproline content i.e. 37.73±0.94 µg a bit higher than leaf seedling tissue and callus culture extracts (fig. 5).

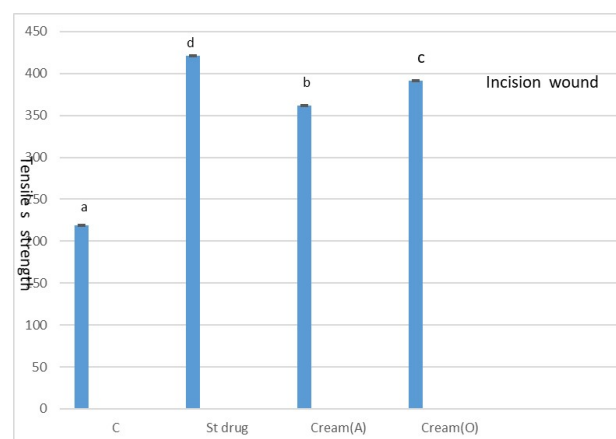


**Fig. 5:** Effect of tannins from callus cultures of leaf of *A. aspera* and *O. basilicum* on dead space wound by hydroxyproline content assay. Povidone iodine (1% w/w); methanol extract of *A. aspera* and *O. basilicum* (1% w/w) compared with control. The letters a to d on bars indicate significant difference where  $P \leq 0.05$  using DMARTS using the SAS version 9.1 software program. (Cream O, Cream A, St, C)



**Fig. 4:** Wound area plot (mm<sup>2</sup>) of burn wound model changeover during 16 days by creams of two plant extracts compared with standard drug. Cream O = Cream of *O. basilicum*, Cream A = Cream of *A. aspera*, St= Standard drug (Povidone iodine), C= Control).

Cream O showed more tensile strength i.e. 391.25±0.86 g/mm<sup>2</sup> as compared to cream A i.e. 361.45±0.93 g/mm<sup>2</sup> in incision wound model but slightly lesser than standard drug Povidone iodine i.e. 421.36±0.91 g/mm<sup>2</sup> (fig. 6).

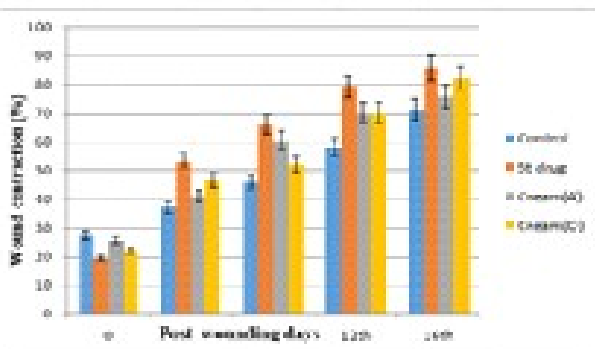


**Fig. 6:** Effect of tannins isolated from callus culture extracts of leaf of *A. aspera* and *O. basilicum* on wound in incision wound model. Povidone iodine (1% w/w); methanol extract of *A. aspera* and *O. basilicum* (1%w/w) compared with control. The letters a to d on bars indicate significant difference where  $P \leq 0.05$  using DMARTS using the SAS version 9.1 software program.

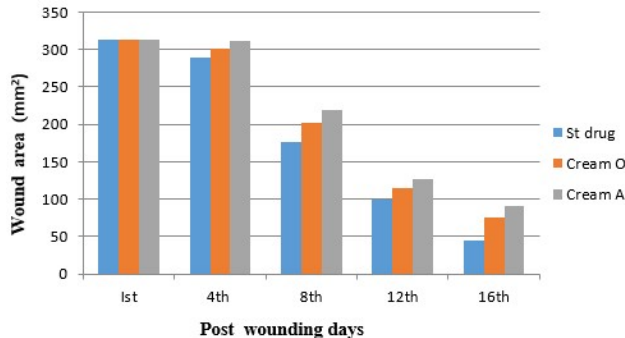
Excision wound model showed better contraction and closure of wound under the influence of tannins from leaf callus cultures of *O. basilicum*. Cream O showed better result i.e. 82.16% in closure of wound as compared to cream A i.e. 75.56%. Standard drug Povidone iodine showed slightly higher wound healing activity i.e. 86.06% than leaf seedling tissue and callus culture extracts (Fig. 7).

Wound area analysis (mm<sup>2</sup>) excision wound model over the duration of 16 days, the standard drug Povidone iodine showed maximum healing effect as compared to other two plant extracts. The cream O of wound area

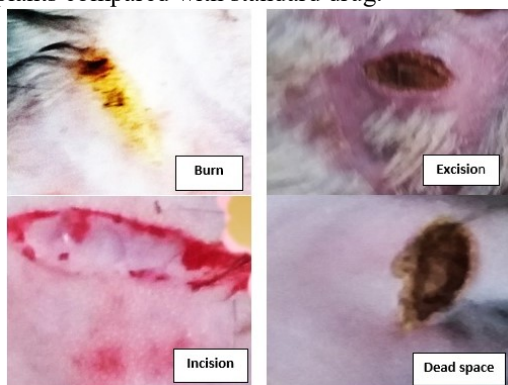showed better healing result as compared to cream A (fig. 8). Different wound models used in the study were shown in fig 9. Figs. 10 to 12 represented the wound healing process using both plants extracts and standard drug. Fig 13 showed the comparison of wound healing process in control and treatment groups. Better wound contraction was observed in treatment groups. Histopathology in incision wound showed the presence of connective tissue and capillaries. In excision, dead space and burn wound models showed the abundance of collagen bundles, connective tissue (figs. 14, 15).



**Fig. 7:** Topical application of tannins isolated from callus culture extracts of leaf of *A. aspera* and *O. basilicum* on wound contraction by excision wound model. Povidone iodine (1% w/w), methanol extract of *A. aspera* and *O. basilicum* (1%w/w) compared with control.



**Fig. 8:** Wound area plot (mm<sup>2</sup>) of excision wound model changeover during 16 days of application of creams of two plants compared with standard drug.



**Fig. 9:** Different wound healing models used in the present study (4x).

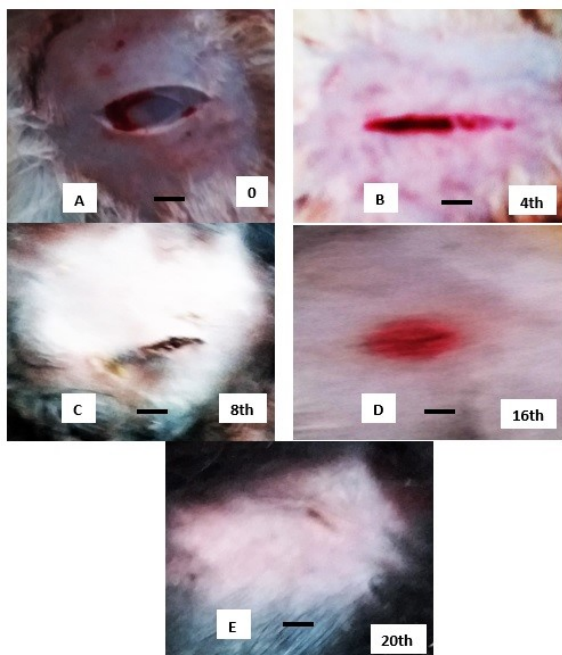
## DISCUSSION

### Anti-inflammatory potential

Carrageenan induced paw edema model is used for acute inflammation in animals which releases serotonin, histamine and increases prostaglandin in damaged tissue of animals and involves synthesis of bradykinin, leukotrienes from polymorphonuclear cells (Antonio, 1998; Yi-Zhong *et al.*, 2006). There is inverse relationship between paw edema and percentage inhibition. The procedure includes anti-inflammatory effect of tannins through scavenging of radicals and suppression of expression of mediators i.e. cytokinase and COX-2 (Mona *et al.*, 2014). Paw edema was reduced by using tannins of callus cultures of *A. aspera*. Tannins from callus culture of *O. basilicum* showed less percentage inhibition as compared to *A. aspera*. Condensed tannins from callus culture extracts of leaf of *A. aspera* reduced the release of many mediators in initial and later step of inflammation. Leaves and roots of the mentioned plants contain biologically active compounds such as glycosides, flavonoids, alkaloids and tannins (Qiao *et al.*, 2009) (Duarte *et al.*, 2009). Condensed tannins present in leaf callus culture of *A. aspera* have more ortho- hydroxyl group resulting in increased anti-inflammatory activity as compared to *O. basilicum* (Gupta *et al.*, 2005). Anti-inflammatory activity of tannins as documented in different researches Such as tannins isolated from grape seed reduced inflammatory disorders through regulating cytokine genes expression (Terra *et al.*, 2007; Chacon *et al.*, 2009), tannins extracted from *A. nodosum* and *E. carva* showed significant anti-inflammatory effects by inhibiting cytokines release (Dutot *et al.*, 2012) prostaglandin-E2 and NO formation (Wijesinghe *et al.*, 2013), condensed tannins isolated from seeds of black raspberry exhibited anti-inflammatory activity by inhibiting lipopolysaccharide-induced RAW 264.7 cells which produce nitric oxide (Park *et al.*, 2014) and hydrolysable tannins from *Myricaria bracteata* exhibited considerable anti-inflammatory activity to control arthritis and ear edema in mice (Liu *et al.*, 2015) proposed anti-inflammatory procedure due to scavenging free radicals.

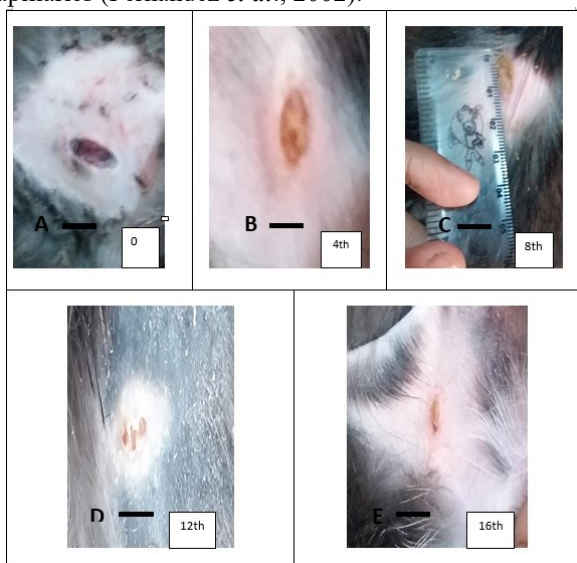
### Wound healing potential

Wound healing is a complex mechanism involves re development of epidermal layer and cellular structures in injured tissue. Procedure can be divided into three steps (1) inflammatory phase, (2) Regeneration phase, (3) maturation phase. Characteristics of these phases are erythema, heat, edema and pain. During the regeneration step, new collagen bundles, capillaries and extra cellular matrix rebuilds at wound area. In final step epithelial cells are formed at the wound surface. The maturation step includes remodeling of collagen (Mondal *et al.*, 2016).



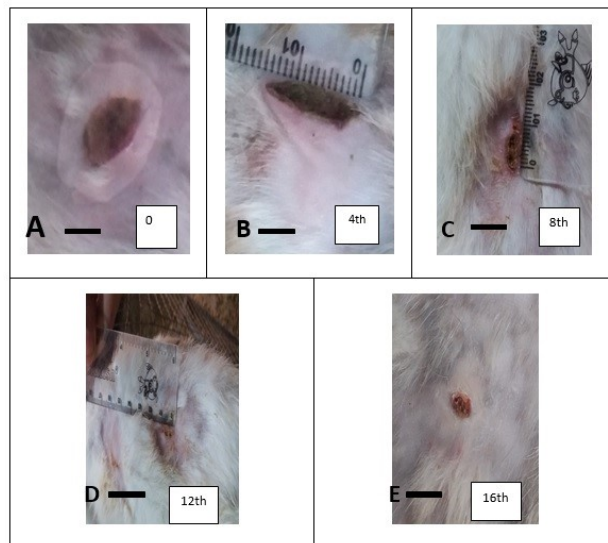
**Fig. 10:** Excision wound healing from standard drug Povidone iodine. The figure illustrates contraction of wound on rabbit. Photographs on 0, 4, 8, 12 and 16<sup>th</sup> day (4x). (Scale bar=1cm) (A =0.83 cm; B =0.37 cm; C=0.30 cm; D=0.25 cm; E =0.16 cm).

Traditionally, pastes, decoctions or extracts of plant are used to treat wounds. Leaf callus cultures of both plants contain sufficient quantity of tannins which promoted wound healing by their antimicrobial mechanism (Fleischner, 1985; Gertie *et al.*, 2002) and chelation of free radicals like oxygen and increased contraction of wound and formed large amount of fibroblast and capillaries (Fernandez *et al.*, 2002).



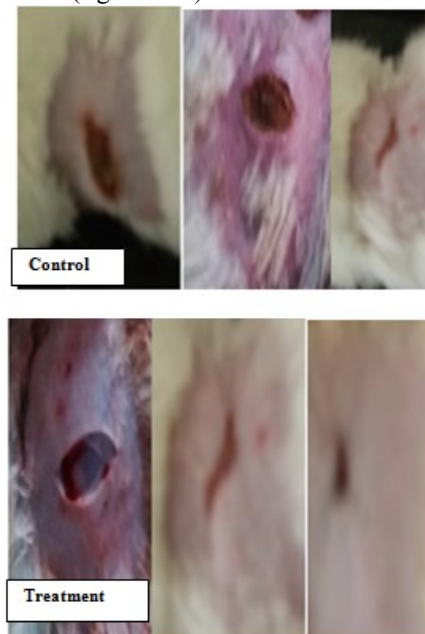**Fig. 11:** Excision wounds healing by tannins from leaf callus culture of *A. aspera*. The figure illustrated contraction of wound on rabbit. Photographs on 0, 4, 8, 12

and 16<sup>th</sup> day (4x). (Scale bar= 1cm) (A=1.53 cm; B=0.75 cm; C=0.6 cm; D=0.44 cm; E =0.3 cm).



**Fig. 12:** Wound healing in excision wound by tannins from leaf callus culture of *O. basilicum*. The figure illustrated contraction of wound on rabbit. Photographs on 0, 4, 8, 12 and 16<sup>th</sup> day (4x). (Scale bar=1 cm) (A=0.66 cm; B=0.35 cm; C=0.28 cm; D=0.18cm; E 0.14cm).

In present experiment, among four wound models, burn wound model showed the best results in terms of contraction and closure of wound as compared to other wound models (figs. 3 & 4).



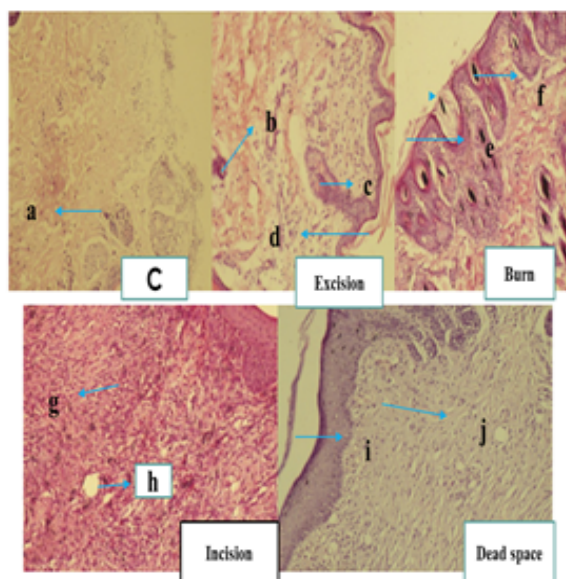
**Fig. 13:** Wound contraction in control and treatment rabbit wound model on 8 and 16<sup>th</sup> day (4x).

Tannins in form of Cream O showed better results in closure of wound comparable to cream A (figs. 3 & 4). Hydrolysable tannins like tannic acid is important in management and healing of burn wound at faster rate

**Table 1:** No of macrophages in different wound models per cubic mm

Wound Model	No of macrophages (per cubic mm)
Incision wound (Fig 14)	80-86
Dead space (Fig 14)	70-75
Burn wound (Fig 15)	85-90
Excision wound (Fig 15)	60-65
Incision wound (Fig 15)	70-75

compared to excision wound due to antioxidant potential and collagen formation involves in healing of burn wound (Halkes *et al.*, 2002). Solanki *et al.* (2012) studied the wound healing activity by using ethanolic leaf extract of *O. basilicum* in rat. He found similar results of wound healing activity. Cream O containing large quantity of hydrolysable showed a bit faster wound healing as compared to cream A. Wound healing activity of cream O, cream A and standard drug were comparable with minute difference.

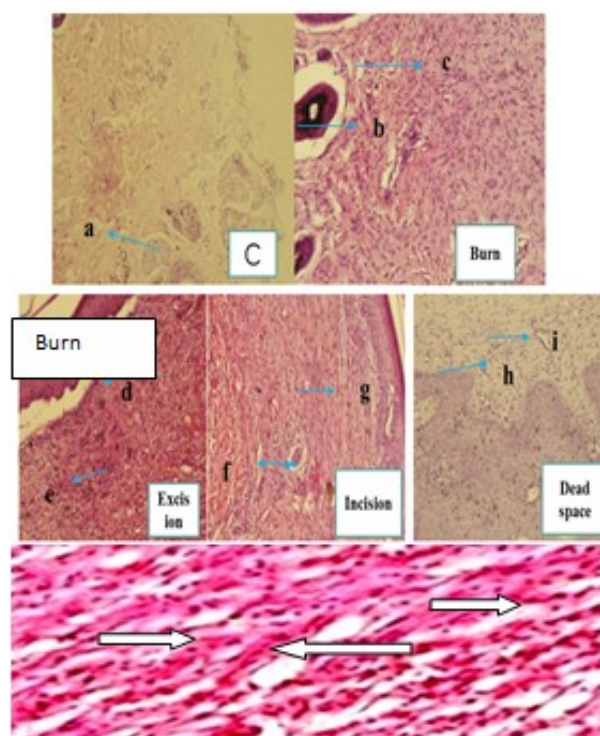


**Fig. 14:** Histopathological study of wound models treated by tannins from leaf callus culture of *A. aspera*. Control (a: inflammation), Excision: (b: capillaries, c: epithelium, d: connective tissue), Burn: (e: Collagen bundles, f: capillaries), Incision: (g: connective tissue, h: adipose tissues), Dead space: (i: collagen bundles, j: connective tissue). Hematoxylin and eosin stained animal tissues at 400x.

**Histopathological study**

Inflammatory cells were seen in control plate. Capillaries, epithelium and collagen bundles were present in excision wound model plate. Capillaries, connective tissue and collagen bundles were occurred in burn wound model plate. Fibrous connective tissue and adipose tissue were seen in incision wound model plate. Collagen bundles and connective tissue were seen in dead space wound model plate (fig. 14). Inflammatory cells were seen in control plate. Capillaries and collagen bundles were present in

burn wound model plate. Epithelium and connective tissue were present in excision wound model plate. Capillaries, collagen bundles, and adipose tissue were present in incision wound model plate. Epithelium, and collagen bundles were present in dead space wound model plate (fig. 15).



**Fig. 15:** Histopathological study of wounds treated by tannins from leaf callus culture of *O. basilicum*. Control: (a: inflammation), Burn: (b: capillaries, c: collagen bundles), Excision (d: epithelium, e: connective tissue), Incision: (f: capillaries g: angiogenesis), Dead space: (h: adipose tissue, i: collagen bundles). Arrows showing collagen bundles in Burn wound model. (Hematoxylin and eosin stained animal tissues at 400x).

**CONCLUSION**

Effectiveness of tannins from biotechnologically propagated calluses against inflammation and their wound healing potential comparable to standard drugs indicates the importance of biotechnological production of tannin extracts and the study on tannins may contribute to formation of new drugs which may be helpful in the

treatment of diseases. However further research is required in isolation and use of tannins in pre-clinical trial as anti-inflammatory and wound healing agents.

## REFERENCES

- Antonio AM and B ARMS (1998). Oral anti-inflammatory and anti-ulcerogenic activities of a hydroalcoholic extract and partitioned fractions of *Turnera ulmifolia* (Turneraceae). *J. Ethnopharmacol.*, **61**(3): 215-228.
- Bairy KL, Abhinav R and Shakta MS (2014). Evaluation of burn wound healing activity of topical regular insulin in non-diabetic and streptozocin-induced diabetic rats. *Int. J. Pharm. Pharm. Sci.*, **6**(8): 127-130.
- Bedi MK and Shenefelt PD (2002). Herbal therapy in dermatology. *Arch. Dermatol.*, **138**(2): 232-242.
- Brown DJ and Dattner AM (1998). Phytotherapeutic approaches to common dermatologic conditions. *Arch. Dermatol.*, **134**(11): 1401-1404.
- Burke A, Smyth E and Fitz GGA (2005). Analgesic antipyretic agents; Pharmacotherapy of gout. In: Brunton LB, Lazo JS, Parker KL (Ed.) Goodman & Gilman's the Pharmacological Basis of Therapeutics. McGraw-Hill, New York, USA, pp.671-715.
- Chacon MR, Ceperuelomallafre V, Maymomasip E, Mateosanz JM, Arola L and Guitierrez C (2009). Grape-seed procyanidins modulate inflammation on human differentiated adipocytes *in vitro*. *Cytokine*, **47**(2): 137-142.
- De Fatima A, Modolo LV, Sanches AC and Porto RR (2008). Wound healing agents: The role of natural and non-natural products in drug development. *Mini. Rev. Med. Chem.*, **8**(9): 879-888.
- Duarte PM, Cutrim de Mendonça A, Máximo MBB, Santos VR, Bastos MF and Nociti JFH (2009). Differential cytokine expressions affect the severity of peri-implant disease. *Clin. Oral. Implan. Res.*, **20**(5): 514-520.
- Dubay GA, Chaurasiya and RP Singh (2016). Evaluation of wound healing activity of Aerial parts of *Asteracantha longifolia* Nees by various wound healing models. *IJIET*, **34**(6): 34-42.
- Dutot M, Fagon R, Hemon M and Rat P (2012). Antioxidant, anti-inflammatory and anti-senescence activities of phlorotannin-rich natural extract from brown seaweed *Ascophyllum nodosum*. *Appl. Biochem. Biotech.* **167**(8): 2234-2240.
- Egloffyz C, Sawatskyy A, Leonardy T, Hartx DA, Valderrabanoz VW and Herzog W (2014). Effect of muscle weakness and joint inflammation on the onset and progression of osteoarthritis in the rabbit knee. *Osteoarthritis and Cartilage*, **22**(11): 1886-1893.
- Fernandez O, Capdevila JZ, Dalla G and Melchor G (2002). Efficacy of *Rhizophora mangle* aqueous bark extract in the healing of open surgical wounds. *Fitoterapia.*, **73**(7-8): 564-568.
- Favaretto ALV, Conterera MGD, Petebusci SO, Silva-Neto CR, Lopes RA and Satake T (1985). Acao cicatrizante do extrato aquoso de casca de barbatimão *Stryphnodendron obovatum* Benth. em úlceras de contencao em ratos. *Rev. Esc. Odontol. Alfenas.*, **8**: 7-11.
- Fleischner AM (1985). Plant extracts: To accelerate healing and inflammation. *Cosmet. Toilett.*, **100**(42): 45-58.
- Getie M, Mariam GT, Reitz R and Neubert RH (2002). Evaluation of the release profiles of flavonoids from topical formulations of the crude extract of the leaves of *Dodonea viscosa* (Sapindaceae). *Pharmazie.*, **57**(43): 320-322.
- Gupta M, Mazumder UK, Kumar RS, Gomathi P, Rajeshwar Y, Kakoti BB and Selven VT (2005). Anti-inflammatory, analgesic and antipyretic effects of methanol extract from *Bauhinia racemosa* stem bark in animal models. *J. Ethnopharmacol.*, **98**(3): 267-273.
- Halkes SBA, van den Berg AJJ, Hoekstra MJ, du Pont JS and Kreis RW (2002). Transaminase and alkaline phosphatase activity in the serum of burn patients treated with highly purified tannic acid. *Burns*, **28**(5): 449-445.
- Hupukens P, Boxma H and Dokter J (1995). Tannic acid as topical agent in burns: Historical considerations and implications for new developments. *Burns*, **21**(1): 57-61.
- Kapu SD, Ngwai YB, Kayode O, Akah PA, Wambebe C and Gamaniel K (2001). Anti-inflammatory, analgesic and anti-lymphocytic activities of the aqueous extract of *Crinum giganteum*. *J. Ethnopharmacol.*, **78**(1): 7-13.
- Koné M, Kone N, Silue AB, Soumahoro TH and Kouakou (2015). *In vitro* Seed Germination and Seedling Growth of Bambara Groundnut (*Vigna subterranea* (L.) Verdc. (Fabaceae). *The Sci. World. J.*, 2015:1-8 .
- Kumar, Vijayakumar, Govindarajan and Pushpangadan (2007). Ethnopharmacological approaches to wound healing exploring medicinal plants of India. *J. Ethnopharmacol.*, **114**(2): 103-113.
- Lopes CG, Sanches CCA, Nakamura VC, Filho DPB, Hernandes L and Mello PCJ (2005). Influence of extracts of *Stryphn odendron pollyphyllum* Mart and *Stryphnodendron obovatum* Benth on the cicatrisation of cutaneous wounds in rats. *J. Ethnopharmacol.*, **99**(3): 265-272.
- Liu JB , Ding YS, Zhang Y, Chen JB, Cui BS and Bai JY (2015). Anti-inflammatory hydrolyzable tannins from *Myricaria bracteata*. *J. Nat. Prod.*, **78**(5): 1015-1025.
- Matthew S, Jain AK, James M, Matthew C and Bhowmik D (2013). Analgesic and Anti-Inflammatory Activity of *Kalanchoe Pinnata* (Lam.). *Pers. J. Med. Plants. Stud.*, **1**(2): 24-28.
- Mona SM, Wadah JA. Osman, EAE. Garelnabi, Zuheir O, Bashier O, Hassan SK and Magdi AM (2014). Secondary metabolites as anti-inflammatory agents. *J. Phyto.*, **3**(4): 275-285.

- Moosophin K, Wetthaisong T, Seeratchakot L and Kokluecha W (2010). Tannin extraction from *Mangosteen peel* for protein precipitation in wine. *KKU Res. J.*, **15**(5): 377-385.
- Mondal S, Debjit G, Seru G, Motati S and Reddy KR (2016). Evaluation of Healing Potential of *Achyranthes aspera* L. (Amaranthaceae) seeds in excision, incision, dead space and burn wound model-An *in vivo* Study. *Pharmacognosy*, **8**(3): 300-305.
- Mota ML, Thomas G and Barbosa FJM (1985). Anti-inflammatory actions of tannins isolated from the bark of *Anacardium occidentale* L. *J. Ethnopharmacol.* **13**(3): 289-300.
- Mukherjee PK and Houghton PJ (2009). Evaluation of Herbal Medicinal Products. (Pharmaceutical press) pp.13-22.
- Neto JJ, Fracasso JF, Neves MCLC, Santos LE and Banuth VL (1996). Tratamento de úlceras varicosa e lesões de pele com *Calendula officinalis* e/ou com *Stryphnodendron barbatiman* (Vellozo) Martius. *Rev. Ciênc. Farm.* **17**: 181-186.
- Palermo D, Pereira LCMS and Mello JCP (2002). HERNANDES, L. Atividade cicatrizante do barbatimao [*Stryphnodendron adstringens* (Martius) Coville] em feridas cutaneas. *Arq. Apadec.* **6**: 2.
- Periyasamy A, Rajkumar and Kanimozhi M (2010). Phytochemical screening and antimicrobial activity from five Indian medicinal plants against human pathogens. *Middle-East J. Sci. Res.*, **5**(3): 157-162.
- Pizzi A (2003). in Handbook of Adhesive Technology, Revised and Expanded, CRC Press.
- Park M, Cho H, Jung H, Lee H and Hwang KT (2014). Antioxidant and anti-inflammatory activities of tannin fraction of the extract from black raspberry seeds compared to grape seeds. *J. Food. Biochem* **38**(3) 259-270.
- Qiao W, Yao Z, Zhang W and Duan HQ (2009). Two new diterpenes from *Duchesnea indica*. *Chinese. Chem. Lett.*, **20**: 572-575.
- Santoro MM and Gaudino G (2005). Cellular and molecular facets of keratinocyte reepithelization during wound healing. *Exp. Cell. Res.*, **304**(1): 274-286.
- Singer AJ and Clark RA (1999). Cutaneous wound healing. *N. Engl. J. Med.*, **341**(10): 738-746.
- Solanki R, Purohit SK, Mathur V and Mathur M (2012). Evaluation of wound healing activity of ethanolic extracts of *Ocimum basilicum* leaves in male albino rats. *IJDRT*, **2**(2):208-211.
- Terra X, Valls J, Vitrac X, Mérrillon JM, Arola L and Ardévol A (2007). Grape-seed procyanidins act as antiinflammatory agents in endotoxin-stimulated RAW 264.7 macrophages by inhibiting NFkB signaling pathway. *J. Agric. Food. Chem.*, **55**: 4357-4365.
- Vieira MC, Lelis RCC., Bruno C, Da Silva G and De Lima O (2011). Tannin Extraction from the Bark of *Pinus oocarpa* var. *oocarpa* with Sodium Carbonate and Sodium Bisulfite. *Floresta e Ambiente.*, **18**(1): 1-8.
- Vines G (2004) Herbal harvests with a future: towards a sustainable source for medicinal plants. [www.plantlife.org.uk](http://www.plantlife.org.uk)
- Walker HL and Mason AD Jr (1968). A standard animal burn. *J. Trauma.*, **8**(6): 1049-1051.
- WHO (2002). Traditional Medicine Strategy (2002–2005). WHO/EDM/TRM/2002.1. Geneva, Switzerland: World Health Organization.
- Wijesinghe WJ, Ginnae A, Wonwoo L, Kang MC, Euna K and Youjin J (2013). Anti-inflammatory activity of phlorotannin-rich fermented ecklonia cava processing by-product extract in lipopolysaccharide-stimulated raw 264.7 macrophages. *J. Appl. Phycol.*, **25**(4): 1207-1213.
- Woessner JF (1961). The determination of hydroxyproline in tissue and protein samples containing small proportions of imino acid. *Arch. Biochem. Biophys.*, **93**(2): 440-447.
- Vidinsky BP, Gal T, Toporcer F, Longauer L, Lenhardt N and Bobrov J (2006). Histological Study of the First Seven Days of Skin Wound Healing in Rats. *Acta. Vet. Brno.*, **75**: 197-202.
- Yi-Zhong C, Meis S, Jie X, Qiong L and Harold C (2006). Structure-radical scavenging activity relationships of phenolic compounds from traditional Chinese medicinal plants. *Life. Sci.*, **78**: 2872-2888.