

Anti-inflammatory and antibacterial activities of *P. petiolosa* (Christ) Ching ethyl acetate extract against *S. aureus* in mice

Juan Cheng¹, Mei Cao², Sijun Yi¹, Yuwei Tao¹, Lei Wang¹, Andong Zhang¹, Ningzhe Li¹, Daoyan Wu¹, Jingshan Peng¹, Jun Fang², Liju Song¹ and Jian Zhao^{1*}

¹Key Laboratory of Bio-Resource and Eco-Environment of Ministry of Education, College of Life Sciences, Sichuan University, Chengdu, Sichuan, P.R. China

²Core Laboratory, School of Medicine, Sichuan Provincial People's Hospital Affiliated to University of Electronic Science and Technology of China, Chengdu, P.R. China

Abstract: *P. petiolosa* as a typical Chinese herbal medicine has been generally utilized as Chinese native medicine formulation for treatment of chronic bronchitis, bronchial asthma and pneumoconiosis. The objective of this study was to evaluate the anti-inflammatory and antibacterial activities of *P. petiolosa* ethyl acetate extract (PPEAE) against *S. aureus* in mice. The air-dried leaves were extracted with ethyl acetate, mice were infected pneumonia by *S. aureus*. Colonization of *S. aureus* in lung tissue was calculated by plate colony count. The number of white blood cells (WBC) in blood was measured by blood cell automatic analyzer. The histopathological analysis of hematoxylin-eosin staining (H&E) of lung tissue was observed under microscope. Real-time PCR assay was employed to determine the relative mRNA expression of HO-1, iNOS and TNF- α . The results showed that, compared with control, after treated with PPEAE the wet/dry (W/D) weight ratio of mice lung tissue (decreased from 5.371 to 4.9) and the number of white blood cells (WBC) (decreased by 3.13×10^9 /mL) decreased dramatically. The number of *S. aureus* was significantly reduced (from 1.93×10^5 CFU/mL to 26×10^3 CFU/mL) in lung tissue after treated with PPEAE. Furthermore, H&E staining showed that PPEAE obviously relieved the inflammation of lung tissue of infected mice. Meanwhile, real-time PCR results indicated that PPEAE down regulated the expression of inflammatory iNOS, TNF- α mRNA and up regulated the expression of anti-inflammatory HO-1 mRNA. In summary, this study revealed that application of crude product PPEAE had prominent antibacterial activity against *S. aureus*. PPEAE significantly reduced the biomass of *S. aureus* in lung tissue and effectively relieved the inflammation of *S. aureus*-induced pneumonia.

Keywords: *P. petiolosa* ethyl acetate extract (PPEAE), anti-inflammatory, antibacterial, *S. aureus*-induced pneumonia

INTRODUCTION

Staphylococcus aureus (*S. aureus*) is a gram-positive human pathogen that caused diverse diseases rang from minor skin to life-threatening deep tissue infections such as pneumonia, osteomyelitis and endocarditis (Lowy 1998). Up to date, *S. aureus* is increasingly recognized as one of the most significant infectious threaten to human health, this situation reinforced by the increasing incidence of nosocomial as well as community-acquired infections worldwide (Montgomery and Rs, 2009). Alpha-toxin, a major virulence factor, secreted by *S. aureus* is the leading causes of pneumonia (Hua *et al.*, 2014). Increasing of respiratory diseases infected by *S. aureus* heighten the need for effective medicines and therapeutic strategies to prevent further infection (Ragle and Wardenburg, 2009). In addition, the emerging resistance of traditional antibiotics considered to be the biggest obstacle for disease control, makes the development of anti-virulence strategies urgent (Song *et al.*, 2016).

Pyrrosia petiolosa (Christ et Bar.) Ching (*P. petiolosa*) is a perennial herb fern belong to *Pyrrosia* genus in the family Polypodiaceae which mainly distributed in China.

*Corresponding author: e-mail: zj804@163.com

In Chinese traditional system of medicine, various parts of this plant had been extensively studied for its ability to treat chronic bronchitis, pyelonephritis, local inflammation and to facilitate wound healing (National Pharmacopoeia Commission (NPC), 2010). The "Wai Taimiyao", a distinguished pharmacopoeia (published in Tang Dynasty) in China, also recorded that the *P. petiolosa* with significantly expectorant, diuretic and antitussive effect. *P. petiolosa* also have been used as a traditional Chinese medicine for the treatment of chronic bronchitis and asthma, it is reported that the patients with severe asthma or even bronchial infections had significantly relieved after added the *P. petiolosa* into the clinical cough and asthma prescriptions (Wang *et al.*, 2011). Previous study revealed that *P. petiolosa* ethyl acetate extract (PPEAE) had inhibitory activity against *S. aureus*, with MIC and MBC of 7.8 and 15.6mg/mL, respectively. The results of GC-MS illustrated that the major classifications were esters, alcohols, phenols and aldehydes (Song *et al.*, 2016). It has been reported that the extract of *P. petiolosa* possessed anti-inflammatory, antibacterial activity (Cheng *et al.*, 2014) and antioxidant activity (Hsu, 2008). However, investigation concerning the anti-inflammatory and antibacterial effect of the extract from *P. petiolosa* against *S. aureus* in mice was

rare. In addition, Chinese herbal medicine with broad-spectrum antibacterial activities and no side effects had attracted many scholars to attach great importance. Thus, provide a new direction for the prevention, control and reduction of respiratory diseases infectious.

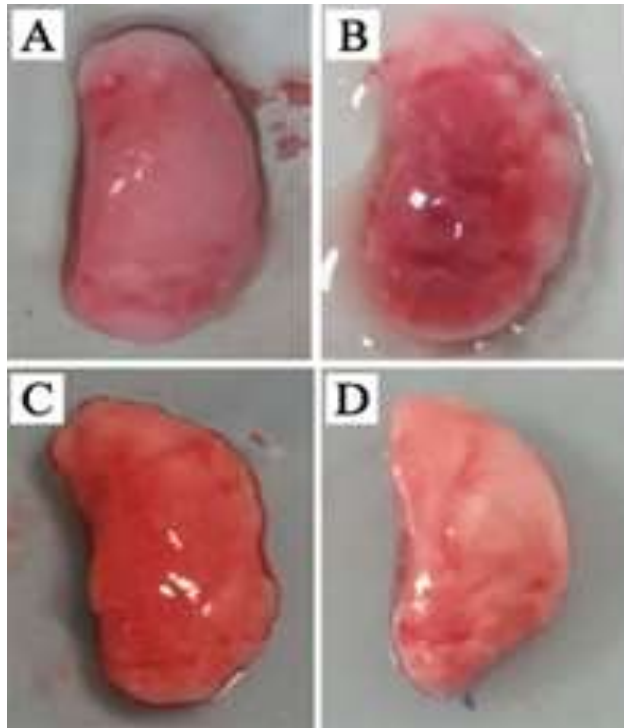


Fig. 1: Morphological observation of lung tissues from each group of mice. Uninfected mice treated with sterile water shown in (A). Mice inoculated with *S. aureus* shown in (B), Infected mice treated with PPEAE and Levofloxacin shown in (C) and (D), respectively.

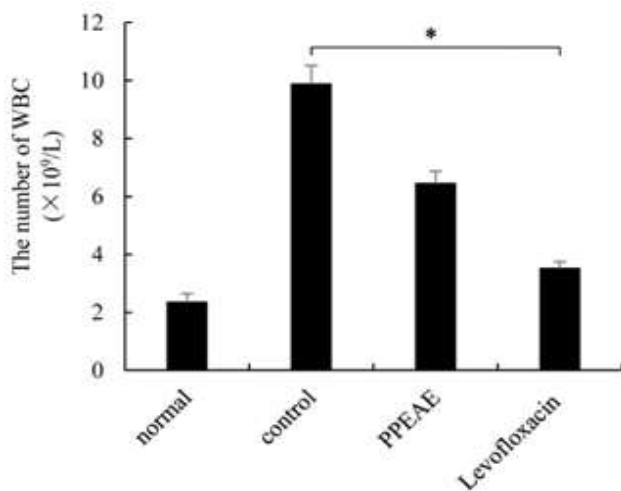


Fig. 2: The number of white blood cells (WBC) in blood from each group of mice. Values are expressed in mean \pm S.D. for four samples. Student's t-test was used to determine statistical significance between groups, $*P < 0.05$.

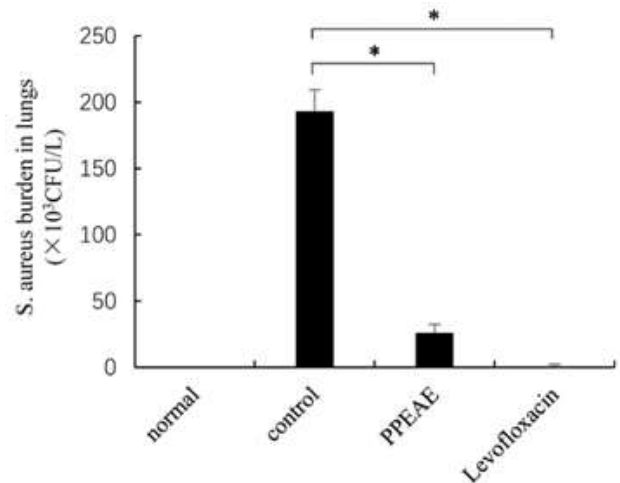


Fig. 3: The biomass of *S. aureus* contained in the lung tissues from each group of mice. Values are expressed in mean \pm S.D. for four samples. Student's t-test was used to determine statistical significance between groups, $*P < 0.05$.

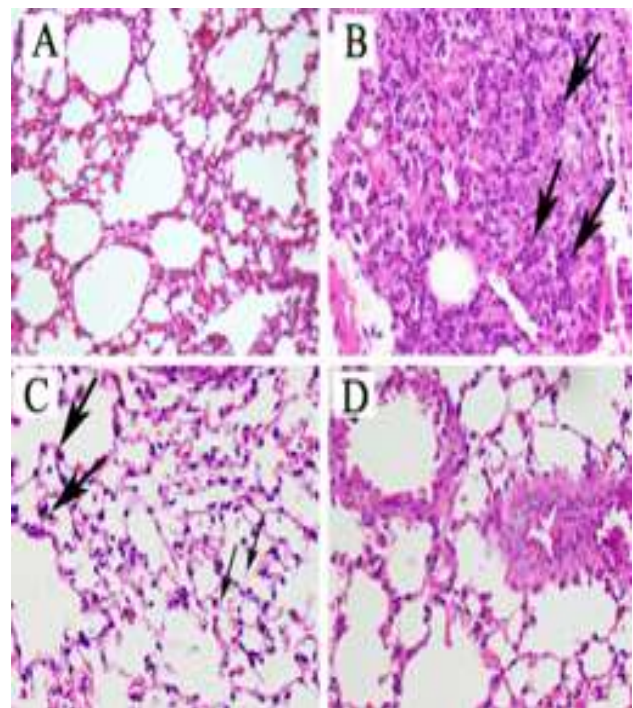


Fig. 4: Pathological observation of lung tissues from each group of mice. Inflammatory cell (Thick arrow), red blood cell (thin arrow). Uninfected mice treated with sterile water shown in (A). Infected mice treated with sterile water shown serious inflammatory cell infiltration (Thick arrow), in (B). Infected mice treated with PPEAE shown slight inflammatory cell infiltration (Thick arrow) and red blood cell exudation (thin arrow), in (C). Infected mice treated with Levofloxacin shown clear alveolar structure, no inflammatory symptoms, in (D). Hematoxylin and eosin, $\times 200$.




Fig. 5: Relative gene expression levels of iNOS, TNF- α , HO-1 mRNA in each group of mice. (A): the level of iNOS mRNA in each group of mice. (B): the level of TNF- α mRNA in each group of mice. (c): the level of HO-1 mRNA in each group of mice. Values are expressed in mean \pm S.D. for four samples. Student's t-test was used to determine statistical significance between groups, * $P < 0.05$.

Table 1: Primers used for real-time PCR

| Gene | Primer sequence (5'-3') | Location within gene |
|-------------|-------------------------|----------------------|
| 16S rRNA-fw | GCTGCCCTTTGTATTGTC | 287–305 |
| 16S rRNA-rv | AGATGTTGGGTAAAGTCCC | 446–465 |
| sea-fw | ATGGTGCTTATTATGGTTATC | 335–356 |
| sea-rv | CGTTTCCAAAGGTAAGTGTATT | 477–498 |
| hla-fw | TTGGTGCAAATGTTTC | 485–501 |
| hla-rv | TCACTTTCCAGCCTACT | 569–586 |
| agrA-fw | TGATAATCCTTATGAGGTGCTT | 111–133 |
| agrA-rv | CACTGTGACTCGTAACGAAAA | 253–274 |

Table 2: The ratio of lung tissue wet/dry weight (W/D)

| Group | W (g) | D (g) | W/D ratio | (W - D)/W% |
|------------------|-------------------|--------------------|-----------|------------|
| Negative control | 0.084 \pm 0.013 | 0.018 \pm 0.003 | 4.592 | 78.223 |
| Model | 0.094 \pm 0.007 | 0.0174 \pm 0.004 | 5.371 | 81.381 |
| Tested group | 0.081 \pm 0.025 | 0.017 \pm 0.004 | 4.908 | 79.625 |
| Positive control | 0.090 \pm 0.024 | 0.020 \pm 0.005 | 4.538 * | 77.965* |

PPEAE - ethyl acetate extract of *P. petiolosa*. Values are expressed in mean \pm S.D. for four samples. Student's t-test was used to determine statistical significance between groups, * $P < 0.05$.

MATERIALS AND METHODS

Collection and Preparation of extracts of *P. petiolosa*

500g air-dried leaves were extracted twice with 1000mL ethyl acetate at a constant temperature 60 for 6 days, then filtered to obtain ethyl acetate extract supernatant. The supernatant of ethyl acetate phase was evaporated to yield dryness, dissolved the dryness in sterile water again to a concentration of 1g/mL. Finally, filtrated through a 0.22 μ m micro filter and stored at 4 for further experimentation.

Medicine Preparation

The medicine products used in our study is Levofloxacin Hydrochloride Tablets (PubChem CID: 149096, batch number: 20161005). 0.5g Levofloxacin was dissolved in 100mL sterile water to a concentration of 5mg/mL.

Animals

BALB/c mice of weighing 20-25g were obtained from Sichuan University animal institute, Chengdu, China. The temperature maintained at 26 \pm 1 and relative humidity held at 75 \pm 5%, then stabilizing for 1 week. They had been given standard pellet diet and water freely available throughout the series of investigation (Deshmukh *et al.*, 2009), these mice were used to investigate the anti-inflammatory and antibacterial activities in *S. aureus*-induced pneumonia. All animals were handled strictly complying with the Animal Care and Use Committee of laboratory animal center of Sichuan University, China, during the whole experimental process.

Mouse model creation and drug administration

A total of 24 mice were randomly divided into four groups of 6 mice each, group 1 (normal) treated with 50 μ L sterile water, groups 2 to 4 were treated with 50 μ L

(4×10^8 CFU/ml) *S. aureus* culture medium suspension which was injected into the left nare of mice, slightly anesthetized with ether, kept upright 3 minutes to make sure the bacterium was adequately breathed into mice with spontaneous respiratory [9]. After 24 hours of infection, four groups of mice were administrated 2 times a day until fifth day, as follow respectively: group 1-sterile water 0.4mL (negative/normal control), group 2-sterile water 0.4mL (model control), group 3-PPEAE (1g/mL) 0.4mL (tested group), group 4-Levofloxacin (5mg/mL) 0.4mL (positive control) (Lodhi *et al.*, 2006).

Clinical symptom

Each group of mice were carefully surveyed daily about its clinical features incorporating: diet, drinking, respiratory, weight changes and psychosis mental state during the administration for 5 days.

Wet/dry (W/D) weight ratio of lung tissue

The lung tissue of sacrificed mice from each group were weighed immediately to obtain its wet weight (*W*). Next, placed in an incubator at 80°C for 48 h, then weighed again to obtain the dry weight (*D*). The *W/D* ratio was calculated to assess lung edema. The value of water content of lung was calculated as follows: Water content of lung = $\{(W - D)/W\} \times 100$. The *W* and *D* denoted initial wet lung weight and dry lung weight.

Colonization of *S. aureus*

The left lung of mice was harvested under aseptic technique, homogenate to obtain the lung tissue suspension and orderly attenuated tenfold for 5 times to concentration of 10^{-5} , then evenly smeared 100 μ l bacterium suspension of each gradient concentration to solid LB media. followed by, cultivated under 37 for 24 h to determine the colonization of *S. aureus*, all samples were analysis in triplicate (Robinson *et al.*, 2015).

Histopathology assay

Immersed the right lung tissue in 4% para formal dehyde, embedded in paraffin, cut into 4 μ m sections, stained with hematoxylin-eosin staining (H&E) and then examined histopathology with microscope (Olympus, Japan) (Zhao *et al.*, 2016).

RNA isolation and RT-PCR

Total RNA was isolated by TRIzol (Invitrogen, Carlsbad, CA, USA). The concentration and purity were tested by BioDrop nucleic acid protein detector and loaded onto an RNase-free 1.5% agarose gel to test the RNA. Using the on-column RNase-free DNA eraser buffer to remove the remain DNA. The total c-DNA reverse transcribed from RNA was used as starting materials for real-time PCR on the step one real-time PCR system. The primer used in real-time PCR are listed in table 1. Cycling conditions consisted of an initial denaturation step at 95 for 60 s and 40 cycles at 95 for 10 s, 60 for 30 s, and 72 for 20 s. All samples were analyzed in triplicate (Qiu *et al.*, 2011).

STATISTICAL ANALYSIS

All data were analysis by SPSS statistical version 19.0 software package (SPSS® Inc. USA) and expressed as mean \pm S.D. Independent Student's t-test was used to evaluate the data, *P*-value <0.05 was considered as significant difference.

RESULTS

Morphological observation of lung tissue

The lung tissues from each group of mice were harvested at the fifth day of administration. In (fig. 1), the results showed that the mice inoculated with *S. aureus* (control) exhibited severe pneumonia, manifested as severe lung edema and pulmonary interstitial hyperemia. In contrast, the mice treated with PPEAE and Levofloxacin (positive control) obviously relieved the lung edema and pulmonary interstitial hyperemia.

Four groups treated with different agent daily-treated with sterile water (normal) in uninfected mice, in (A). Treated with sterile water (control) in infected mice, in (B). Treated with PPEAE and Levofloxacin (positive control) in infected mice, respectively, in (C and D). Infected mice treated with sterile water shown severe lung edema and pulmonary interstitial hyperemia, in (B). Infected mice treated with PPEAE and Levofloxacin obviously relieved lung edema, hyperemia. in (C and D).

W/D weight ratio of lung tissue

Table 2 displayed the *W/D* weight ratio of lung tissues from each group of mice. Compared with normal mice, the *W/D* weight ratio of control dramatically increased by 0.779. In contrast, the *W/D* weight ratio of PPEAE and Levofloxacin treated group (positive control) significantly decreased from 5.371 to 4.9 and to 4.74, respectively, indicating that PPEAE markedly relieved the pulmonary edema and protected mice from *S. aureus* infection.

Measurement of WBC in blood

Femoral artery blood was collected from each group after administration for 5 days, the number of WBC was measured by blood cell automatic analyzer. As depicted in (fig. 2), the number of WBC in control was significantly higher than that in normal mice, the mice treated with PPEAE was lower than control, but higher than Levofloxacin treated group (positive control). As a result, the *S. aureus*-induced pneumonia was successfully exhibited and the PPEAE markedly relieved the pneumonia induced by *S. aureus* in mice.

Colonization of *S. aureus*

The number of *S. aureus* contained in lung tissue was displayed in (fig. 3), there is no *S. aureus* in normal mice. Compared with control, the biomass of *S. aureus* contained in lung tissue of PPEAE and Levofloxacin treated group decreased significantly (decreased from

$1.93 \pm 0.02 \times 10^5$ CFU/ml to $(26 \pm 0.005$ and to $0.31 \pm 0.001) \times 10^3$ CFU/ml, respectively), suggesting that PPEAE obviously inhibited the growth of *S. aureus*.

Pathological observation of lung tissue

In line with the H&E results, the normal group appeared complete alveolar structure, no exudation and inflammatory symptoms (fig. 4A). In contrast, the control mice exhibited severe pneumonia, as evidenced by incomplete alveolar structure, inflammatory cell infiltration and Lung with abscess formation (fig. 4B). Treatment with PPEAE relieved the pneumonia, manifested as slight inflammatory cell infiltration and red blood cell exudation (fig. 4C). Compare with PPEAE, the Levofloxacin treated group showed complete alveolar structure, exudation and inflammatory symptoms evidently relieved (fig. 4D). In general, two administration group significantly ease the acute inflammatory symptoms. The possible mechanism is that PPEAE inhibit the expression of Alpha-toxin secreted by *S. aureus*, thereby attenuating the infect ability of *S. aureus* and provide sufficient time for the mouse autoimmune system to eliminate *S. aureus*.

Anti-inflammatory factor assay

Real-time PCR was conducted to detect the gene expression of inflammatory iNOS, TNF- α mRNA and anti-inflammatory HO-1 mRNA. The expression of HO-1, iNOS and TNF- α mRNA in control mice significantly increased by 1.87, 4.32 and 2.18 times than that of normal mice, respectively. Compared with control, after treated with PPEAE and Levofloxacin, two administration group significantly reduced the iNOS (44.4% and 70.1%, respectively), TNF- α mRNA (63.3% and 64.2%, respectively) and increased the HO-1 mRNA (83.7% and 82.9%, respectively) in cells as shown in (fig. 5). Yet, the expression of HO-1 mRNA was obviously up regulated in both PPEAE and Levofloxacin treated group, suggesting that PPEAE relieve *S. aureus*-induced inflammation by reduce the secretion of inflammatory cytokines such as iNOS, TNF- α mRNA and increase anti-inflammatory cytokine HO-1 mRNA production.

DISCUSSION

Staphylococcus aureus is a ubiquitous pathogen associated with a wide range of infections affecting the respiratory tract that range from asymptomatic colonization to full minant necrotizing pneumonia (Parker and Prince, 2012). Treatment of *S. aureus* infections changed dramatically with the emergence of methicillin resistance (Haley et al., 1982). Thus, there is an urgent need to develop new therapeutic to aid the treatment of *S. aureus* infections, especially the *S. aureus*-induced pneumonia (Qiu et al., 2011).

Currently, plant extract are gaining considerable interest

for their potential antimicrobial activities on a wide range of bacteria (Smith-Palmer et al., 2004). Some unique traits of extract from *P. petiolosa* in regard to the antibacterial activity have been displayed by our previous study. Plant products PPEAE are potential agents to cure severe infection of bacteria due to no negative side effects, non-toxicity, its wide spread availability and its effectiveness as crude preparations. It has been reported by other researcher that ethanol extract of *P. petiolosa* possessed the antioxidant (Rivera et al., 2011), antibacterial and anti-inflammatory activities (Cheng et al., 2014). These discoveries motivate us to further investigate the anti-inflammatory and antibacterial activities of PPEAE on *S. aureus* infection in mice and demonstrate that PPEAE inhibit *S. aureus* by regulate the expression of inflammatory factors. In the present study, we have observed PPEAE markedly relieved lung edema and pulmonary interstitial hyperemia. The results of PPEAE significantly reduced the W/D weight ratio of lung tissue, indicating that PPEAE was beneficial for improving lung injury in mice, this is similar to the report about dexamethasone (Hsu, 2008). Alleviation of lung injury was evidenced by attenuated pathological conditions of the lung and reduced inflammatory cell infiltration. Our study demonstrated that PPEAE play an important role in decrease the number of WBC and the biomass of *S. aureus* in lung tissue, indicating PPEAE participate bacterial clearance and protect mice from pneumonia infections (Qiu et al., 2012; Yang et al., 2015). Real-time PCR assay was conducted to determine the relative expression levels of HO-1, iNOS and TNF- α mRNA. The expression of inflammatory cytokines such as iNOS, TNF- α mRNA was obviously increased in infected mice, yet, the expression level of administration group was significantly reduced, implying PPEAE protect mice from *Staphylococcus aureus* pneumonia via inhibition of secretion of α -hemolysin (Zhang et al., 2013). Further illustrated that PPEAE via reduced the secretion of inflammatory cytokines such as iNOS, TNF- α mRNA and improved the anti-inflammatory cytokine HO-1 mRNA production to inhibit *S. aureus*-induced pneumonia.

CONCLUSION

In conclusion, administration of PPEAE from *P. petiolosa* was found to relieve the *S. aureus*-induced inflammatory and pneumonia, including relieved lung edema and pulmonary interstitial hyperemia, decreased inflammatory cell infiltration and red blood cell exudation, meanwhile, reduced the secretion of inflammatory cytokines such as iNOS, TNF- α mRNA and increased the anti-inflammatory cytokine HO-1 mRNA production. In general, our study is beneficial to exploit the *P. petiolosa* as a new respiratory disease medicine resource in pharmaceutical industry and provide a new point of view for utilization of traditional medicinal plant in china.

ACKNOWLEDGEMENTS

Juan Cheng and Mei Cao contributed equally to this work. This work was financially supported by the Sichuan Province Key Technologies Research and Development Program under Grant 2017FZ0059.

REFERENCES

- Cheng D, Zhang Y, Gao D and Zhang H (2014). Antibacterial and anti-inflammatory activities of extract and fractions from *Pyrrhosia petiolosa* (Christ et Bar.) Ching. *J. Ethnopharmacol*, **155**(2): 1300-1305.
- Deshmukh PT, Fernandes J, Atul A and Toppo E (2009). Wound healing activity of *Calotropis gigantea* root bark in rats. *J. Ethnopharmacol*, **125**(1):178-181.
- Haley RW, Hightower AW, Khabbaz RF, Thornsberry C, Martone WJ, Allen JR and Hughes JM (1982). The emergence of methicillin-resistant *Staphylococcus aureus* infections in United States hospitals. Possible role of the house staff-patient transfer circuit. *Ann. Intern. Med.*, **97** (3): 297-308.
- Hsu CY (2008). Antioxidant activity of *Pyrrhosia petiolosa*. *Fitoterapia*, **79**(1): 64-66.
- Hua L, Hilliard JJ, Shi Y, Tkaczyk C, Cheng LI, Yu X, Datta V, Ren S, Feng H and Zinsou R (2014). Assessment of an Anti-Alpha-Toxin Monoclonal Antibody for Prevention and Treatment of *Staphylococcus aureus*-Induced Pneumonia. *Antimicrob Agents Chemother*, **58**(2): 1108-1117.
- Kim HK, Missiakas D and Schneewind O (2014). Mouse models for infectious diseases caused by *Staphylococcus aureus*. *J. Immunol. Methods*, **410**: 88-99.
- Lodhi S, Pawar RS, Jain AP and Singhai AK (2006). Wound healing potential of *Tephrosia purpurea* (Linn.) Pers. in rats. *J. Ethnopharmacol.*, **108**(2): 204-210.
- Lowy FD (1998). *Staphylococcus aureus* infections. *N Engl. J. Med.*, **339**(8): 520-532.
- Montgomery CP and Rs BVS (2009). The arginine catabolic mobile element is not associated with enhanced virulence in experimental invasive disease caused by the community-associated methicillin-resistant *Staphylococcus aureus* USA300 genetic background. *Infect. Immun.*, **77**(7): 2650-2656.
- National Pharmacopoeia Commission (NPC) (2010). Chinese Pharmacopoeia. *China Medical Science and Technology Press*, pp, **02**(4): 272-288.
- Parker D and Prince A (2012). Immunopathogenesis of *Staphylococcus aureus* pulmonary infection. *Semin Immunopathol*, **34**(2): 281-297.
- Qiu J, Niu X, Dong J, Wang D, Wang J, Li H, Luo M, Li S, Feng H and Deng X (2012). Baicalin protects mice from *staphylococcus aureus* pneumonia via inhibition of the cytolytic activity of-hemolysin. *J. Infect. Dis.*, **206**(2): 292-301.
- Qiu J, Wang J, Luo H, Du X, Li H, Luo M, Dong J, Chen Z and Deng X (2011). The effects of subinhibitory concentrations of costus oil on virulence factor production in *Staphylococcus aureus*. *J. Appl. Microbiol.*, **110**(1): 333-340.
- Ragle BE and Bubeck WJ (2009). Anti-alpha-hemolysin monoclonal antibodies mediate protection against *Staphylococcus aureus* pneumonia. *Infect. Immun.*, **77**(7): 2712-2718.
- Rivera DG, Hernandez I, Merino N, Luque Y, Alvarez A, Martín Y, Amador A, Nuevas L and Delgado R (2011). *Mangifera indica* L. extract (Vimang) and mangiferin reduce the airway inflammation and Th2 cytokines in murine model of allergic asthma. *J. Pharm. Pharmacol.*, **63**(10): 1336-1345.
- Robinson KM, Lee B, Scheller EV, Mandalapu S, Enelow RI, Kolls JK and Alcorn JF (2015). The role of IL-27 in susceptibility to post-influenza *Staphylococcus aureus* pneumonia. *Respir Res*, **16**(1): 1-12.
- Smith-Palmer A and Stewart J and Fyfe L (2004). Influence of subinhibitory concentrations of plant essential oils on the production of enterotoxins A and B and α -toxin by *Staphylococcus aureus*. *J. Med. Microbiol.*, **53**: 1023-1027.
- Song L, Cao M, Chen C, Qi P, Li N, Wu D, Peng J, Wang X, Zhang M and Hu G (2016). Antibacterial activity of *Pyrrhosia petiolosa* ethyl acetate extract against *Staphylococcus aureus* by decreasing hla and sea virulence genes. *Nat Prod Res*, **31**(11): 1-7.
- Wang N, Wang JH, Li X, Ling JH and Li N (2006). Flavonoids from *Pyrrhosia petiolosa* (Christ) Ching. *J. Asian Nat. Prod. Res.*, **8**(8): 753-756.
- Yang M, Du C, Gong P, Xia F, Sun C, Feng X, Lei L, Song J, Zhang L, Wang B, Xiao F, Yan X, Cui Z, Li X, Gu J and Han W (2015). Therapeutic effect of the YH6 phage in a murine hemorrhagic pneumonia model. *Res. Microbiol.*, **166**(8): 633-643.
- Zhang Y, Wang JF, Dong J, Wei JY, Wang YN, Dai XH, Wang X, Luo MJ, Tan W, Deng XM and Niu XD (2013). Inhibition of α -toxin production by subinhibitory concentrations of naringenin controls *Staphylococcus aureus* pneumonia. *Fitoterapia*, **86**: 92-99.
- Zhao G, Wu H, Jiang K, Rui G, Zhu Z, Qiu C, Guo M and Deng G (2016). IFN- τ inhibits *S. aureus*-induced inflammation by suppressing the activation of NF- κ B and MAPKs in RAW 264.7 cells and mice with pneumonia. *Int. Immunopharmacol*, **35**: 332-340.