

Potential therapeutic effects of avenanthramide-C against lung toxicity caused by silver nanoparticles injection in rats

Najla Altwaijry¹, Thanaa A El-Masry^{1,2}, Badriyah S Alotaibi^{1*}, Ehab Tousson³, Abdulaziz A Alodhayani⁴, Kadreya El-Morshedy⁵, Nouf A Elmaged⁶, Ahmed E Sayed⁷ and Asmaa Saleh^{1,8}

¹Pharmaceutical Sciences Department, College of Pharmacy, Princess Nourah bint Abdulrahman University, Riyadh, Saudi Arabia

²Department of Pharmacology and Toxicology, Faculty of Pharmacy, Tanta University, Tanta, Egypt

³Department of Zoology, Faculty of Science, Tanta University, Tanta, Egypt

⁴Family and Community Medicine Department, College of Medicine, King Saud University, Riyadh, Saudi Arabia

⁵Department of Anatomy and Embryology, Faculty of Medicine, Tanta University, Tanta, Egypt

⁶Princess Nourah bint Abdulrahman University, Riyadh, Saudi Arabia

⁷Faculty of Medicine, Tanta University, Tanta, Egypt

⁸Department of Biochemistry, Faculty of Pharmacy, Al Azhar University, Cairo, Egypt

Abstract: Most clinical investigations about the impact of nanoparticles on cells and tissues show that nanoparticles may enter the human body by means of respiratory tracts. Humans, animals, plants and environments are continually presented to a wide scope of business items containing silver nanoparticles (Ag NPs) in their piece. Ag NPs, utilized in various consumer products as room showers, surface cleaners, wound dressings, food storage containers and many textiles. The current examination planned to explore the defensive role of Avenanthramide-C (Avns) contrary to the lung toxicity initiated by Ag NPs injection in rats. 40 male Wistar rats were separated into 4 groups (Gp1, control; Gp2, Avns; Gp3, Ag NPs; Gp4, Ag NPs+Avns). Current results revealed that; Ag NPs induced a significant depletion in RBCs count, hemoglobin, platelets counts and a significant increase in total WBCs, lung injury, cyclooxygenase-2 (COX2) and TNF α expressions as compared to control. Treatments of Ag NPs with Avenanthramide-C extract (Ag NPs+Avns) improved the lung structure and blood complete pictures as compared to Ag NPs group.

Keywords: Ag NPs, avenanthramide-C, lung, cyclooxygenase-2 and TNF α expressions.

INTRODUCTION

Nanotechnology in this decade has several applications in the drug delivery, food industry, hardware, diagnosis, beautifying agents, sports, and medication (Al-Suhaibani and El-Morshedi, 2014; Alotaibi *et al.*, 2020, 2021; El-Masry *et al.*, 2020). There is growing interest in understanding the toxicity of nanomaterials and their potential risk to the environment and human health. Silver nanoparticles (Ag NPs) are part of the developing nanotechnology and its nanoparticles in the range of 1 and 100 nanometers and it have extraordinary thermal, optical, and electrical properties (Tolaymat *et al.* 2010; Khan *et al.*, 2018; Altwaijry *et al.*, 2020). Ag NPs, one of the most notable nanomaterials, are routinely used in shopper items, for example, surface cleaners, room showers, toys, antimicrobial paints, home apparatuses (clothes washers, air and water channels), food stockpiling compartments and materials (Shehzad *et al.*, 2018; Khan *et al.*, 2018).

As an alternate to regular nanoparticles poisonousness medicines, novel medicines are being produced using the secondary plants metabolites (Tousson *et al.* 2018; El-Masry *et al.*, 2019, 2020a). Phytochemicals are biologically active compounds that found in natural

products that have protective properties and essential due to disadvantages of the current therapies (Abd-Eldaim *et al.*, 2019a, 2019b, 2021; Mutar *et al.*, 2020).

Oats, (*Avena sativa*), is a category of cereal grain and are rich in soluble fibers which benefit in depressing the levels of cholesterol and increased the beta-glucan content (Zhang *et al.*, 2020). Avenanthramides (anthranilic acid amides; Avns) are a group of phenolic alkaloids (polyphenols) found exclusively in oats, and it consist of conjugate of one of three phenylpropanoids and anthranilic acid (Emmons and Petersonm 2001; Koenig *et al.*, 2011). Recently, a number of studies demonstrate that; Avenanthramides have anti-oxidant, anti-inflammation, anti-proliferation, and vasodilator activities (Chu *et al.*, 2013; Aldubayan *et al.*, 2019).

Due to the increasing prevalence of Ag NPs in several consumer products (cosmetics, surface cleaners, toys, fabrics, foods storage container), the toxicity of Ag NPs in biological systems has been called into question. Small size of Ag NPs have a quicker release rate are extra toxic and when it combined together inhibit the immune functions (Altwaijry *et al.*, 2020). Silver ions released from Ag NPs ingested products into the blood stream can collect in different body organs revealed toxic effects (Cho *et al.*, 2018). Subsequently current examination expected to explore the defensive role of avenanthramides

*Corresponding author: e-mail: toussonehab@yahoo.com

against silver nanoparticles (Ag NPs) instigated lung injury in rats.

MATERIALS AND METHODS

Chemicals

Avenanthramides

Methyl ester of Avenanthramide-C (CAS number is 955382-52-2 and inventory number is CAY10011336; Ann Arbor, MI 48108, USA).

Silver nanoparticles

Silver nano-powder (Ag NPs) with main size between 30-40 nm and about 99.9% trace metals basis was gotten from Sigma - Aldrich Chemicals Company (Cairo, Egypt). According to Kim *et al.* (2010) Ag NPs should be sonicated for 10 minutes before used.

Animals and experimental design

All trial methods were affirmed by the Committee of Ethics in Faculty of Science, Tanta University, as supported by Institutional Animal Care and Use Committee (IACUC-SCI-TU-0185).

The animals were maintained on a commercial standard pellet diet and tap water *ad libitum*. After seven days of acclimation, healthy 40 rats (immature male Wistar, 100-110g weight and 8-9 weeks old) were separated into 4 groups [Gp 1 (Control) served as control; Gp 2 (Avns) in which rats were administered Avns by oral gavage (50ng/kg/day) for four weeks according to Aldubayan *et al.*(2019); Gp 3 (Ag NPs) in which rats were injected *intraperitoneally* (IP) with Ag NPs (100 mg/kg BW; <100 nm) for 4 weeks; Gp 4 (Ag NPs+Avns) was injected *IP* for 4 weeks with Ag NPs then treated for another 4 weeks with Avns].

Blood and tissue preparation

Toward the finish of the examination, the rats were abstained for 10-12 hours, and were anesthetized utilizing sodium pentobarbital and dismembered. Blood tests from independently rodent were gathered from vena-cava and accumulated in heparinised tubes for complete blood picture (CBC) examinations with automated hematology analyzer Sysmex (kx - 21n; JAPAN CARE CO., LTD).

Histopathological Examination

Fixed lung from various gatherings were prepared for paraffin sections, stained with haematoxylin and eosin for histological examination as indicated by Tousson (2016).

Immunohistochemical detection of TNF α and Cox-2

Detection of TNF α immunoreactivity (TNF α -ir) and Cyclooxygenase (COX)- 2 immunoreactivity in the fixed lung sections were distinguished utilizing the avidin Biotin Complex technique as indicated by El-Masry *et al.* (2020b) and Khan *et al.* (2012) respectively.

STATISTICAL ANALYSIS

Data were expressed as mean values \pm SE and statistical analysis was achieved using one way ANOVA to evaluate significant differences between treatment groups. The criterion for statistical significance was set at $p < 0.05$ for the biochemical data. All statistical analyses were performed using SPSS statistical (version 21; SPSS[®] Inc. - USA).

RESULTS

Animal symptoms, food consumption and general activity

Rats in all gatherings aside from Ag NPs bunch seemed solid, with no mortality, no clinical indications of sickness, or huge contrasts in food utilization or body weight during the investigation length (information not appeared). Conversely; Ag NPs gathering, uncovered observable decline in action.

Effect of Ag NPs and Avns on blood parameters

Table 1 showed the variations in CBC in all groups. Only WBCs counts was significantly increased while RBCs, Hb, HCT percent, MCV, MCH, MCHC and platelets were significantly decreased in Ag NPs group when compared to the control. On the other hand; a significant decrease in WBCs count and significant increase in RBCs, Hgb, HCT percent, MCV, MCH, MCHC and platelets after treatment of Ag NPs with Avns (table 1).

Impact of Ag NPs and Avns on lung histopathology

Lungs sections in control and Avns groups revealed normal spongy structure with typical alveoli, alveolar sacs, tinny and dense slices of interalveolar septa, bronchioles, and artery and viens (figs. 1A&1B). Lung segments in Ag NPs bunch indicated different histopathological changes as stamped alveolar injury as fallen alveoli, with severe dense and thickened interalveolar septa and checked invasion of incendiary cells notwithstanding solid blocked blood vessels (figs. 1C). Lung sections in treated Ag NPs with Avns revealed good improvement with only minimal alveolar injury (figs. 1D).

Impact of Ag NPs and Avns on TNF α

Faint positive reactions in interalveolar septa in both lung sections of the control and the rats treated with Avenanthramide-C (Avns) for TNF α (figs. 2A&2B). While; lung sections in Ag NPs group showed moderate to strong positive reactions for TNF α (fig. 2C). In contrast; faint to mild positive reactions for TNF α were detected after the treated with Ag NPs then Avns (fig. 2D).

Impact of Ag NPs and Avns on Cyclooxygenase 2

Faint positive reactions in inter-alveolar septa in both lung sections of the control and the rats treated with

Table 1: Changes in the CBC parameters in different groups.

Parameter	Groups			
	Control	Avns	Ag NPs	Ag NPs+Avns
RBCs ($10^6/ml$)	5.11 [#] ±0.16	5.23 [#] ±0.12	4.01*±0.11	4.76*±0.15
Hb (gm/dl)	12.86 [#] ±0.89	13.04 [#] ±0.92	11.91*±0.95	12.56*±0.81
HCT (%)	42.4 [#] ±2.33	43.0 [#] ±3.01	39.3*±1.64	41.4 [#] ±2.21
MCV (fl)	83.0 [#] ±3.35	82.2 [#] ±4.19	89.0*±3.38	88.7*±4.67
MCH (Pg)	25.2 [#] ±1.80	24.9 [#] ±1.65	29.7*±2.02	26.9*±1.48
PLT ($10^3/ml$)	498 [#] ±15.4	563 [#] ±21.0	316.0*±10.9	425 [#] ±18.5
WBCs ($10^3/ml$)	8.1 [#] ±0.44	8.47 [#] ±0.50	10.93*±0.63	8.01 [#] ±0.60

Values are expressed as means ± SE; n=10 for each treatment group; (*) & (#) significant 0.05 compared to control and to Ag NPs groups respectively.

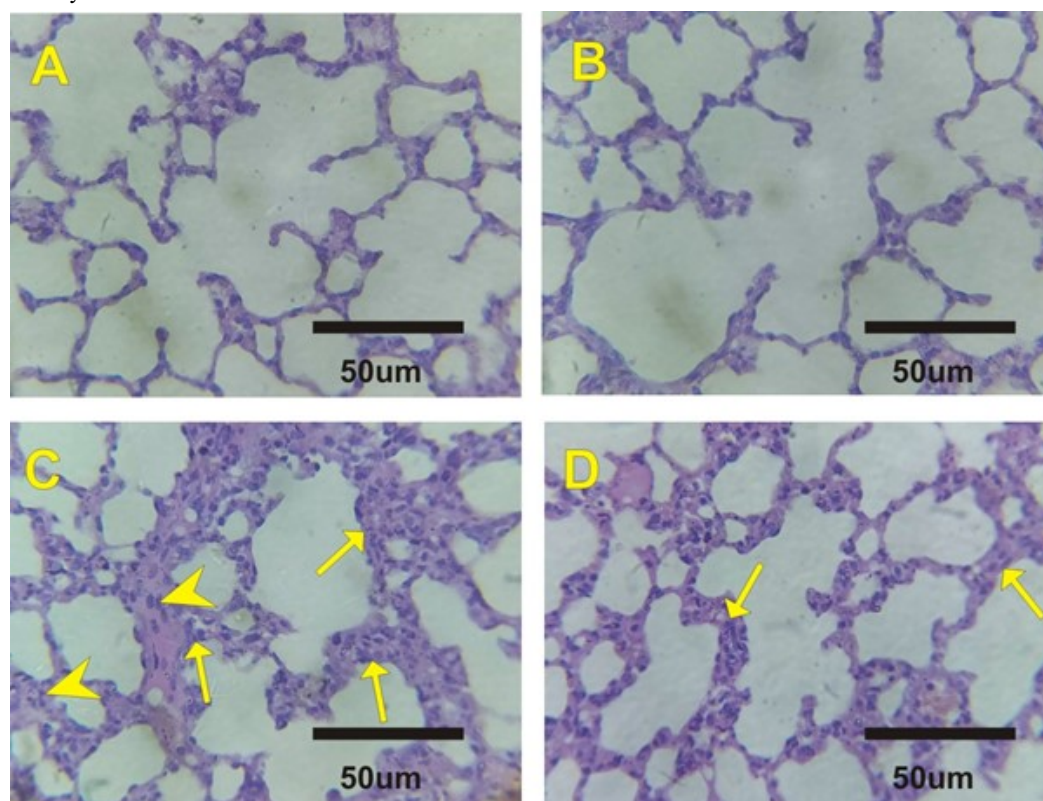


Fig. 1: Photomicrographs of lung sections in the different experimental groups stained with Hematoxylin & Eosin. A&B: Lung sections in the control and Avns groups revealed normal spongy structure with normal alveoli and alveolar sacs. C: Lung sections in Ag NPs group revealed marked alveolar damage in the form of collapsed alveoli, with marked thickened interalveolar septa (arrows) and marked infiltration of inflammatory cells (arrow heads). D: Lung sections in treated Ag NPs with Avns revealed mild alveolar damage and evident reduction of all alveolar changes except for few thickening of interalveolar septa (arrows).

Avenanthramide-C (Avns) for Cox2 expressions (figs. 3A&3B). While; moderate positive reactions for Cox2 were observed in Ag NPs group (fig. 3C). In contrast; faint positive reactions for Cox2 expressions were detected after the treated with Ag NPs then Avns (fig. 3D).

DISCUSSION

Nanoparticles (NPs) have come to be frequent components of broad range products such as textiles,

detergents, private care products, washing machines, refrigerators, etc (Barbir *et al.*, 2019). Albeit little data in regards to the natural toxicology impacts and toxicological impacts of nanomaterials is accessible, be that as it may, it is anticipated due to physico - compound properties of nanomaterials that they may have communication with organic parts and may affect the conduct and properties of macromolecules, cells and living organisms. Silver nanoparticles (Ag NPs) lack biocompatibility inside the body, in order to overcome this problem, Ag NPs were used in this study.

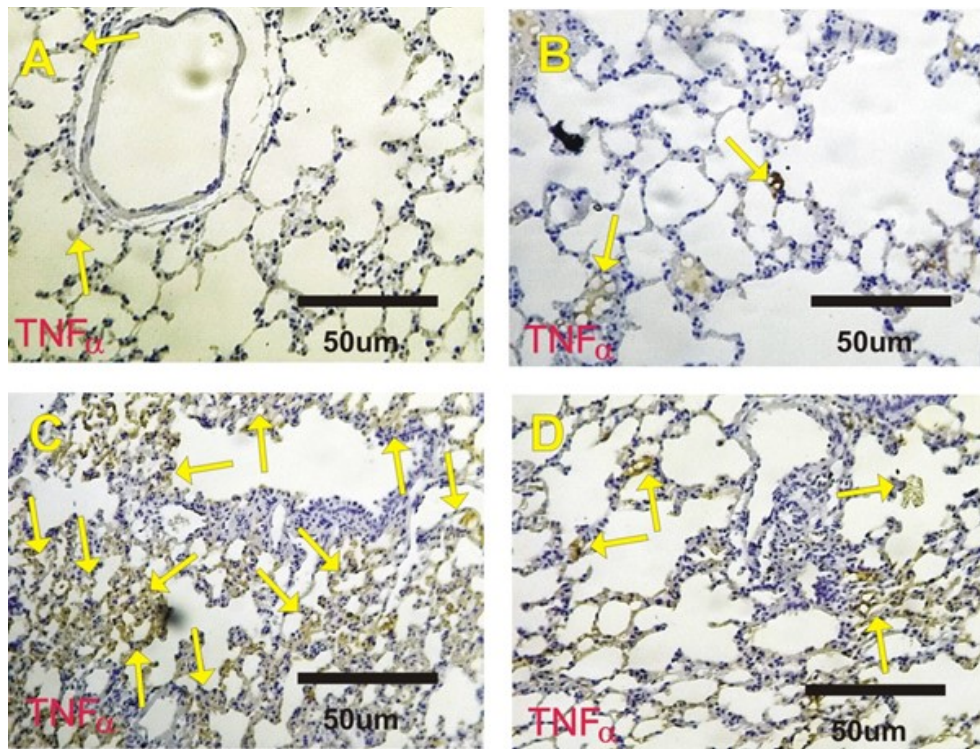


Fig. 2: Photomicrographs of rat lung sections stained with TNF α . A&B: faint positive reactions for TNF α expression (arrows) in interalveolar septa in control and Avns groups. C: Strong positive reactions for TNF α expression (arrows) in the interalveolar septa in treated rat with Ag NPs. D: Mild positive reactions for TNF α (arrows) in interalveolar septa in Ag NPs+Avns.

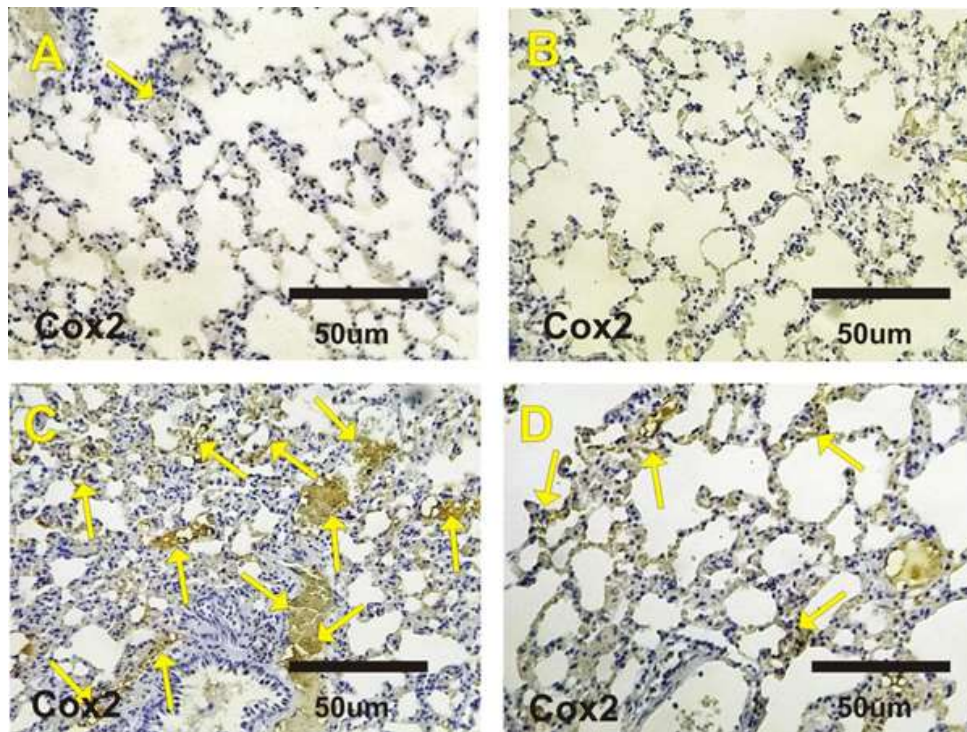


Fig. 3: Photomicrographs of rat lung sections stained with Cyclooxygenase 2 (Cox2). A&B: Negative or faint positive reactions for Cox2 expression (arrows) in interalveolar septa in control and Avns groups. C: Moderate to strong positive reactions for Cox2 expression (arrows) in the interalveolar septa in treated rat with Ag NPs. D: Mild positive reactions for Cox2 (arrows) in interalveolar septa in Ag NPs+Avns.

The role of the natural antioxidant from plants on cell damage has been noted by many pharmacological studies in recent past (Salama *et al.* 2014; Tousson *et al.* 2018). Oats, perhaps the most generally devoured entire grain oats, stand out on the grounds that they are wealthy in phenolic mixes (Peterson, 2001). The phenolic mixes in oats comprise of straightforward flavonoids, phenolic acids, and avenanthramides (Chu *et al.*, 2013; Aldubayan *et al.*, 2019). In any case, little is referred to about home grown plants as defensive specialists against Ag NPs actuated lung poisonousness. This examination was intended to analyze the conceivable defensive impacts of Avenanthramide-C (Avns) against lung harm by Ag NPs on male rat.

The obtained results in this study indicated that; Ag NPs injection in rats induced changes in the got brings about this examination demonstrated that; Ag NPs infusion in rodents prompted changes in blood total pictures as height of leucocyte includes and exhaustion in hemoglobin, red platelets tallies and platelets whenever contrasted with control gathering. The diminishing in RBC and Hb on the grounds that those RBCs were gotten from hemopoietic foundational micro organisms in bone marrow. Following a progression of development steps, coordinated primarily by erythropoietin, red cells enucleate and enter the circulatory framework, in this manner, the variety in RBCs can be identified with the hematopoietic system.

Little is referred to about the destiny of nanoparticles as silver nanoparticles that enter the lungs, either intentionally through clinical medicines or by chance through air contamination and word related openness in the work environment. In this work, the neurotic injuries as solid alveolar harm as imploded alveoli, thickened interalveolar septa with hefty invasion of incendiary cells and clogged blood vessels with extra vasation of red platelets inside the alveolar lumen were chiefly showed in the rodent lung after Ag NPs intraperitoneal infusion. Our outcomes concur with Vasanth and Kurian (2017) who revealed that silver nanoparticles initiated lung injury in various test models.

Inflammation is related with expanded favorable to incendiary cytokine creation, which could happen in both initiated leukocytes and harmed muscle cells (Proske and Allen, 2005). TNF α is type of proinflammatory cytokine that represent as antitumorigenic and mainly produced by immune cells for example macrophages and lymphocytes. Current results revealed that; TNF α immunoreactivity were increased in lung tissues after Ag NPs injection and the treatment of Ag NPs with Avns inhibited the increased of TNF α immunoreactivity. The high expression of TNF α in lung after Ag NPs injection because that oxidative stress caused by Fe₃O₄/AgNPs enhances TNF- α production.

Our outcomes concur with Nounou *et al.* (2013) who detailed that oral openness to zinc oxide nanoparticles actuated lung harm, aggravation and stamped expanded in TNF α immunore activity in rodent's lung. In the current investigation Avns supplementation upgrade of alveolar harm actuated by Ag NPs, and will be of significant premium to be utilized as an adjuvant treatment under these conditions. Our results in line of Guo *et al.* (2008) detailed that the inhibitory impact of AVA on the statement of proinflammatory cytokines was interceded through NF κ B actuation in HAEC. Our findings concur with Sur *et al.* (2008) who detailed that also avenanthramides, display calming action. Cyclooxygenase-2 (COX-2) is up-managed in aspiratory conduit smooth muscle cells and incendiary cells during hypoxia and assumes a defensive job in the lung's reaction to hypoxia (Fredenburgh *et al.*, 2009). Current results revealed that; COX-2 immunoreactivity were increased in lung tissues after Ag NPs injection and the treatment of Ag NPs with Avns inhibited the increased of COX-2 immunore activity. Our outcomes concur with Lim and Kang (2020) who detailed that; Avenanthramide C stifles hypoxia-instigated cyclooxygenase-2 (COX-2) expression through sirtuin1 actuation in non-little cell cellular breakdown in the lungs cells. This restraint of TNF α and COX-2 most likely adds to the calming and chemo preventive properties of avenanthramide.

CONCLUSION

Silver nanoparticles induced lung injury, in addition to changes in complete blood pictures, alteration in Cyclooxygenase-2 and TNF α immunoreactivity. Treatments with Avenanthramide-C extract might offer benefits against the toxic nature of silver nanoparticles (AgNPs) especially in lung.

ACKNOWLEDGEMENTS

This work was funded by DSR (Deanship of Scientific Research), Princess Nourah bint Abdulrahman University, Riyadh, Saudi Arabia, under grant RGP-1440-0022. The authors therefore, gratefully acknowledge the DSR technical and financial support.

REFERENCES

- Abd Eldaim MA, Tousson E, El Sayed IE and Awd WM (2019a). Ameliorative effects of *Saussurea lappa* root aqueous extract against Ethephon-induced reproductive toxicity in male rats. *Environ. Toxicol*, **34**(2): 150-159.
- Abd Eldaim MA, Tousson E, El Sayed IE, Abd Elmaksoud AZ and Ahmed AA (2021). Ameliorative effects of 9-diaminoacridine derivative against Ehrlich ascites carcinoma-induced hepatorenal injury in mice. *Environ. Sci. Pollut. Res.*, doi: 10.1007/s11356-020-11857-y.

- Abd Eldaim MA, Tousson E, El Sayed IE, El AE and Elsharkawy HN (2019b). Grape seeds proanthocyanidin extract ameliorates Ehrlich solid tumor induced renal tissue and DNA damage in mice. *Biomed. Pharmacother.*, **115**:108908.
- AlDubayan MA, Elgharabawy RM, Ahmed AS and Tousson E (2019). Antineoplastic activity and curative role of avenanthramides against the growth of Ehrlich solid tumors in mice. *Oxid. Med. Cell Longev.*, **2019**; 5162687.
- Alotaibi B, Tousson E, El-Masry TA, Altwaijry N and Saleh A (2021). Ehrlich ascites carcinoma as model for studying the cardiac protective effects of curcumin nanoparticles against cardiac damage in female mice. *Environ. Toxicol.*, **36**(1): 105-13.
- Alotaibi B, El-Masry TA, Tousson E, Alarfaj SJ and Saleh A (2020). Therapeutic effect of rocket seeds (*Eruca sativa* L.) against hydroxyapatite nanoparticles injection induced cardiac toxicity in rats. *Pak. J. Pharm. Sci.*, **33**(4 Suppl): 1839-1845.
- Al-Suhaibani ES and El-Morshedi NA (2014). Histopathological and ultrastructural effect of zinc oxide nanoparticles on male wistar rats submandibular glands. *IOSR J. Pharm. Biol. Sci.*, **9**(6): 05-9.
- Altwaijry N, El-Masry TA, Alotaibi B, Tousson E and Saleh A (2020). Therapeutic effects of rocket seeds (*Eruca sativa* L.) against testicular toxicity and oxidative stress caused by silver nanoparticles injection in rats. *Environ. Toxicol.*, **35**(9): 952-960
- Barbir R, Goessler W, Curlin M, Micek V, Milic M, Vukovic B, Milic M, Ljubojevic M, Domazet Jurasin D and Vinkovic Vreck I (2019). Protein corona modulates distribution and toxicological effects of silver nanoparticles *in vivo*. *Part. Part. Syst. Char.*, **36**(8): 1900174.
- Cho YM, Mizuta Y, Akagi JI, Toyoda T, Sone M and Ogawa K (2018). Size-dependent acute toxicity of silver nanoparticles in mice. *J. Toxicol. Pathol.*, **31**(1): 73-80.
- Chu YF, Wise ML, Gulvady AA, Chang T and Kendra DF, Van Klinken BJ, Shi Y and O'Shea M (2013). *In vitro* antioxidant capacity and anti-inflammatory activity of seven common oats. *Food Chem.*, **139**(1-4): 426-431.
- El-Masry T, Al-Shaalan N, Tousson E, Buabeid M and Al-Ghadeer A (2020). Potential therapy of vitamin B17 against Ehrlich solid tumor induced changes in Interferon gamma, Nuclear factor kappa B, DNA fragmentation, p53, Bcl2, survivin, VEGF and TNF- α Expressions in mice. *Pak. J. Pharm. Sci.*, **33**(1): 393-401.
- El-Masry TA, Al-Shaalan NH, Tousson E, Buabeid M and Alyousef AM (2019). The therapeutic and antineoplastic effects of vitamin B17 against the growth of solid-form Ehrlich tumours and the associated changes in oxidative stress, DNA damage, apoptosis and proliferation in mice. *Pak. J. Pharm. Sci.*, **32**(6): 2801-2810.
- El-Masry TA, Altwaijry N, Alotaibi B, Tousson E, Alboghdady A and Saleh A (2020). Chicory (*Cichorium intybus* L.) extract ameliorates hydroxyapatite nanoparticles induced kidney damage in rats. *Pak. J. Pharm. Sci.*, **33**(3): 1251-1260.
- Emmons CL and Peterson DM (2001). Antioxidant activity and phenolic content of oat as affected by cultivar and location. *Crop Sci.*, **41**: 1678-1681.
- Fredenburgh LE, Ma J and Perrella MA (2009). Cyclooxygenase-2 inhibition and hypoxia-induced pulmonary hypertension: Effects on pulmonary vascular remodeling and contractility. *Trends Cardiovas. Med.*, **19**(2): 31-37.
- Guo W, Wise ML, Collins FW and Meydani M (2008). Avenanthramides, polyphenols from oats, inhibit IL-1 β -induced NF- κ B activation in endothelial cells. *Free Radic. Biol. Med.*, **44**: 415-29.
- Khan AQ, Khan R, Rehman MU, Lateef A, Tahir M, Ali F and Sultana S (2012). Soy isoflavones (daidzein & genistein) inhibit 12-O-tetradecanoylphorbol-13-acetate (TPA)-induced cutaneous inflammation via modulation of COX-2 and NF- κ B in Swiss albino mice. *Toxicology*, **302**(2-3): 266-274.
- Khan SU, Saleh TA, Wahab A, Khan MH, Khan D, Khan WU, Rahim A, Kamal S, Khan FU and Fahad S (2018). Nanosilver: New ageless and versatile biomedical therapeutic scaffold. *Int. J. Nanomedicine*, **13**: 733.
- Kim YS, Song MY, Park JD, Song KS, Ryu HR and Chung YH (2010). Subchronic oral toxicity of silver nanoparticles. *Part Fibre Toxicol.*, **7**(1): 20
- Koenig RT, Dickman JR, Wise ML and Ji LL (2011). Avenanthramides are bioavailable and accumulate in hepatic, cardiac and skeletal muscle tissue following oral gavage in rats. *J. Agric. Food Chem.*, **59**(12): 6438-6443.
- Lim W and Kang C (2020). Avenanthramide C suppresses hypoxia-induced cyclooxygenase-2 expression through sirtuin1 activation in non-small-cell lung cancer cells. *Anim. Cells Syst.*, **24**(2): 79-83.
- Mutar TF, Tousson E, Hafez E, Gazia MA and Salem SB (2020). Ameliorative effects of vitamin B17 on the kidney against Ehrlich ascites carcinoma induced renal toxicity in mice. *Environ. Toxicol.*, **35**(4):528-537.
- Nounou H, Attia H, Shalaby M and Arafah M (2013). Oral exposure to zinc oxide nanoparticles induced oxidative damage, inflammation and genotoxicity in rat's lung. *Life Sci. J.*, **10**: 1.
- Peterson DM (2001). Oat antioxidants. *J. Cereal Sci.*, **33**(1): 115-129.
- Proske U and Allen TJ (2005). Damage to skeletal muscle from eccentric exercise. *Exerc. Sport Sci. Rev.*, **33**(1): 98-104.
- Salama AF, Tousson E, Shalaby KA and Hussien HT (2014). Protective effect of curcumin on chloroform as by-product of water chlorination induced cardiotoxicity. *Biomed. Prev. Nutr.*, **4**(2): 225-230.

- Shehzad A, Qureshi M, Jabeen S, Ahmad R, Alabdall AH, Aljafary MA and Al-Suhaimi E (2018). Synthesis, characterization and antibacterial activity of silver nanoparticles using *Rhazya stricta*. *Pee J.*, **6**: e6086.
- Sur R, Nigam A, Grote D, Liebel F and Southall MD (2008). Avenanthramides, polyphenols from oats, exhibit anti-inflammatory and anti-itch activity. *Arch. Dermatol. Res.*, **300**(10): 569.
- Tolaymat TM, El Badawy AM, Genaidy A, Scheckel KG, Luxton TP and Suidan M (2010). An evidence-based environmental perspective of manufactured silver nanoparticle in syntheses and applications: A systematic review and critical appraisal of peer-reviewed scientific papers. *Sci. Total. Environ.*, **408**(5): 999-1006.
- Tousson E (2016). Histopathological alterations after a growth promoter boldenone injection in rabbits. *Toxicol. Ind. Health*, **32**(2): 299-305.
- Tousson E, Bayomy MF and Ahmed AA (2018). Rosemary extract modulates fertility potential, DNA fragmentation, injury, KI67 and P53 alterations induced by etoposide in rat testes. *Biomed. Pharmacother.*, **98**(2): 769-774.
- Tousson E, Hafez E, Zaki S and Gad A (2016). The cardioprotective effects of L-carnitine on rat cardiac injury, apoptosis and oxidative stress caused by amethopterin. *Environ Sci. Pollut. Res.*, **23**: 20600-20608
- Vasanth SB and Kurian GA (2017). Toxicity evaluation of silver nanoparticles synthesized by chemical and green route in different experimental models. *Artif. Cells Nanomed. Biotechnol.*, **45**(8): 1721-1727.
- Zhang Y, Ni T, Zhang D, Liu H, Wang J and Sun B (2020). Consumption of avenanthramides extracted from oats reduces weight gain, oxidative stress, inflammation and regulates intestinal microflora in high fat diet-induced mice. *J. Funct. Foods*, **65**: e103774.