

Hepatotoxicity induced by chronic suppurative otitis media in rats and effects of ceftazidime and amikacin on it

Shafaque Mehboob^{1*}, Darakhshan M Saleem², Mehjabeen³, Moona Mehboob⁴, Noor Jahan⁵, Shaheen Perveen⁶, SM Tariq Rafi⁷, Humaira Anser⁸ and Farah Owais⁹

¹Department of Pharmaceutical Chemistry, Institute of Pharmaceutical sciences, Jinnah Sindh Medical University, Karachi, Pakistan

²Biomedical Engineering Department, Sir Syed University of Engineering & Technology, Karachi, Karachi, Pakistan

^{3,9}Department of Pharmacology, Faculty of Pharmaceutical Sciences, Federal Urdu University of Arts, Science and Technology, Karachi, Pakistan

⁴Department of Pharmaceutical Chemistry, School of Pharmacy, Dow University of Health Science, Karachi, Pakistan

⁵Department of Pharmacology, School of Pharmacy, Dow University of Health Science, Karachi, Pakistan

⁶Department of Pharmaceutics, Institute of Pharmaceutical Sciences, Jinnah Sindh Medical University, Karachi, Pakistan

⁷Department of ENT, Jinnah Sindh Medical University, Karachi, Pakistan

⁸Department of Pharmacology, Institute of Pharmaceutical Sciences, Jinnah Sindh Medical University, Karachi, Pakistan

Abstract: Chronic suppurative otitis media (CSOM) is the chronic inflammation with perforation of middle ear. If CSOM is not treated, it may cause secondary inflammation of liver with elevated liver enzymes and histological changes. Present study is aimed to observe the hepatotoxic effects due chronic suppurative otitis media (CSOM) in CSOM induced rats and also to observe the effects of ceftazidime and amikacin to attenuate hepatotoxicity due to CSOM. Liver enzyme tests and histological examinations were performed on rats divided into different groups as G1 (negative control), G2 (positive control), G3 ceftazidime (15mg/kg intraperitoneally) and G4 amikacin (15mg/kg). One-way ANOVA showed that liver enzymes were significantly increased ($p=0.000$ and F value 6.899) except gamma glutamic transferase in G2 (rats with CSOM without treatment) from G1 (negative control without CSOM) with histological damage of liver. These hepatotoxic effects were attenuated or recover with proper treatment with potent antibiotics (ceftazidime and amikacin). Therefore, study showed that chronic suppurative otitis media can induce hepatic toxicity including elevated liver enzymes level and inflammation, aggregation or infiltration in liver cells in rat model with reversible hepatic damage. If CSOM is treated with adult dose of ceftazidime or amikacin, it may attenuate the damage and prevent risk of liver damage.

Keywords: Chronic suppurative otitis media, hepatotoxicity, ceftazidime, amikacin

INTRODUCTION

Liver is responsible for the detoxification and metabolism of several chemicals and drugs from the body (Mohsen *et al.*, 2017). Chronic inflammation, infection and oxidative stress are leading reasons of hepatic toxicity. Untreated infections of a body part may cause secondary infection of liver. It is usually conducted to have understanding of different injuries or diseases related to the hepatic enzymes alteration and in certain condition, the abnormal levels of transaminases with the altered levels of alkaline phosphates and gamma transpeptidase may present the condition of the inflammation, toxicity or injury of liver. Therefore, it may present the infection of another organ (Edoardo *et al.*, 2005). Present study is aimed to observe the hepatotoxic effects due to chronic suppurative otitis media (CSOM) in CSOM induced rats.

Chronic suppurative otitis media is a chronic infection with inflammation of middle ear infection. This is usually associated with middle ear perforation, hearing loss with otalgia and otorrhea (ear discharge) (Nwabuisi and Ologe,

2002). World health organization (WHO) reported that global prevalence of chronic suppurative otitis media is about 65 to 330 million in a year and estimated prevalence rate of CSOM in south East Asia is 5.2% which makes this area included among the highly prevalent (Iqbal *et al.*; 2009). In Pakistan, the most frequent organism (*Pseudomonas aeruginosa*) found to be the most sensitive by amikacin but also with ceftazidime and ciprofloxacin (Manssor *et al.*, 2009). However, amikacin or ceftazidime may cause minor hearing loss, therefore, it should be used with precaution (Brown *et al.*, 1989). The present study also aimed to observe the recovered effects on hepatotoxicity due to CSOM (if any) after treatment with ceftazidime and amikacin in CSOM induced rats.

MATERIAL AND METHODS

Animals

Rats (male Sprague-dawley) with average weight 191.5g \pm 12 were purchased (Dow University of health sciences). Animals were locally bred and kept under 12 hour light dark cycle at 22 \pm 2°C. NIH recommendations for the Care

*Corresponding author: e-mail: shafaque.mehboob@hotmail.com

and Use of Laboratory Animals were followed. Rats were randomly selected to serve any group (Saleem *et al.*; 2018).

Dosing protocol

Liver enzyme tests and histological examinations were performed on rats divided into different groups as G1 (negative control), G2 (positive control), G3 (ceftazidime (15mg/kg intraperitoneally), and G4 (amikacin (15mg/kg intraperitoneally)). G2 was left untreated while G3 and G4 were treated with antibiotics (ceftazidime and amikacin) for one week after two weeks of CSOM induction. For the induction of CSOM, rats were given anaesthesia with ketamine (100mg/kg) with diazepam (0.1mg/kg intraperitoneally) followed by inoculation of 0.04ml of 6.4×10^7 CFU of *Pseudomonas aeruginosa* into the ear (tympanic bulla) (Trinidad *et al.*, 2005; Bhutta *et al.*, 2012).

Estimation of liver enzymes

Liver function tests (direct bilirubin, total bilirubin, alkaline phosphatase, aspartate aminotransferase, gamma glutamyl transferase) were performed in the serum of the rats.

Test Principle for estimation of direct bilirubin

A stabilized diazonium salt, 3, 5 Dichlorophenyl diazonium tetrafluoroborate (DPD) couples directly with direct (conjugated) bilirubin in an acid medium to form azobilirubin. The absorbance at 570 nm is proportional to the direct bilirubin concentration in the sample.

Test Principle for estimation of total bilirubin

A stabilized diazonium salt, 3, 5-dichlorophenyl-diazonium tetrafluoroborate (DPD), reacts with conjugated bilirubin directly and with unconjugated bilirubin in the presence of an accelerator to form azobilirubin. The absorbance can be detected at 540 nm.

Test Principle for estimation of ALP

Alkaline phosphatase activity is determined by measuring the rate of conversion of p-nitro-phenylphosphate (pNPP) to p-nitrophenol (pNP) in the presence of magnesium and zinc ions and of 2-amino-2-methyl-1-propanol (AMP) as phosphate acceptor at pH 10.4. The rate of change in absorbance due to the formation of pNP is measured bichromatically at 410/480 nm and is directly proportional to the ALP activity in the sample.

Test Principle for estimation of ALT

This method was also based on the recommendations of the "International Federation for Clinical Chemistry" (IFCC). Pyruvate and glutamate are produced when ALT transport amino group from alanine to 2-oxoglutarate. Pyridoxal phosphate catalyzes the reaction and NAD^+ is formed when pyruvate enters a lactate dehydrogenase (LDH). The absorbance is taken at 340 nm.

Test principle for estimation of GGT

GGT catalyses the transfer of the gamma-glutamyl group from the substrate, gamma-glutamyl-3-carboxy-4-nitroanilide, to glycylglycine, yielding 5-amino-2-nitrobenzoate. The absorbance can be detected at 410/480 nm after formation of 5-amino-2-nitrobenzoate (Moss and Henderson, 1999; Schumann *et al.*; 2002).

Histopathological examination of liver

Liver samples collection of rats

At the end of the experiment, the rats were anesthetized, dissected and liver was excised immediately. This procedure followed the preservation of liver in 10% formalin, then in formalin wax which were further stained using hematoxyline and eosin stain. Histopathological examination was done to observe cellular pattern, sign of inflammation, infiltration or necrosis (Alharthi *et al.*, 2019).

STATISTICAL ANALYSIS

Results are presented as mean \pm SD. One way ANOVA was applied for liver enzymes analysis and group comparisons (Post Hoc) were done by Tukey's test ($p \geq 0.05$).

RESULTS

Estimation of liver enzymes

Liver enzymes and chemical such as total bilirubin, direct bilirubin, serum glutamic pyruvic transaminase, alkaline phosphatase and gamma glutamic transferase were estimated in CSOM induced rats. The effects of CSOM on liver enzyme tests was obtained significant when one-way ANOVA was applied with p value 0.000 and F value 6.899.

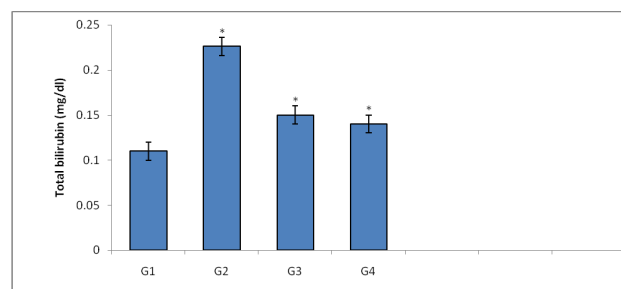


Fig. 1: Total bilirubin concentration (mg/dl) in G1 (negative control), G2 (positive control), G3 (ceftazidime treated) and G4 (amikacin treated).

Fig. 1-5 show significant increase ($p < 0.05$) in total bilirubin, direct bilirubin, serum glutamic pyruvic transaminase, alkaline phosphatase but not in gamma glutamic transferase in G2 (rats with CSOM without treatment) from G1 (negative control without CSOM) but not in gamma glutamic transferase.

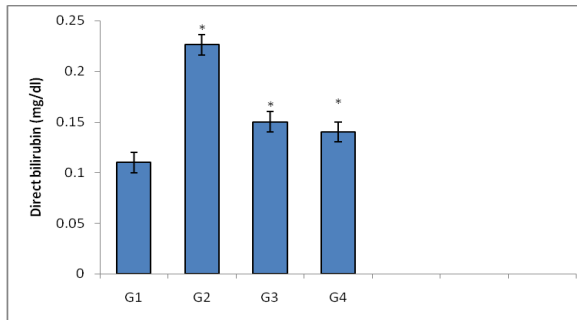


Fig. 2: Direct bilirubin concentration (mg/dl) in G1 (negative control), G2 (positive control), G3 (ceftazidime treated) and G4 (amikacin treated).

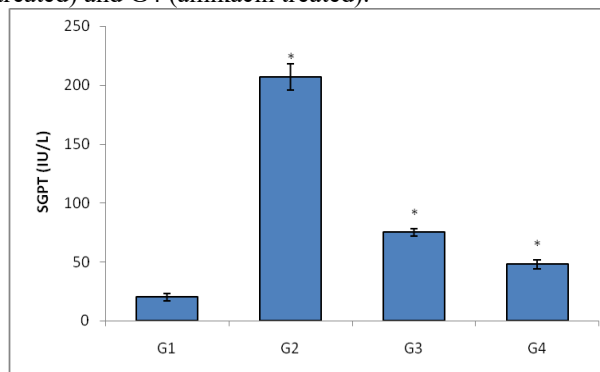


Fig. 3: SGPT concentration (IU/L) in G1 (negative control), G2 (positive control), G3 (ceftazidime treated) and G4 (amikacin treated).

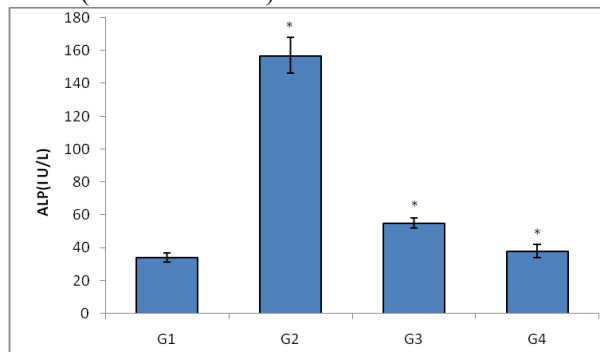


Fig. 4: ALP concentration (IU/L) in G1 (negative control), G2 (positive control), G3 (ceftazidime treated) and G4 (amikacin treated).

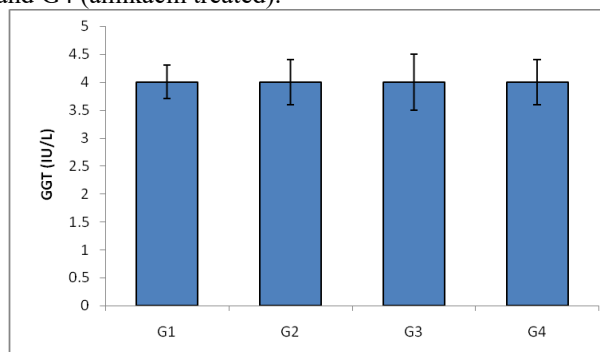


Fig. 5: GGT concentration (IU/L) in G1 (negative control), G2 (positive control), G3 (ceftazidime treated) and G4 (amikacin treated).

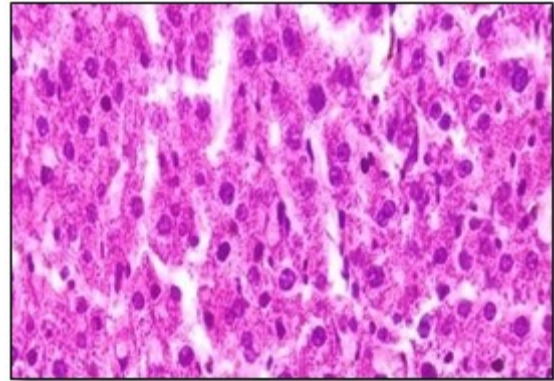


Fig. 6: G1 (negative control with normal hepatocytes)

These figs. also show that there was significant decrease ($p < 0.05$) in liver enzymes in treated groups of G3 (ceftazidime) and G4 (amikacin) from positive control of G2 (rats with CSOM without treatment) but insignificant difference from negative control of G1 (healthy rats).

Histopathological examination of liver

In order to evaluate the hepatotoxic effects of chronic suppurative otitis media (CSOM) infection in rats, not only liver function tests were conducted but histopathological studies were also performed. Fig. 7 presented normal pattern of hepatocytes with normal nucleus without aggregation and any inflammation or infiltration of monocytes of G1 (negative control). However, liver of the rat of G2 (positive control with CSOM infection without any treatment) showed toxicological effects of CSOM infection at hepatic level. Aggregation, inflammation and infiltration can be seen in fig. 7. In addition to this, dilation of the vessels showed worse condition of hepatic inflammation.

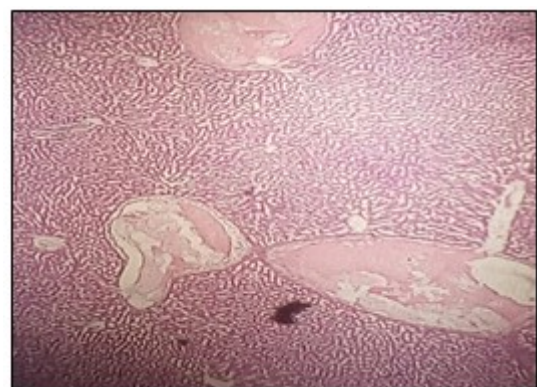


Fig. 7: G2 (Hepatocytes of rats with CSOM without treatment).

G3 (ceftazidime) and amikacin (G4) showed little bit better pattern as compared to the positive control but poorer than negative control. These groups showed approximately the same pattern of inflammation with aggregation (figs. 8 and 9).

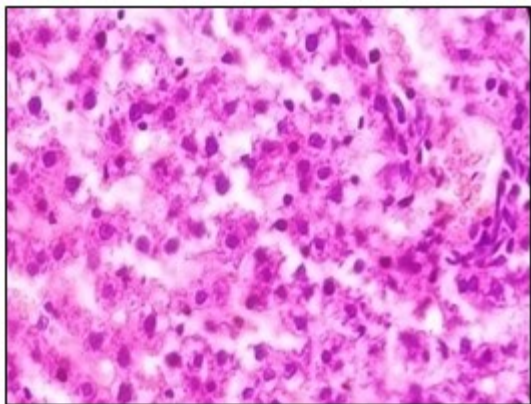


Fig. 8: G4 (Hepatocytes of rats when treated with ceftazidime)

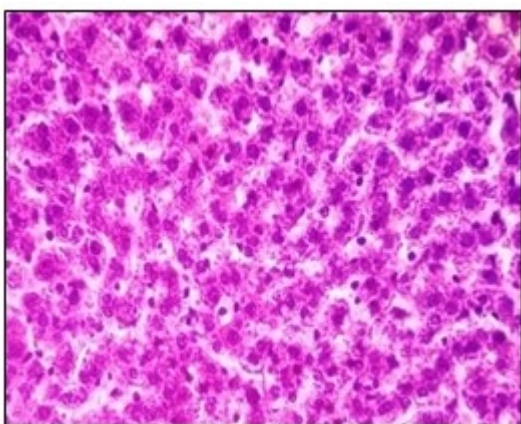

Fig. 9: G4 (Hepatocytes of rats when treated with amikacin)

DISCUSSION

Liver function test is usually conducted to understand different injuries or diseases related to the hepatic enzymes alteration which is usually of two types. One is hepatocellular predominant and the second is cholestatic predominant. Although in certain condition, the abnormal levels of transaminases with the altered levels of alkaline phosphates and gamma transpeptidase may present the consequences of the inflammation, toxicity or injury of liver or another organ (Edoardo *et al*, 2005).

In the present study, direct as well as total bilirubin, direct bilirubin, SGPT and ALP were significantly ($p < 0.05$) high in diseased group without any treatment (G2) as compared to the healthy rats (G1). This indicated the risk of hepatic inflammation or injury in the positive group suffering from infection without treatment (G2). On the other hand, ceftazidime and amikacin treated groups (G3 and G4) showed significant decrease ($p < 0.05$) from group without any treatment (G2) but insignificant ($p > 0.05$) difference from healthy rats (G1). There was no change in GGT levels among all the groups (G1, G2, G3 and G4).

Bilirubin levels provide information about risk status of liver. It is a product of form hemoglobin and its elevated levels shows the condition of hyperbilirubinemia or hypobilirubinea in conjugated or unconjugated form in different clinical presentations such as ineffective erythropoiesis, large hematomas or alcoholic liver disease (Feverly *et al*, 1986; Bosma *et al*, 1995). Immune markers which are reported to be altered in chronic infections such as IgE, IL6, IL8 and tumor necrosis factor are also reported to be involved in hepatitis, liver cirrhosis and other hepatic diseases (González-Quintela *et al*, 1999).

The biochemical abnormalities regarding amino-transferase levels may be due to chronic suppurative otitis media. As literature shows that a number of infection conditions such as ischemic injury, toxic injury, acute viral hepatitis, acute biliary obstruction or alcoholic and non-alcoholic fatty liver disease may cause increased ALP (Maria and Victorino, 1997; Aithal *et al*, 2000).

The determination of alkaline phosphatase (ALP) occupies very important place in the diagnosis of hepatic dysfunction along with the serum concentration of gamma glutamyl transpeptidase. It is also involved in the elevation of inflammatory markers (Ghosh *et al*, 2014) and toll like receptors. In the current study, only G2 group represented abnormal (significantly higher than normal values of G1) values, presented the high risk of liver inflammation, cholestasis or toxicity only in G1 group (Bilski *et al*, 2017; Molnár *et al*, 2019).

Gamma glutamyl transpeptidase is less specific for liver injury due to its presence in other tissues and organs but it is highly sensitive for liver or infection, particularly with altered biochemical markers of liver. It presented the overall status of the liver function its unchanged level shows that there was no irreversible changes or damage at hepatic level due to CSOM (Betro *et al*, 1973; Lum and Gambino, 1972).

Focal inflammation of the hepatic cells may present one or more aggregates of inflammatory cells which is developed during the chronic inflammation of liver or other body organ (Hall *et al*, 1992).

The elevated inflammatory markers or components of the immune system may lead to the inflammation, necrosis and even apoptosis or fibrogenesis of liver cells (Cohen-Naftaly and Friedman, 2011; Safadi *et al*, 2004; Hintermann, 2013).

In the presented study, high IgE and other cytokines may contribute to create high risk for autoimmune hepatitis (Oliveira *et al*, 2015, Mehboob *et al*, 2020).

In the current study, G1 of healthy rats without CSOM showed normal histopathological condition of hepatic

cells without any sign of inflammation (absence of neutrophils, macrophages or lymphocytes), edema, hyperemia, necrosis or apoptosis.

On the other hands, the group G2 with CSOM but without any treatment showed a little changed histological view with peripheral inflammation (with altered hepatic enzyme and cytokines concentration). The presence of the inflamed cells makes the liver condition susceptible for liver injury or infiltration of immune cells. No sign of predominance of plasma cells in portal infiltrate was observed. Centrilobular injury with the sign of hepatocellular necrosis was also absent.

Both of the treated groups (from G3 and G4) showed normal pattern of the cells with very little inflammation signs. It seemed that the antibiotics (ceftazidime and amikacin) revert the inflammation particularly around portal vein due to CSOM in the rats at hepatic level too (along with the decrease of IgE and cytokines concentration with the normalization of hepatic enzyme levels).

The hepatic inflammation with abnormal liver function test and elevated cytokines levels with altered IgE concentrations may present the early stage of hepatic injury due to CSOM induced in the rats which is reversible. These results are supported by the reported literature indicating the autoimmune hepatitis after the chronic infection of the liver or any other organ with altered immune system markers concentrations (Hall *et al.*, 1992)

CONCLUSION

Present study showed that chronic suppurative otitis media can induce hepatic toxicity including elevated liver enzymes level and inflammation, aggregation or infiltration in liver cells in rat model with reversible hepatic damage. If CSOM is treated with adult dose of ceftazidime or amikacin, it may attenuate and prevent risk of liver damage.

REFERENCES

Aithal GP, Rawlins MD and Day CP (2000). Clinical diagnostic scale: A useful tool in the evaluation of suspected hepatotoxic adverse drug reactions. *J. Hepatol.*, **33**(6): 949-52.

Alharthi WA, Hamza RZ, Elmahdi MM, Abuelzahab HS and Saleh H (2020). Selenium and L-carnitine ameliorate reproductive toxicity induced by cadmium in male mice. *Biol. Trace Elem. Res.*, **197**(2): 619-627.

Betro MG, Oon RC and Edwards JB (1973). Gamma-glutamyl transpeptidase in diseases of the liver and bone. *Am. J. Clin. Pathol.*, **60**(5): 672-678.

Bilski J, Mazur-Bialy A, Wojcik D, Zahradnik-Bilska J, Brzozowski B, Magierowski M, Mach T, Magierowska K and Brzozowski T (2017). The Role of Intestinal Alkaline Phosphatase in Inflammatory Disorders of Gastrointestinal Tract. *Mediators of Inflamm.* 1-9. 9074601.

Bhutta MF., Thornton RB, Kirkham LAS, Joseph EK and Cheeseman MT (2017). Understanding the aetiology and resolution of chronic otitis media from animal and human studies. *DMM.*, **10**(11): 1289-1300.

Bosma PJ, Chowdury JR, Bakker C, Gantla S, de Boer A and Oostra BA *et al.* (1995). The genetic bases of the reduced expression of bilirubin UDP-glucuronosyl transferase 1 in Gilbert's syndrome. *N. Engl. J. Med.*, **333**(18): 1171-1175.

Brown OE, Wright CG, Edwards LB and Meyerhoff WL (1989). The ototoxicity of ceftazidime in the chinchilla middle ear. *J. Otolaryngol.-Head N*, **115**(8): 940-942.

Cohen-Naftaly M and Friedman SL. (2011) Current status of novel antifibrotic therapies in patients with chronic liver disease. *Therap. Adv. Gastroenterol.*, **4**(3):391-417.

Edoardo G, Giannini, Roberto Testa and Vincenzo Savarino (2005). Liver enzyme alteration: A guide for clinicians. *CMAJ.* **172**(3): 367-379.

Ghosh SS, Gehr TW and Ghosh S (2014). Curcumin and chronic kidney disease (CKD): Major mode of action through stimulating endogenous intestinal alkaline phosphatase. *Molecules*, **19**(12): 20139-20156.

Hall WC, Ganaway JR, Rao GN, Peters RL, Allen AM, Luczak JW, Sandberg EM and Quigley BH (1992). Histopathologic observations in weanling B6C3F1 mice and F344/N rats and their adult. parental strains. *Toxicol. Pathol.*, **20**(2): 146-154.

Hintermann E, Ehser J, Bayer M, Pfeilschifter JM and Christen U (2013). Mechanism of autoimmune hepatic fibrogenesis induced by an adenovirus encoding the human liver autoantigen cytochrome P450 2D6. *J. Autoimmun.*, **44**(8): 49-60.

Iqbal J, Khan W, Raza SN, Naqvi NU, Rahat ZM, Azeem QE and Hussain B (2009). Frequency of chronic suppurative otitis media in the junior ranks of Pak army. *PAFMJ*, **59**(3): 367-370.

De Oliveira LC, Goldberg AC, Marin MLC, Schneidwind KR, Frade AF, Kalil J, Miura IK, Pugliese RPS, Danesi VLB and Porta G (2015). Autoimmune hepatitis in Brazilian children: IgE and genetic polymorphisms in associated genes. *J. Immunol. Res.*, 2015: 679813.

Feverly J and Blanckaert N (1986). What can we learn from analysis of serum bilirubin. *J. Hepatol.*, **2**(1): 113-121.

González-Quintela A, Vidal C, Lojo S, Pérez LF, Otero-Antón E, Gude F and Barrio E (1999). Serum cytokines and increased total serum IgE in alcoholics. *Ann. Allergy Asthma Immunol.*, **83**(1): 61-67.

Lum G and Gambino SR (1972). Serum gamma-glutamyl transpeptidase activity as an indicator of disease of liver, pancreas, or bone. *Clin. Chem.*, **18**(4): 358-362.

- Mansoor T, Musani MA, Khalid G and Kamal M (2009). *Pseudomonas aeruginosa* in chronic suppurative otitis media: sensitivity spectrum against various antibiotics in Karachi. *J. Ayub. Med. Coll Abbottabad.*, **21**(2): 120-123.
- Maria VA and Victorino RM (1997). Development and validation of a clinical scale for the diagnosis of drug-induced hepatitis. *Hepatology*, **26**(3): 664-669.
- Mehboob S, Rafi T, Mehjabeen, Saleem DM, Mehboob M and Ahmed H (2020). Effects of ceftazidime with and without imipramine and bromazepam on behavior and neuro-inflammatory parameters in rats with chronic suppurative otitis. *Pak. J. Pharm. Sci.*, **33**(3): 1271-1276.
- Molnar K, Vannay A, Szebeni B, Banki NF, Sziksz E, Cseh A, Gyorffy H, Lakatos PL, Papp M, Arato A and Veres G (2012). Intestinal alkaline phosphatase in the colonic mucosa of children with inflammatory bowel disease. *World J. Gastroenterol.*, **18**(25): 3254-3259.
- Mohsen AM, Asfour MH and Salama AA (2017). Improved hepatoprotective activity of silymarin via encapsulation in the novel vesicular nanosystem bilosomes. *Drug Dev Pharm.*, **43**(12): 2043-2054.
- Moss DW and Henderson RA (1999). In: Burtis CA, Ashwood ER (eds.) *Tietz Textbook of Clinical Chemistry*. Philadelphia: WB Saunders Company. *Clinical Enzymology.*, **3**(1): 676-684.
- Nwabuisi C and Ologe FE (2002). Pathogenic agents of chronic suppurative otitis media in Ilorin, *East Afr. Med. J.*, **79**(4): 202-205.
- Safadi R, Ohta M, Alvarez CE, Fiel MI, Bansal M, MehalWZ, Friedman SL (2004). Immune stimulation of hepatic fibrogenesis by CD8 cells and attenuation by transgenic interleukin-10 from hepatocytes. *Gastroenterology*, **127**(3): 870-882.
- Saleem DM, Mehboob S, Khan MM, Samad N, Zafar A and Haleem DJ (2018). Inhibition of diet-restriction-induced behavioral deficits by tryptophan administration in rats. *Pak. J. Pharm Sci.*, **31**(3): 1021-1029.
- Schumann G, Bonora R and Ceriotti F *et al.* (2002). IFCC Primary Reference Procedures for the Measurement of Catalytic Activity Concentrations of Enzymes at 37°C. Part 4. Reference procedure for the measurement of catalytic concentration of alanine aminotransferase. *Clin. Chem. Lab Med.*, **40**(7): 718-24.
- Trinidad A, Ramirez-Camacho R, Carcia-Berrocá JR and Verdagué JM *et al.*, (2005). *Pseudomonas aeruginosa* infection in the hypo ventilated middle ear; an experimental model. *Acta. Oto-Laryngologia.*, **125**(3): 266-269.