

The mouse model of hepatic veno-occlusive disease

Licai An^{1*}, Xijing Li^{2*}, Xiaoxia Chu¹, Xiaoqian Liu¹, Yuanfeng Zhang¹, Yanming Wang¹, Yan Wang¹ and Yinghui Liu¹

¹Department of Hematology, Yantai Yuhuangding Hospital, Yantai, China

²Department of Pathology, Yantaishan Hospital, Yantai, China

Abstract: With the application of hematopoietic stem cell transplantation, Subacute or acute increase in the incidence of hepatic veno-occlusive disease (HVOD) becomes more common and it can lead to fatal complications. This article characterizes a mouse model of HVOD induced by monocrotaline. After gavage with monocrotaline was performed on BALB/c mice, On the 3rd, 4th, 6th, 8th and 10th days, mice were anesthetized, blood was collected and the liver was removed. Liver slices were processed by HE stain, Masson's trichrome stain or immunohistochemical stain. From days 3 through 4, histopathology and cytokine changes were determined as severe, early HVOD. From days 6 through 8, the changes were considered to represent late HVOD. On the 10th day, the above changes showed that late HVOD gradually improved.

Keywords: Animal model, endothelial cell, fibrosis, inflammatory cytokines, liver function.

INTRODUCTION

Hepatic veno-occlusive disease (HVOD) usually occurs due to various causes such as hepatic lobule, central venous and sublobular venous damage, which lead to lumina stenosis or occlusion, thereby leads to intrahepatic portal hypertension. HVOD has become a most common and life-threatening complication, with incidence varying widely between studies depending on the type of transplant, conditioning regimen and criteria used to make the diagnosis. The rate of occurrence varied from 0 percent-60 percent (Coppell *et al.*, 2010). Retrospective analysis (Kalayoglu-Besisik *et al.*, 2005) showed that 24 percent of the deaths occurring were caused by HVOD within 100 days after hematopoietic stem cell transplantation (HSCT). The mortality rate was higher than 80 percent in the severe HVOD (Lee *et al.*, 2010; Enric *et al.*, 2011).

The pathogenesis of HVOD remains poorly understood, early diagnosis and differential diagnosis was is difficult, also there is no specific therapy. At present, mainly treatment is only restricted at protecting the liver, supportive therapy and antithrombolysis, but these symptomatic treatments are also limited by increased bleeding risk and lower mitigation rate. Many patients soon developed severe HVOD and death in short term. Therefore exploring the pathogenesis and therapeutic measure of HVOD to improve the quality of recipients survival after HSCT has important clinical significance.

The understanding of this disease comes from the histopathology of the patient's biopsy specimen and clinical manifestations (Tefferi *et al.*, 2001; Tack *et al.*,

2001; Mohty *et al.*, 2015) and experimentally from in vivo (Chen *et al.*, 2008; Chen *et al.*, 2011) and in vitro studies (DeLeve *et al.*, 1996). However, understanding of its underlying mechanism still remains poor. One of the main difficulties is lack of good animal models, which can play a great role in testing hypothesis and therapeutic effects. So far there were variety of HVOD models, but all have advantages and disadvantages. Borwska *et al.* built a HVOD model of nitrous acid amine, but lesions were generally lighter and only suitable for mild to moderate research (Borowska H *et al.*, 2004). We gavaged mice with monocrotaline to establish acute model of HVOD, this model has many advantages which are as follows: Economy, high success rates, small individual difference, short cycle to build model, short observation time after taking medicine. which contribute to follow-up studies on the prevention and treatment of HVOD. Thus, this study intends to provide assessment of the model, in order to providing a theoretical basis for further studies of HVOD.

Monocrotaline is not toxic until it undergoes metabolic activation to apyrrolic metabolite. But when it reaches the liver undergoing Cytochrome P450 catalyzation, it will oxidize to unstable dehydrogenation pyrrolidine alkaloids (DHP) and DHP can be further hydrolyzed to DHN, both of which react with glutathione (GSH) and generate weak toxic or nontoxic products. When the GSH content decreases, the formation of toxic substances is increased, which may lead to cells damage (DeLeve *et al.*, 1996). Hepatocytes in zone 3 of the liver acinus contain a high concentration of cytochrome P450 enzymes, but a low concentration of GSH. Zone 3 contains a lower concentration of GSH, which determines that LSEC is

*Corresponding author: e-mail: liuyinghuiyt@126.com

*Co-first author with equal contribution

more susceptible to damage from toxic substances (Valla, 2016; Yang *et al.*, 2016). Endothelial cell damaged is an important initial event in HVOD (Gozdzik *et al.*, 2008).

In this study, we built an animal model for monocrotaline-induced HVOD and performed characterization analysis using light microscope and Masson's stain. At each time point after administration of monocrotaline, we anesthetized three mice and collected samples, and the results were presented as the mean \pm standard deviation. To objectively describe HVOD progress, we established an evaluation system to rate the changes observed under light microscope as no change mild change, moderate change or severe change.

MATERIALS AND METHODS

Mice

Male BALB/c (n=30) mice at 10 to 12 weeks were obtained from Yangzhou University, Jiangsu Province, China. Mice, weighing 26 to 28 grams (g), were housed in sterilized cages at the Experimental Animal Center of Xuzhou Medical College.

Experimental model

All protocols dealing with animals were reviewed and approved by Jiangsu Society for Animal Care and Use Committee to ensure ethical and humane treatment of the animals. After feeding for 7 days, the mice were weighed and randomly divided into 2 groups: NS group (n=15) and MCT group (n=15). Mice in MCT group were gavaged with 200mg/kg monocrotaline in the morning (day0), NS group were gavaged with PBS alone. On the 3th, 4th, 6th, 8th and 10th days after administration of monocrotaline, three mice were euthanized and the livers of mice were removed and weighed, and then the liver indices (liver weight/body weight) were calculated. The livers were fixed and embedded following the pathological specimen processing procedure. All slices were processed by HE stain, Masson's trichrome stain or immunohistochemical stain for observation of hepatic injury. The study was approved by the Experimental Animal Ethics Committee from Yantai Yuhuangding Hospital.

Flow cytometry

The following monoclonal antibodies were used in this study for flow cytometry, anti-mouse CD41-APC (eBioscience, clone eBioMWRg30), anti-mouse CD61-PE (Becton Dickinson, clone 2C9-G3), anti-mouse CD62P-FITC (Becton Dickinson, clone RB40.34). Cytometric Bead Array (CBA) Mouse Inflammation Kit were purchased from BD Biosciences (San Jose, CA, USA). Antigens were labelled according to the manufacturer's instructions. Sample acquisition was performed on a FACS Calibur (BD Biosciences) flow cytometer using Cell Quest Pro software

(BD Biosciences) and further analysis was performed using Cell Quest Pro.

Histology and immunohistochemistry (IHC)

Liver was immediately taken out after mice were euthanized, fixed in neutral buffered formalin 4 percent, and embedded in paraffin after 24 hours for slicing. Histological observation was performed with hematoxylin and eosin staining; Weigert's hematoxylin, ponceau-acid fuchsin and 2 percent aniline blue were used for Masson's trichrome stain; immunohistochemical stain was used by ABC method and MECA-32 antibody for hepatic sinusoid observation.

Scoring of Light Microscopy

Evaluation of histological sections stained by hematoxylin-eosin, by Masson trichrome stains and immunohistochemistry stains was performed blindly by two pathologist. Histopathological changes of liver tissue on light microscopy were assessed by a modified Deleve scoring system (Deleve *et al.* 1999) and HSCT-HVOD scoring system through the researcher's preliminary experiment (Zeng *et al.* 2013). To classify HVOD as mild, moderate, or severe, an overall score was determined The diagnostic standard for early HVOD was a score of 0 or 1+ in central vein or hepatic sinusoid fibrosis; the diagnostic standard for late HVOD was a score of 2+ or 3+ in central vein or hepatic sinusoid fibrosis. Total score was obtained by adding the higher score between the subendothelial hemorrhage score and the hepatic sinusoid internal hemorrhage score to the higher score between the central vein fibrosis score and the sinusoidal fibrosis score; HVOD with a total score of 1~5 was rated as mild, 6~10 as moderate, 11~15 as severe (see table 1).

Biochemical and Physiological Parameters

On the 3th, 4th, 6th, 8th and 10th days after administration of monocrotaline, mice were anesthetized and blood was obtained by removing the eyeballs; Serum was kept for liver function tests. Bilirubin, aspartate amino transferase and alanine amino transferase levels were examined by Shanghai Slac Corporation, China, using an automatic analyzer (Erba XL-300, purchased from Germany).

Inflammatory cytokines detection

On the 3th, 4th, 6th, 8th and 10th days after administration of monocrotaline, mice were anesthetized by intraperitoneal injection of chloral hydrate and blood was collected by removing the eyeballs; anticoagulant EDTA was added to the peripheral blood, which was centrifuged at 4500r/m \times 5min; supernatant was collected and stored in freezer at -80°C. CBA method was applied to measure IL-6, IL-10, IL-12, MCP-1 and TNF- α level (Boue *et al.* 2014; Carson *et al.* 2003). Samples were removed from the freezer and resuscitated at 37°C for 30min, centrifuged at 1500r/m \times 5min; 50 μ l supernatant was collected to the testing tube, together with 50 μ l micro

spheres and 50 μ l PE-conjugated anti-mouse IL-6,IL-10,IL-12,MCP-1 and TNF- α testing agents; these were incubated at room temperature in dark for 3 hours; 1ml washing solution was then added, followed by centrifugation at 1500r/m \times 5min; supernatant was discarded and 300 μ l washing solution was added for loading; BD Cell Quest was used for IL-6,IL-10,IL-12,MCP-1 and TNF- α detection.

Activated platelets determination

On the 3th, 4th, 6th, 8th and 10th days after gavaging with monocrotaline, intraperitoneal injection of anesthesia and the middle of blood was collected by removing the eyeballs, then respectively added 5ul blood to A test tube, which equipped with platelet gelation inhibitor 2ul, anti-mouse CD41 antibodies 2ul, anti-mouse CD61 antibodies 2ul and negative control antibodies 2ul and B test tube ,which equipped with platelet gelation inhibitor 2ul, anti-mouse CD41 antibodies 2ul, anti-mouse CD61 antibodies 2ul and anti-mouse CD62P antibodies 2ul. These were incubated at room temperature in dark for 20min after antigating, then 500ul platelet buffer was added to each test tube. Flow cytometry was used to detect the proportion of Activated platelets.

STATISTICAL ANALYSIS

Results were presented as mean \pm standard deviation (SD). Statistical significance was calculated using an unpaired t-test with Welch's correction (Graph Pad Prism 8.0.0, Inc., La Jolla, CA, USA). $P \leq 0.05$ was considered statistically significant.

RESULTS

Clinical diagnosis of HVOD

The clinical syndrome of hepatic veno-occlusive disease (HVOD) was characterized by hyperbilirubinemia (bilirubin \geq 2mg/dl), unexplained weight gain (\geq 2 or 5% body weight) and dolorous hepatomegaly (Coppell *et al.* 2003). In this experiment, we used liver index, total bilirubin (TBIL), alanine amino transferase (ALT) and aspartate amino transferase (AST) levels as evaluation indices for the clinical diagnosis of HVOD in mice after administration of monocrotaline. Liver index is the ratio of liver weight to body weight. Together with TBIL, ALT and AST levels, these are important indices for evaluating the degree of liver damage, for following the progress of liver disease and for evaluating the treatment effect and the prognosis. We euthanized the mice on the 3rd, 4th, 6th, 8th and 10th days after administration of monocrotaline removed the livers and calculated liver index.

As shown in fig. 1A, the liver index started to increase on day 3 after administration of monocrotaline and peaked on the 4th day (0.0717 \pm 0.00092) μ mol/l, from days 6th to 10th, the liver index showed descend tendency, on the 10th

it still fall short of normal, but was still 1.13 times that of the control value (0.052 \pm 0.00093) μ mol/l ($P < 0.05$). When liver cells are damaged, metabolism of bilirubin is also disturbed; pathological changes in the liver cells, disrupted transformation from bilirubin to bile, or obstruction of bile secretion due to increase pressure in the bile duct caused by liver cell swelling, can all lead to an increase of the TBIL level in the blood. We collected mice sera at different times and detected the TBIL level. At every point, peripheral blood serum was gathered for TBIL, the results as shown in fig. 1B, 3 days after administration of monocrotaline the TBIL level reached peak value (37.59 \pm 0.86) μ mol/l, then decreased gradually, on the 10th reached the minimum (25.14 \pm 0.64) μ mol/l, but was still 1.28 times that of the control value ($P < 0.05$). ALT mainly exists in the cytoplasm of the liver cells, and its intracellular concentration is 1000-3000 times higher than its concentration in the serum.

Therefore necrosis of 1% liver cells could lead to one-fold increase of ALT in the serum and ALT is recommended by World Health Organization (WHO) as the most sensitive indicator of liver damage. In this study, we tested changes in ALT level in the mice serum. As shown in fig. 1C, 3 days after administration of monocrotaline ALT level began to increase, on the 4th the ALT levels reached peak value (71.58 \pm 1.20)U/L, about 1.59 times the normal control level, on the 6th, 8th it decreased slightly, until the 10th it reached the minimum value (53.09 \pm 0.77) U/L, but still higher than the control group ($P < 0.05$). AST mainly exists in the mitochondrion of the liver cells, when hepatocytes are severely damaged or necrosis is there, it also lead to increase of its concentration in the serum. AST level helps us diagnose diseases and judge prognosis. In this study, we tested changes in AST level in the mice serum, the results as shown in fig. 1D, 3 days after administration of monocrotaline AST level began to increase. On the 4th the AST level reached peak value (81.58 \pm 0.76)U/L, compared with the control group increase by 52.0%. Between days 6 through 8, AST level showed descend tendency, until the 10th it reached the minimum value (75.68 \pm 1.22) U/L, but was still 1.28 times that of the control value (59.34 \pm 0.70)U/L($P < 0.05$).

Pathological diagnosis of HVOD

Observation under light microscope

On the 3th, 4th, 6th, 8th and 10th days after administration of monocrotaline, there was no spontaneous death among all 30 mice. Pathological changes of the liver were evaluated based on standards, and the results are shown in table 2. On the 3rd and 4th days, hepatocyte necrosis and subendothelial hemorrhage were rated 3. Central venous fibrosis was rated as 1 or 2. The overall score of liver injury was 11~14, which was considered severe HVOD. On the 6th and 8th days, hepatocyte necrosis and subendothelial hemorrhage were only rated 1, but central hepatic vein fibrosis and hepatic sinusoidal fibrosis were

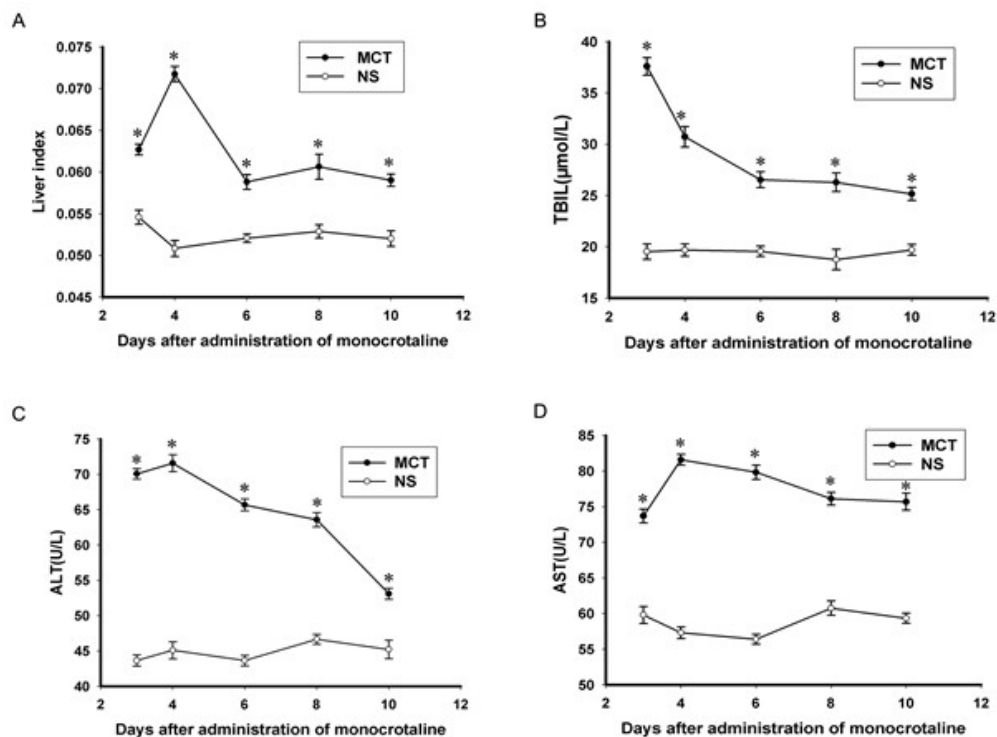


Fig. 1: Clinical diagnosis of HVOD A. On the 3th, 4th, 6th, 8th and 10th days after administration of monocrotaline, livers of the mice were taken out, weighed and liver indices were calculated. B. At those same time points, the mice were euthanized and peripheral blood serum was gathered for TBIL C. At those same times, the mice were euthanized and peripheral blood serum was gathered for ALT. D. At those same times, the mice were euthanized and peripheral blood serum was gathered for AST. All data were presented as mean ± SD. * means $P < 0.05$.

rated 2-3. The total score of liver damage was 7~10, which was moderate HVOD. On the 10th day, except for the central venous fibrosis score of 3, all other scores improved.

Early HVOD

From days 3 through 4, lining of central vein swelling, blood congestion in the sinusoids with endothelial injury, sinusoidal hemorrhage was observed, there was severe damage to hepatocytes and subendothelial fibrosis in a few central veins was found (fig. 2A, B) Based on the evaluation standard shown in table 1, these pathological changes under light microscope were defined as severe, early HVOD.

Late HVOD

From days 6 through 8, fibrosis of the central veins and hepatic sinusoidal was mild on the early HVOD and progressively worsened to moderate or severe, so that the changes were considered to represent ‘‘late HVOD’’ (fig. 2B). Coagulative necrosis were alleviated remarkably, central veins and sinusoid endothelial injury sustained, but compared with the prophase damages improved obviously (figs. 2A, B, C). On the 10th, hepatocellular edema and blood congestion in the sinusoids were no longer observed, coagulative necrosis had resolved

completely and damage to the sinusoidal wall began to abate, but there were continued fibrosis of central hepatic veins and hepatic sinusoidal (figs. 2A, B, C).

The development of HVOD and analysis of hypercoagulability

Activated platelets determination

On the 3th day after administration of monocrotaline, the ratio of activated platelets began to increase on the 4th day, the ratio of activated platelets reached peak value ($4.14\% \pm 0.2\%$), about 19.7 times of normal level. From days 6 through 10 the ratio of activated platelets decreased obviously (fig. 3A), but still not returned to normal levels ($P < 0.05$).

Inflammatory cytokines detection

Clinical studies and animal models demonstrated a variety of inflammatory cytokines, such as TNF- α , IL-6, IL-10, IL-12 and MCP-1, whose levels were closely related to the occurrence of HVOD. For example, TNF- α is harmful to LSEC, and can cause damages in the endothelial cells structures and function. In addition, TNF- α also leads to platelets activation and induces hypercoagulability. Therefore, in this study we detected inflammatory cytokines after administration of monocrotaline and found that the IL-6, IL-10, IL-12 and TNF- α concentration in

Table 1: Evaluation standards for liver damage

	0	1	2	3
Endothelium injury in liver sinusoid or small hepatic veins	No damage	Mild damage (minor damage, exfoliation of liver sinusoidal endothelia and liver sinusoidal lining cell loss, or endothelial injury, exfoliation in local regions but not the whole courses of blood vessels)	Moderate damage (damage, exfoliation of part of liver sinusoidal endothelia and liver sinusoidal lining cell loss, or endothelial injury, exfoliation along the whole courses of a few blood vessels)	Severe damage (damage, exfoliation of the majority of liver sinusoidal endothelia and liver sinusoidal lining cell loss, or endothelial injury, exfoliation along the whole courses of the majority of blood vessels)
Liver cell necrosis	No necrosis	Mild necrosis (necrosis of the center of some hepatic lobules, no necrosis of the interlobular septa)	Moderate necrosis (necrosis of the center of most hepatic lobules and necrosis of some of the interlobular septa)	Severe necrosis (necrosis of the center of most hepatic lobules and necrosis of the majority of the interlobular septa)
Subendothelial hemorrhage	No hemorrhage	Mild hemorrhage (occasional subendothelial hemorrhage in the central veins)	Moderate hemorrhage (subendothelial hemorrhage in a few central veins)	Severe hemorrhage (subendothelial hemorrhage in most central veins)
Internal hemorrhage in the hepatic sinusoid	No hemorrhage	Mild hemorrhage (hemorrhage in local regions of the sinusoids in central veins)	Moderate hemorrhage (hemorrhage in most of the sinusoids in the central veins, and in a few interlobular septa)	Severe hemorrhage (hemorrhage in most of the sinusoids in the central veins and in the majority of interlobular septa)
Fibrosis of the central veins	No fibrosis	Mild fibrosis (Subendothelial fibrosis in a few central veins)	Moderate fibrosis (Subendothelial fibrosis in the majority of central veins, along with a few perivenular fibrosis)	Severe fibrosis (Subendothelial fibrosis along with perivenular fibrosis in the majority of central veins)
Hepatic sinusoidal fibrosis	No fibrosis	Mild fibrosis (focal sinusoidal fibrosis in the hepatic lobules)	Moderate fibrosis (diffuse sinusoidal fibrosis in the minority of hepatic lobules)	Severe fibrosis (diffuse sinusoidal fibrosis in the majority of hepatic lobules)
Inflammation in the central veins	No inflammatory infiltration	Mild infiltration (focal inflammatory infiltration)	Moderate infiltration (diffuse inflammatory infiltration in the minority of central veins)	Severe infiltration (diffuse inflammatory infiltration in the majority of central veins)

Table 2: Evaluation scores of liver damage at different times after administration of monocrotaline

	3d	4d	6d	8d	10d
Endothelium injury in liver sinusoid or small hepatic veins	2	3	2	1	1
Liver cell necrosis	3	3	2	1	1
Subendothelial hemorrhage	3	3	1	1	1
Internal hemorrhage in the hepatic sinusoid	2	3	1	1	1
Fibrosis of the central veins	½	½	3	3	3
Hepatic sinusoidal fibrosis	1	½	3	2	1
Inflammation in the central veins	2/3	3	½	½	0/1
Total score	11~13	13/14	9/10	7/8	6/7

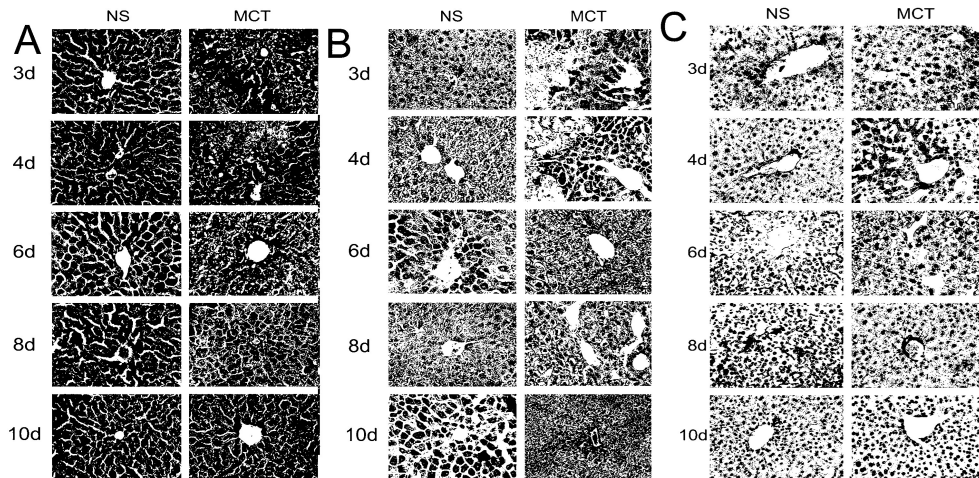


Fig. 2: Pathological diagnosis of HVOD. A. HE staining was operated after sample collections on the 3rd, 4th, 6th, 8th and 10th days after administration of monocrotaline B. Masson's trichrome staining was operated following 24 hours' fixation after sample collections at those same time points. C. Immunohistochemical staining was performed following 24 hours' fixation in 4% Formalin after sample collections on the 3rd, 4th, 6th, 8th and 10th days after administration of monocrotaline. Shown here were exemplar data selected from the three independent mice in each group. Magnifications of all slices were $\times 400$.

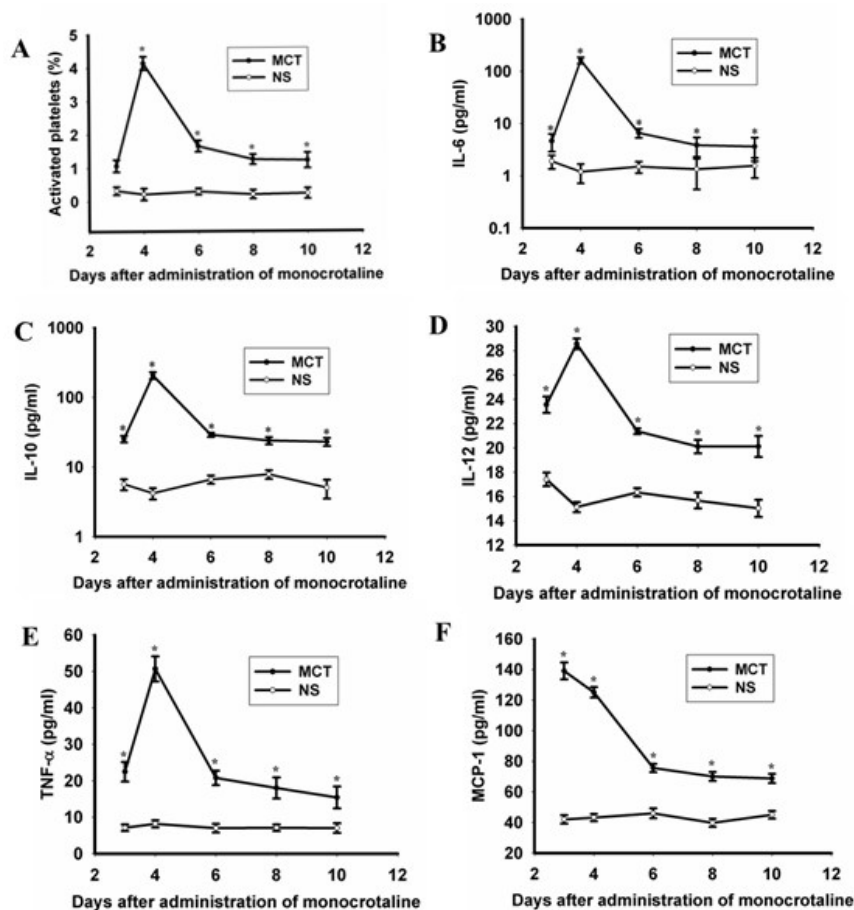


Fig. 3: Analysis of the formation and hypercoagulability of HVOD .A. After animal anesthesia at different time points, peripheral blood was acquired and flow cytometry was applied to measure the percent of activated platelets. B-F. On the 3th, 4th, 6th, 8th and 10th days after administration of monocrotaline, the mice were euthanized and the peripheral blood was acquired. IL-6, IL-10, IL-12, TNF- α and MCP-1 levels of the serum were measured. *means $P < 0.05$.

the peripheral blood after administration of monocrotaline began to increase on the 3rd. On the 4th the concentration of inflammatory cytokines reached the peak value. From days 6 through 8 they showed descend tendency, on the 10th they turned to normal level ($P<0.05$) (figs. 3B, C, D, E). MCP-1 is a kind of chemokine, which is necessary for mononuclear cell proliferation, maturation, survival and activation and required to participate in the immune response in inflammatory cell chemotaxis, activation process. It reached peak value on the 3rd on the 4th always occupied a higher level, on the 6th it showed decrease, on the 10th tend to normal level ($P<0.05$) (fig. 3F)

DISCUSSION

The researchers experiments provided the basis for successful establishment of HVOD model. The time course of the changes could be divided into two phases: Early HVOD on days 3 through 4 and late HVOD on days 6 through 8, on the 10th late HVOD tended to normalize. Between the 3th and 4th, the earliest manifestations of toxicity were morphological changes of SEC and CV endothelial cells, recruitment of monocytes into the lobule and adherent to the CV endothelium and severe coagulative necrosis of hepatocytes. The most obvious performance appeared on the 4th, the disruption of sinusoidal wall integrity and blood cells in the space of Disse were observed. From days 3 through 5, the classical features of early HVOD were present, with fibrosis of the central hepatic veins and hepatic sinusoidal, coagulative necrosis of hepatocytes decreased, the damage of sinusoidal wall alleviated. Treatment with monocrotaline caused progressive destruction of the sinusoidal wall, which peaked at day 4, after which there was a progressive reconstruction of the sinusoidal wall in surviving mouse. On the 10th the integrity of the sinusoidal walls almost reconstructed completely, but fibrosis of the central veins and hepatic sinusoidal persisted.

One of the etiological factors that induce HVOD is ingestion of PAs. Monocrotaline is one of the PAs which is toxic to the liver and monocrotaline is not toxic until it undergoes metabolic activation to a pyrrolic metabolite. Hepatocytes in zone 3 contain glutathione S-transferase (GST) enzymes which catalyze the reaction of glutathione with electrophilic compounds, nevertheless the concentration of glutathione (GSH) lower than other zones, which were able to transform drugs into nonactive water soluble metabolites. GSH plays a role in detoxification due to its anti-oxidant nature. Sinusoidal endothelial cells and hepatocytes in zone 3 of liver acinus lack GSH which caused the cells here to be more susceptible to injury due to toxic substances. Sinusoidal endothelial cells were damaged easily by toxic substances due to lower content of GSH and GST isozymes. In vitro toxicity studies demonstrated that the greater

susceptibility of SEC to drugs and toxins that cause HVOD, evidence has shown that damage of LSECs is an initial step leading to HVOD (Tefferi *et al.*, 2001; Fan, 2014). In addition, monocrotaline toxic to the liver was influenced by CYP3A. Although estrogens had no apparent effect on the activity of CYP3A, female were not susceptible to the PA (Gorski *et al.*, 2000), therefore we selected male mice as experimental subjects.

Clinical diagnosis of HVOD was referred from the Baltimore and Seattle standards (Coppell *et al.*, 2003). hepatomegaly, right upper quadrant pain, ascites and presence of hyperbilirubinemia. In this experiment, we utilized liver index, TBIL, ALT and AST levels for the clinical diagnosis of HVOD, which showed parallel changes in our model, experimental group mice demonstrated severe hepatocellular edema and liver function damage obviously, these mice were clinically diagnosed with HVOD.

The histological manifestations of HVOD include central veins and sublobular vein line swelling and fibrosis leading to obstruction of central veins and liver sinusoids, blood stream choked with hepatocellular degeneration and coagulation necrosis. In our study, we observed early hepatic injury by HE stain, Masson's trichrome stain or immunohistochemical stain, including liver sinusoids and sublobular vein lining falling off, blood congestion in the sinusoids with dilatation, edema and severe necrosis of hepatocyte. On later HVOD the pathological changes were characterized by deposition of fibrin-like materials in LSs (fig. 2). Thus, this model does seem to represent true HVOD. We used a modified evaluation system to characterize the changes and the degree of these changes observed under light microscope caused by monocrotaline induced HVOD (table 1), So that pathological changes were deemed more accurate.

Comparing monocrotaline group with control group, the researchers found that the liver damage showed spontaneous improvement judging from the experimental data and light microscopic scoring. These results were consistent with Deleve's paper (Deleve *et al.*, 1999). Liver index, TBIL, ALT, AST and activated platelets all reached peak value on the 3th and 4th days after administration of monocrotaline, at this time, Severe coagulative necrosis of liver cells, blood sinus congestion, and loss of sinusoidal wall integrity were observed. However, between the 6th and 8th days after administration of monocrotaline, all detection of targets decreased. Pathological section showed that degeneration and necrosis of hepatocytes were improved, central vein and lobular vein intima swelling were alleviated, sinusoidal congestion alleviated, but fibrin deposition of the central veins and hepatic sinusoidal persisted. On the 10th, every target was not restored to normal levels. Pathological section showed that hepatic sinusoidal was clear, apparent

congestion was no longer detected, necrosis of hepatocytes were improved, fibrosis of the central hepatic veins and hepatic sinusoidal were still persistent.

Liver Sinusoidal endothelial cells (LSECs) are not only supporting cells of hepatocytes in the resting liver, but also a source of vascularization during liver regeneration. When LSECs are damaged, hepatocytes enter apoptotic state due to lack of supporting cells and the angiogenesis ability of liver parenchyma is lost; meanwhile, impaired LSECs secrete cytokines abnormally further worsens liver function. Then, when the central veins and sublobular veins are damaged, they release PAI-1 and TF, which induce platelet activation and cause liver function abnormalities of hemostasis; however, activated platelet promoted occurrence of hypercoagulable states through PAI-1 and TF which released by endothelial cells (Pihusch *et al.*, 2005), exacerbating liver cell damage and causing irreversible liver damage. Knolle *et al.* reported that LSECs were involved in the formation of immune tolerance and they were considered to be a point of adjustment between immunogenicity and immune tolerance (Knolle *et al.*, 2003). Schildberg *et al.* (2008) confirmed that LSEC prevented antigen-specific immune response by inhibiting DC activated initial CD8⁺T cells (Schildberg *et al.*, 2008). Abnormal liver structure and function may be the result of damage to LSEC.

Endothelial cell damage is thought to be the first step and the promoter of the HVOD pathogenesis (Gozdzik *et al.*, 2008), which promoted platelet activation and produced procoagulant cytokines and is involved in the development of HVOD. In our study, the following morphological changes were observed on day 3, the detection of targets of experimental group mice began to increase; on the 4th we observed that LSEC damaged most pronounced, activated platelets, liver index, ALT and TBIL reached the peak value (fig. 1,3A). On day 4th, light microscopic manifestations of liver sections including the integrity of sinusoidal walls disappeared, liver sinusoid congestion and extension obviously, hepatocytes in zone 3 of liver acinus damaged severely as well as patches. This result is consistent with that from Carreras E *et al.* (Carreras, 2000). Between days 6 and 10, liver function abnormality and platelet activation considerably increased, fibrosis of central vein and hepatic sinusoid were more obvious (figs. 1, 2, 3) which promoted blood hypercoagulability or thrombosis in the hepatic venules.

There has been increasing evidence that a variety of inflammatory cytokines play an important role in many types of liver disease, including drug- and toxin-induced disease. Between days 3 and 4, HE staining showed that lobules and central vein diffuse infiltration of mononuclear cells. At the same time, in the study we found MCP-1 at a high level which demonstrated widespread inflammation. Therefore, the activation of

mononuclear cells released cytokines, such as TNF- α , IL-6 and Reactive Oxygen Species, then stimulated T cells and NK cells secreting TNF- α and IL-6 which can induce liver cells necrosis and fibrosis by complex synergy and chain reaction, IL-6 improved platelet response to thrombin and promoted thrombosis (Esmon, 2004). TNF- α has been associated with the occurrence of HVOD and other thrombotic diseases, high expression of TNF- α mRNA were obtained by detachment of peripheral mononuclear cells in HVOD patients (Coppell *et al.*, 2003). TNF- α plays an important role in the process of liver damage, hepatic stellate cells (HSC) activation and liver regeneration (Marra, 2002; Diehl, 2002). It is reported that TNF- α can promote activated HSC secreting many kinds of cytokines such as IL-6, TGF- β which activated HSC and aggravated liver fibrosis through producing abundant extra cellular matrix (ECM) (Faouzi *et al.*, 1999). IL-12 mainly effects on T cells and NK cells which can stimulate the proliferation of activated T cells and promote Th0 cells differentiation to Th1 cells. In addition, IL-12 induces CTL cells and NK cells cytotoxic activity, thereby promoting their secretion of some cytokines such as INF- γ , TNF- α and GM-CSF *et al.* In our study, we found IL-12 reached the peak in the 4th which fully reflect the inflammatory injury more seriously. From the days 6 to 10, the concentration of IL-12 decreased and inflammatory injury alleviated.

IL-10 inhibited T cell generation of cytokines, especially inhibit Th1 cell secretion IL-2, INF- γ and LT, thus inhibiting the cellular immune response. IL-10 reduced monocyte-macrophage cells surface expression of MHC-II molecules, at the same time, it damaged the ability of APC antigen-presenting cell. It's actually the reason for suppressing cellular immunity. In addition, IL-10 inhibit NK cells activity, interfere with NK cells and macrophages to secrete cytokines. In this study, we detected a high level of IL-10 on the 3rd and 4th after administration of monocrotaline in experimental group mice and on the 4th it reached the peak value. These fully displayed that the inflammatory injury more serious on the 3rd and 4th, when organism plays the compensation.

HVOD is a kind of disease which is caused by sinusoidal endothelial and vascular endothelial injury. At present its treatment strategies mainly focus on antithrombotic and thrombolytic studies, with a view to reducing the further hepatocellular injury in HVOD patients, thereby protecting liver function. Defibrotid (DF) and Tissue plasminogen activator are the representative drugs (Corbacioglu *et al.*, 2015; Richardson *et al.*, 2018), but remission rates are less than 50 percent (Richardson *et al.*, 2001). This shows that HVOD once occurs, prognosis is poor and prevention is better than cure. In hematopoietic stem cell transplantation, a simple proper control of cytotoxic dose and fractionated total body irradiation conditioning regimen are often adopted for preventive

therapy to reduce side effects on liver or suffering from acute liver injury such as hepatitis had to delay transplant period to ensure that the liver of transplant recipients tolerant with preconditioning. However, current clinical data indicate that the means of both prevention and treatment will not reduce the occurrence of HVOD. It is imperative to seek practical and effective means to prevent HVOD.

CONCLUSION

In summary, this article has characterized a simple animal model of HVOD according to the clinical diagnostic criteria and by light microscopy, electron microscopy, and immunoperoxidase staining of endothelial cells. Early HVOD on days 3 through 4 and late HVOD on days 6 through 8, on the 10th late HVOD tended to be normal. The model exhibits the characteristic clinical and histological features of HVOD. In conclusion, here we provided a good model for further study the pathogenesis and prevention measures of HVOD.

ACKNOWLEDGEMENTS

The authors thank Dr Lingyu Zeng (Department of Hematology, The Affiliated Hospital of Xuzhou Medical University, Jiangsu, China) for assistance with the experiment. Financial support: This research was supported by Youth Startup Fund of Yantai Yuhuangding Hospital (grant no. 201501). Conflict of interest: The authors do not have any disclosures to report.

REFERENCES

- Borowska H, Aieiszewska E, Czaudema P, Sawicki B (2004). Daetinomycin-induced veno-occlusive disease in rats. The hepatoprotective action of amifostine. Evaluation in a light and electron microscope. *Folia Morph-ologia*, **63**(1): 91-93.
- Boué J, Basso L, Cenac N, Blanpied C, Rolli-Derkinderen M, Neunlist M, Vergnolle N, Coppell JA, Richardson PG, Soiffer R, Martin PL, Kernan NA, Chen A, Guinan E, Vogelsang G, Krishnan A, Giral S, Revta C, Carreau NA, Iacobelli M, Carreras E, Ruutu T, Barbui T, Antin JH and Niederwieser D (2010). Hepatic Venocclusive Disease following Stem Cell Transplantation: Incidence, Clinical Course and Outcome. *Biol. Blood Marrow Transplant*, **16**(2): 157-168.
- Carreras E (2000). Veno-occlusive disease of the liver after hemopoietic cell transplantation. *Eur. J. Haematol.*, **64**(5): 281-291.
- Carson RT and Vignali DA (1999). Simultaneous quantitation of 15 cytokines using a multiplexed flow cytometric assay. *J. Immunol. Methods.*, **227**(1-2): 41-52.
- Chen MY, Cai JT, Du Q, Wang LJ, Chen JM and Shao LM (2008). Reliable experimental model of hepatic veno-occlusive disease caused by monocrotaline. *Hepatobiliary Pancreat Dis. Int.*, **7**(4): 395-400.
- Chen Z, Huo JR, Yang L and Zhu HY (2011). Effect of ligustrazine on mouse model of hepatic veno-occlusive disease induced by Gynura segetum. *J. Gastroenterol Hepatol.*, **26**(6): 1016-1021.
- Coppell JA, Brown SA and Perry DJ (2003). Veno occlusive disease: Cytokines, genetics and haemostasis. *Blood Rev*, **17**(2): 63-70.
- Corbacioglu S, Carreras E, Mohty M, Pagliuca A, Ballabio M, Hume R, Bandiera V, Finetto G and Richardson PG (2015). Defibrotide for the treatment of hepatic veno-occlusive disease: an update from the international compassionate use program in 710 patients. *Biol. Blood Marrow Transplant*, **21**(2): S108-S108.
- DeLeve LD (1996). Cellular target of cyclophosphamide toxicity in the murine liver: Role of glutathione and site of metabolic activation. *Hepatology*, **24**(4): 830-837.
- Deleve LD, McCuskey RS, Wang XD, Hu L, McCuskey MK, Epstein RB, Kanel GC (1999). Characterization of a reproducible rat model of hepatic veno occlusive disease. *Hepatology*, **29**(6): 1779-1793.
- Diehl AM (2002). Liver regeneration. *Front Biosci.*, **7**: e301-e314.
- Dietrich G (2014). Endogenous regulation of visceral pain via production of opioids by colitogenic CD4(+) T cells in mice. *Gastroenterology*, **146**(1): 166-175.
- Enric C, Marina DB, Laura RO, Carmen M, Francesc FA and Montserrat R (2011). The incidence of veno-occlusive disease following allogeneic hematopoietic stem cell transplantation has diminished and the outcome improved over the last decade. *Biol. Blood Marrow Transplant*, **17**(11): 1713-1720.
- Esmon CT (2004). Crosstalk between inflammation and thrombosis. *Maturitas*, **47**(4): 305-314.
- Fan CQ and Crawford JM (2014). Sinusoidal obstruction syndrome (hepatic veno-occlusive disease). *J. Clin. Exp. Hepatol.*, **4**(4): 332-346.
- Faouzi S, Lepreux S, Bedin C, Dubuisson L, Balabaud C, Bioulac-Sage P, Desmoulière A and Rosenbaum J (1999). Activation of cultured rat hepatic stellate cells by tumoral hepatocytes. *Lab Invest*, **79**(4): 485-493.
- Gorski JC, Wang Z, Haehner-Daniels BD, Wrighton SA and Hall SD (2000). The effect of hormone replacement therapy of CYP3A activity. *Clin. Pharmacol. Ther.*, **68**(4): 412-417.
- Gozdziak J, Krasowska-Kwiecień A, Wedrychowicz A (2008). Sinusoidal obstruction disease (SOS), previous hepatic venoocclusive disease (VOD)--still serious complication after hematopoietic stem cell transplantation. *Przegl Lek.*, **65**(4): 203.
- Kalayoglu-Besik S, Yenerel MN, Caliskan Y, Ozturk S, Besik F and Sargin D (2005). Time related changes in the incidence, severity and clinical outcome of hepatic veno occlusive disease in hematopoietic stem cell transplantation patients during the past 10 years.

- Transplant Proc.*, **37**(5): 2285-2289.
- Knolle PA (2003), Limmer A. Control of immune responses by scavenger liver endothelial cells. *Swiss Med Wkly*, **133**(37-38): 501-506.
- Lee SH, Yoo KH, Sung KW, Koo HH, Kwon YJ, Kwon MM, Park HJ, B-K P, Kim YY and Park JA (2010). Hepatic veno-occlusive disease in children after hematopoietic stem cell transplantation: Incidence, risk factors, and outcome. *Bone Marrow Transplant*, **45**(8): 1287-1293.
- Marra F (2002). Chemokines in liver inflammation and fibrosis. *Front Biosci.*, **7**: d1899-d1914.
- Pihusch V, Pihusch M, Penovici M, Kolb HJ, Hiller E, Pihusch R (2005). Transforming growth factor beta-1 released from platelets contributes to hypercoagulability in veno-occlusive disease following hematopoietic stem cell transplantation. *Thromb. Res.*, **116**(3): 233-240.
- Mohty M, Malard F, Abecassis M, Aerts E, Alaskar A, Aljurf M, Arat M, Bader P, Baron F and Bazarbachi A (2015). Sinusoidal obstruction syndrome/veno-occlusive disease: Current situation and perspectives-a position statement from the European Society for Blood and Marrow Transplantation (EBMT). *Bone Marrow Transplant*, **50**(6): 781-789.
- Richardson P, Guinan E (2001). Hepatic veno-occlusive disease following hematopoietic stem cell transplantation, *Acta. Haematol.*, **106**(1-2): 57-68.
- Richardson PG, Triplett BM, Ho VT, Chao N, Dignan FL, Maglio M, Mohty M (2018). Defibrotide sodium for the treatment of hepatic veno-occlusive disease/sinusoidal obstruction syndrome. *Expert. Rev.* *Clin. Pharmacol.*, **11**(2): 113-124.
- Schildberg FA, Hegenbarth SI, Schumak B, Scholz K, Limmer A, Knolle PA (2008). Liver sinusoidal endothelial cells veto CD8 T cell activation by antigen-presenting dendritic cells. *Eur. J. Immunol.*, **38**(4): 957-967.
- Tack DK, Letendre L, Kamath PS, Tefferi A (2001). Development of hepatic veno-occlusive disease after Mylotarg infusion for relapsed acute myeloid leukemia. *Bone Marrow Transplantation*, **28**(9): 895-897.
- Tefferi A, Kumar S, Wolf RC, Lacy MQ, Inwards DJ, Gloor J M, Albright RC, Kamath PS and Litzow MR (2001). Charcoal hemofiltration for hepatic veno-occlusive disease after hematopoietic stem cell transplantation. *Bone Marrow Transplantation*, **28**: 997-999.
- Valla DC, Cazals-Hatem D (2016). Sinusoidal obstruction syndrome. *Clin. Res. Hepatol. Gastroenterol.*, **40**(4): 378-385.
- Yang M, Ruan J, Fu PP and Lin G (2016). Cytotoxicity of pyrrolizidine alkaloid in human hepatic parenchymal and sinusoidal endothelial cells: Firm evidence for the reactive metabolites mediated pyrrolizidine alkaloid-induced hepatotoxicity. *Chem. Biol. Interact.*, **243**: 119-126.
- Zeng L, An L, Fang T, Pan B, Sun H, Chen C, Cao J, Li Z and Xu K (2013). A murine model of hepatic veno-occlusive disease induced by allogeneic hematopoietic stem cell transplantation. *Cell. Biochem. Biophys.*, **67**(3): 939-948.