

Clinical application of irinotecan combined with first-line chemotherapeutics against pediatric hepatoblastoma with pulmonary metastasis

Huimin Hu[#], Weiling Zhang[#], Jing Li, Fan Li, Yuan Wen, Yanyan Mei and Dongsheng Huang*

Department of Pediatrics, Beijing Tongren Hospital, Capital Medical University, Beijing, China

Abstract: This study aimed to investigate the short-term efficacy and adverse reactions of irinotecan combined with first-line chemotherapeutics for the treatment of pediatric hepatoblastoma with pulmonary metastasis (HB-PM). Forty-one pediatric patients with HB-PM undergoing cisplatin + fluorouracil + vincristine + doxorubicin (C5VD) treatment with bad therapeutic effect or bad response were instead treated with two cycles of an irinotecan protocol (vincristine + irinotecan + cyclophosphamide + cisplatin). The changes in recent alpha-fetoprotein (AFP), efficacy and adverse reactions in these patients were statistically analyzed. Results showed that, the median level of AFP before chemotherapy was 56432 µg/L; however, it was significantly lower (749 µg/L) after two cycles of chemotherapy (rank sum test, $P = 0.00$). After two cycles of chemotherapy, three patients achieved a complete response and 32 patients achieved a partial response. The recent efficacy cases accounted for 85.36% of patients (35/41). The delayed diarrhea was the most common adverse reaction to irinotecan, with an incidence rate of 58.53% (24/41), which was improved after symptomatic treatment. In conclusion, the protocol of irinotecan combined with first-line chemotherapeutics can be used for the treatment of HB-PM that is not sensitive to the C5VD protocol, with good short-term curative effect and tolerable adverse reactions.

Keywords: Hepatoblastoma, irinotecan, alpha-fetoprotein, adverse reactions.

INTRODUCTION

Hepatoblastoma (HB) is the most common liver malignancy in children, with an abdominal mass and alpha fetoprotein (AFP) elevation being the main clinical features. Over the past 20 years, given the widespread application of platinum-based neoadjuvant chemotherapeutics advocated by the Children's Oncology Group (COG), the International Society of Pediatric Oncology (SIOPEL) and the Japanese Study Group for Pediatric Liver Tumor (JPLT), the surgical resection rate and survival rate of patients with HB have significantly improved (Sunil *et al.*, 2018). Thus, based on these results, the cisplatin + fluorouracil + vincristine + doxorubicin protocol (C5VD) is recommended for high-risk HB cases in China (Chinese Anti-Cancer Association Pediatric Committee, 2017). HB with pulmonary metastasis (HB-PM) is defined as a high risk form of HB stratification (Meyers *et al.*, 2017); moreover, therapeutic effects against metastatic, recurrent, or progressive HB are still not ideal (Tang *et al.*, 2016; Trobaugh-Lotrario *et al.*, 2016; Zhang *et al.*, 2016).

Irinotecan (CPT-11) is one of the newly marketed hydroxycamptothecin derivatives, a new family of cytotoxic drugs. Studies have shown that the protocol of vincristine + irinotecan has a certain therapeutic effect against the recurrence and progression of HB (Katzenstein *et al.*, 2017; Powers *et al.*, 2018). The vincristine +

irinotecan combination is important for the treatment of high-risk HB and the adverse reactions of irinotecan are considered acceptable (Katzenstein *et al.*, 2017). However, because of the low incidence of HB and as irinotecan is a second-line chemotherapeutic drug, there are no multicenter clinical trials of irinotecan against HB-PM with a robust number of patients. Therefore, in this study, we administered two cycles of the vincristine + irinotecan + cyclophosphamide + cisplatin regimen to 41 pediatric patients with HB-PM, who were originally undergoing treatment with the conventional C5VD protocol in our department and not exhibiting a good response. We evaluated the post-treatment changes in AFP, recent efficacy and adverse reactions, with the goal of providing an effective treatment option for pediatric patients with HB-PM.

MATERIALS AND METHODS

General information

Between January 2016 and December 2018, the clinical data for 41 pediatric patients with HB-PM were collected. The diagnosis was made by pathological examination after a liver operation or puncture biopsy and patients underwent a pulmonary enhanced CT scan, which indicated pulmonary metastasis. The patients were admitted to the pediatrics department for chemotherapy and were originally treated with two cycles of the C5VD protocol. However, there were no obvious changes in AFP

*Corresponding author: e-mail: hds5180@sina.com

#Equal contributions

or in the size or number of pulmonary nodules. The patients then received two cycles of the irinotecan protocol (vincristine + irinotecan + cyclophosphamide + cisplatin). The 41 pediatric patients with HB were classified as stage IV, according to the international hepatoblastoma staging criteria issued by the COG (Ismail *et al.*, 2012). Informed consent to administer chemotherapy to each child was obtained from a family member and this study was reviewed and approved by the Ethics Committee of Beijing Tongren Hospital (No. 20140905).

Chemotherapy protocol

The conventional chemotherapy protocol was C5VD, specifically: cisplatin 20mg/m²/day, days 1-5; fluorouracil 12-15mg/kg/day, days 1-5; vincristine 1.5mg/m²/day, max ≤ 2 mg, day 1 and doxorubicin, 25mg/m²/day, days 2 and 3; however, because there was no doxorubicin at our hospital, pirarubicin was used instead, at a dosage of 25mg/m²/day, days 2 and 3. The irinotecan protocol was: vincristine + irinotecan + cyclophosphamide + cisplatin, specifically: vincristine 1.5mg/m²/day, maximum ≤ 2mg, day 1 irinotecan 50mg/m²/day, days 1-5; cyclophosphamide 250mg/m²/day, days 2-4 and cisplatin 20mg/m²/day, days 1-5, with every 21-28 days representing one cycle. Additionally, we routinely administered ceftizoxime for 5 days to prevent irinotecan-induced diarrhea. All 41 patients were administered two continuous cycles of this irinotecan protocol.

Efficacy assessment

The patients were evaluated before and after the two cycles of chemotherapy. The assessment included a physical examination, imaging (abdominal ultrasound, CT, or MRI) and the serum AFP level. The serum AFP was measured using electrochemiluminescence (Roche Cobas e601, Switzerland). The detection range of AFP at our hospital was 0–484000 µg/L and the maximum value of ≥ 484000 µg/L was treated as 484000 µg/L. The AFP value was measured before each cycle of chemotherapy, and a lung CT examination was conducted after every two cycles of chemotherapy.

Based on the results of these tests, the pediatric patients were divided into complete remission, partial remission, stable disease, progressive disease, or recurrence (Perilongo *et al.*, 2004). Complete remission indicated that lesions had completely disappeared and that AFP was normal for more than four cycles. Partial remission indicated that tumor size was reduced by more than 50%, without the occurrence of any new lesions or disease progression. Stable disease (SD) referred to a reduction in tumor size of < 50%, without any tumor enlargement or new lesions. Progressive disease (PD) referred to tumor enlargement of more than 25%, with new tumors or elevated AFP. In our patients, we evaluated only the recent efficacy, which was in terms of complete reaction, partial reaction (PR) and no reaction. The complete reaction

referred to the disappearance of pulmonary nodules and an obvious decrease in AFP. PR referred to pulmonary nodules that had shrunk at least 30% and decreased AFP. For the criterion of no reaction, the disease was considered stable or in a progressive status. The rate of efficacy was calculated for all cases.

Adverse reaction assessment

The patients were monitored for routine changes in blood cell counts during and after chemotherapy and were evaluated according to the side effect rating scale of radiotherapy and chemotherapy by the World Health Organization (WHO) (Trotti and Bentzen 2004). Hematological toxicity was mainly manifested as myelosuppression. The myelosuppression criteria were: peripheral white blood cell count (WBC) ≤ 3×10⁹/L; monocytes ≤ 3%; absolute value of neutrophils ≤ 1.0×10⁹/L; hemoglobin (HB) ≤ 80 g/L and platelets (PLT) ≤ 20×10⁹/L. The recovery criteria for myelosuppression were: Peripheral WBC ≥ 2.0×10⁹/L; absolute value of neutrophils ≥ 1.0×10⁹/L, HB ≥ 80 g/L and PLT ≥ 20×10⁹/L. Considering the adverse reactions that occurred after the first application of irinotecan as well as the effects of positive preventive measures during the second application, this study compared only the adverse effects occurring during the first irinotecan application.

Delayed diarrhea was defined as diarrhea that occurred 24 hours after administration. The mechanism of irinotecan-induced diarrhea is still unclear and may be related to the cytotoxic effect of CPT-11 on the epithelium of the digestive tract mucosa, which leads to dysfunction in water and electrolyte absorption and excessive secretion of small intestinal fluids. The criteria for diarrhea are explained as follows. When the number of stools increased to less than 4 times per day, it was considered grade I. When stools increased to 4-6 times per day or if stools appeared at night, it was considered grade II. If the number of stools increased to more than 7 times per day or fecal incontinence occurred, requiring intravenous nutrition support to improve dehydration status it was considered grade III. Finally, life-threatening water and electrolyte disorders, requiring intravenous nutrition and intensive care, were considered grade IV. After diarrhea occurred, large doses of loperamide were used for treatment (Tang *et al.*, 2019). When the first dilution occurred or fecal frequency increased and bowel sounds became hypersonic, patients were advised to drink a large quantity of an electrolyte-containing beverage and immediately begin appropriate anti-diarrhea treatment. At present, the recommended anti-diarrhea treatment is a high-dose of loperamide (4 mg for the first dose, followed by 2 mg every 2 h). The treatment lasted 12 hours after the last dilution and the dose was not changed during treatment. If diarrhea was not alleviated within 24 hours, the patient was advised to see a doctor.

STATISTICAL ANALYSIS

SPSS 21.0 software (SPSS Inc., US) was used for data processing. The measurement data were expressed as the mean \pm standard deviation or the median, and were compared using *t* test. Count data were expressed as the rate and were compared using χ^2 test. *P* value of < 0.05 was considered statistically significant.

RESULTS

Clinical features

The age of onset among the 41 patients, including 19 boys and 22 girls, was between 0.3 and 5.7 years, with the median age of onset being 1.6 years. There was one patient who was younger than 6 months. The characteristics of the 41 patients are shown in table 1. There were 4 cases of lung recurrence and 37 cases of newly diagnosed pulmonary metastasis. The four lung recurrence cases were shown in table 2.

Table 1: Clinical characteristics of HB-PM patients with lung metastases

Characteristic	Case [n(%)]
Gender	
Male	19(46.34)
Female	22(53.66)
Age (Year)	
< 0.5	1(2.44)
≥ 0.5	40(97.56)
PRETEXT stage system	
Stage III	5(12.20)
Stage IV	36(87.80)
Histopathology type	
Epithelial	27(65.85)
Mixed epithelial-mesenchymal	14(34.15)
Metastasis type	
Lung metastasis alone	29(70.73)
Extrapulmonary involvement	12(29.27)
Right atrial aneurysm thrombus	1(2.44)
Mediastinal metastasis	1(2.44)
Brain metastases	8(19.51)
Bone metastasis	1(2.44)

HB-PM, hepatoblastoma with pulmonary metastasis; PRETEXT, pretreatment extent of disease

AFP changes before and after chemotherapy

The serum AFP ranged from 1715 to 484000 $\mu\text{g/L}$, with a median of 60500 $\mu\text{g/L}$, before two cycles of C5VD treatment. After two cycles of C5VD chemotherapy, AFP ranged from 1000 to 484000 $\mu\text{g/L}$, with a median of 56432 $\mu\text{g/L}$. No significant differences in the values were observed before and after C5VD treatment ($P > 0.05$). The AFP values before the irinotecan protocol were in the range of 1000–484000 $\mu\text{g/L}$, with a median of 56432 $\mu\text{g/L}$. The AFP values after two cycles of chemotherapy were in

the range 110–320000 $\mu\text{g/L}$, with a median of 749 $\mu\text{g/L}$. The normal distribution test of AFP before and after chemotherapy was $P < 0.05$, which indicated that the data had non-normal distributions. The result of the rank sum test was $P = 0.00$ ($Z = -5.229$); thus, the values before and after treatment were significantly different. After two cycles of the irinotecan protocol, AFP significantly decreased. The AFP curves before and after chemotherapy were shown in fig. 1.

Short-term efficacy

Among the 41 patients, 3 patients had a complete remission of lung lesions, 32 patients had a partial remission, 5 patients had an SD and 1 patient had PD. The short-term effective rate was 85.36% (35/41). The changes in lung lesions before and after treatment are shown in fig. 2.

Adverse reactions

The adverse reactions to irinotecan were mainly manifested as hematological toxicity and digestive tract reactions. The incidence rates of grade I/II and grade III adverse hematological reactions were 92.68% (38/41) and 7.32% (3/41), respectively; these were completely improved after symptomatic treatment, such as treatment with active granulocyte colony-stimulating factor. The main gastrointestinal reactions were delayed diarrhea, abdominal pain, and vomiting. Of these, delayed diarrhea was the most common, with an incidence rate of 58.53% (24/41) and a stool frequency of 2–17 times per day. Grade I/II diarrhea accounted for 53.67% (22/41) and grade III diarrhea accounted for 4.88% (2/41). Diarrhea was completely resolved with symptomatic treatment, including treatment with loperamide, antibiotics and oral rehydration salts.

The incidence rate of abdominal pain was 26.83% (11/41), but this side effect was tolerable. The incidence of nausea and vomiting was 14.63% (6/41), grade I/II cases accounted for 12.20% (5/41). Only one patient (1/41, 2.42%) had serious vomiting and irinotecan was stopped. All toxic and side effects were completely relieved until the 21st day of chemotherapy.

DISCUSSION

Since the 1980s, after the application of chemotherapeutics, such as cisplatin and doxorubicin, as well as surgery combined with cisplatin-based neoadjuvant chemotherapy, the survival rate of HB has significantly improved. Although treatment strategies for patients with low-risk HB are different for various international collaboration groups, the overall curative effects were relatively satisfactory. However, the prognosis of patients with high-risk HB is still not optimistic and has become a clinical problem that requires urgent resolution.

Table 2: Clinical characteristics of four HB-PM patients with lung recurrence cases

Number	Case 1	Case 2	Case 3	Case 4
Gender	Male	Male	Female	Male
Age	1.25	4.75	3.0	2.0
Histopathology type	Epithelial	Epithelial	Epithelial	Mixed epithelial-mesenchymal
PRETEXT stage	IV	IV	IV	IV
Times of lung relapse	3	2	2	2
Cycles of chemotherapy	25	33	19	19

HB-PM, hepatoblastoma with pulmonary metastasis; PRETEXT, pretreatment extent of disease

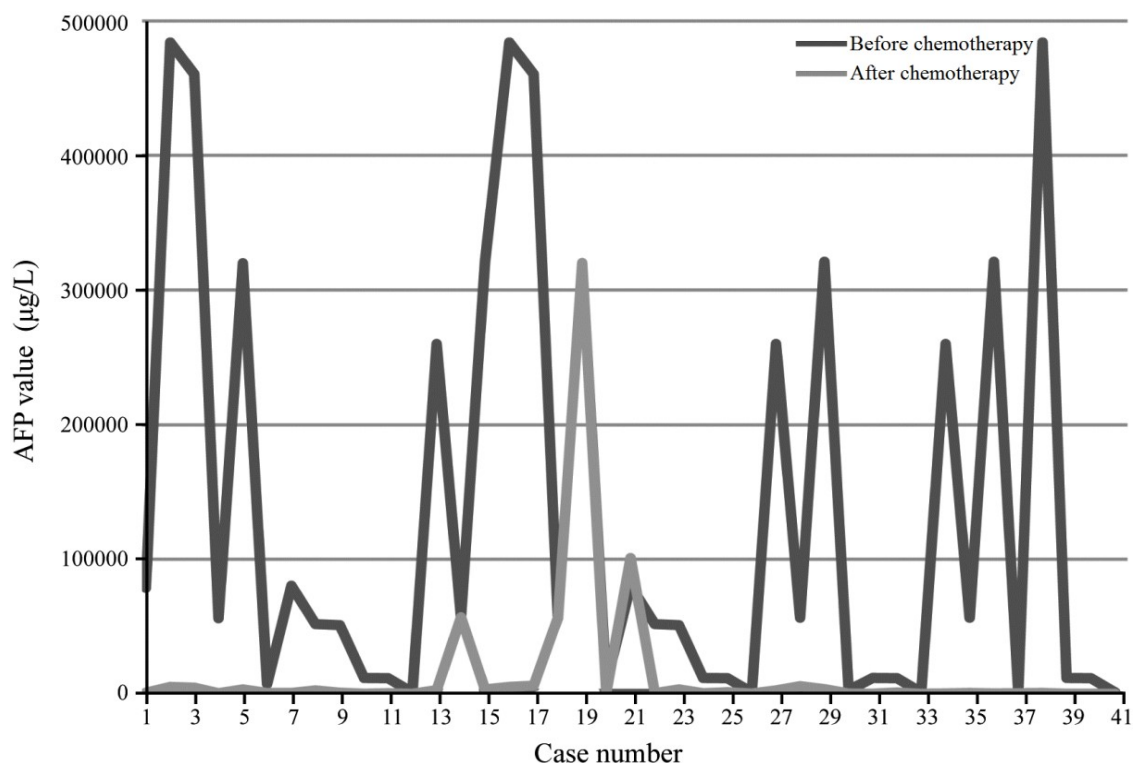


Fig. 1: Changes of serum AFP before and after irinotecan chemotherapy. AFP, alpha-fetoprotein.

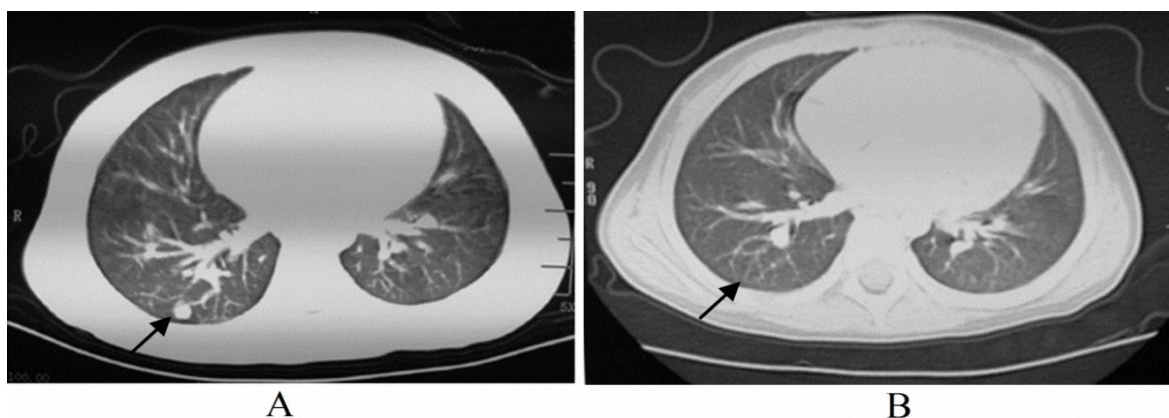


Fig. 2: Changes of pulmonary nodules before and after irinotecan chemotherapy: A: before chemotherapy, the circular metastatic nodules were visible in the right lung (arrow); B: after two cycles of chemotherapy, there was no obvious nodule in the right lung (arrow).

At present, the COG and SIOPEL-based chemotherapy protocols developed by the Children's Cancer Branch of the Chinese Anticancer Association are adopted and it is recommended that PRETEXT-II, III and IV of HB are administered two courses of C5V or C5VD neoadjuvant chemotherapy (cisplatin + fluorouracil + vincristine or cisplatin + fluorouracil + vincristine + doxorubicin) before surgery; moreover, the timing of surgery should be determined based on the AFP level and related imaging findings (Yuan *et al.*, 2016). Therefore, the pediatric patients with PM-HB enrolled in this study were all administered two cycles of the cisplatin + fluorouracil + vincristine + pirarubicin protocol. However, the AFP levels and lung lesions were poorly controlled

Irinotecan has been used as a second-line antitumor drug for the treatment of advanced and recurrent solid tumors in children (Cole *et al.*, 2020). For patients with HB-PM, the replacement with the vincristine + irinotecan (VI) protocol has been confirmed to have a favorable remission rate (O'Neill *et al.*, 2017). The Collagen Gel Droplet-embedded Culture Drug Sensitivity Test in Relapsed Hepatoblastoma provided the basic science background to support future clinical trials of a combination of sorafenib and irinotecan for relapsed or refractory hepatoblastoma (Goto *et al.*, 2017). A report from the Children's Oncology Group AHEP0731 study committee showed that 14 of 30 evaluable patients responded to the administration of two cycles of the VI protocol (Katzenstein *et al.*, 2017). Thus, we used the VI regimen on 5 patients; however, we did not see effects as positive as those previously reported. Nonetheless, we confirmed the effects of the cisplatin + pirarubicin + cyclophosphamide protocol before or after surgery against stage IV of HB (Zhang *et al.*, 2016). Therefore, we added cyclophosphamide and cisplatin to the VI regimen, for which the protocol was vincristine + irinotecan + cyclophosphamide + cisplatin. Thus, the regimen has been administered to patients with lung metastasis that cannot be Get good response using the cisplatin + fluorouracil + vincristine + pirarubicin protocols developed since 2014. In the present study, when treatment of the 41 pediatric patients with HB-PM was replaced with the vincristine + irinotecan + cyclophosphamide + cisplatin protocol, the results showed that there was a significant difference in the AFP level before and after chemotherapy; that is, the AFP level significantly decreased after two cycles of the irinotecan protocol. In addition, among 41 patients, lung lesions completely disappeared in 3 patients, nodules were reduced in 32 patients, nodules showed no obvious change in 5 patients and nodules were enlarged in only one patient; thus, the short-term effective rate was 85.36% (35/41). Therefore, the vincristine + irinotecan + cisplatin + cyclophosphamide protocol was effective for the reduction of AFP levels and the control of lung metastases. In a future study, a prospective cohort study will be conducted to clarify the difference between this regimen and the

C5VD regimen for the treatment of HB with lung metastases.

The common adverse reactions to irinotecan were hematological toxicity and digestive tract reactions. The incidence rates of grade I/II and grade III/IV hematological adverse reactions were 92.68% (38/41) and 7.32% (3/41), respectively. All side effects were completely resolved after the receipt of symptomatic treatment, such as treatment with granulocyte colony-stimulating factor. Therefore, hematological toxicity to irinotecan is tolerable in children.

The gastrointestinal responses of irinotecan were mainly diarrhea, abdominal pain and vomiting. Delayed diarrhea was a dose-limiting toxicity reaction to irinotecan that usually occurred after 5 days of irinotecan application. There have also been reports of pseudomembranous colitis in patients treated with irinotecan. Nausea and vomiting may occur after medication administration and approximately 10% of patients still experience severe nausea or vomiting after the use of antiemetic drugs. To date, the National Comprehensive Cancer Network of the United States (NCCN) has not issued guidelines for the prevention and treatment of chemotherapy-caused diarrhea; however, expert consensus and numerous recommendation guidelines for the intervention and management of chemotherapy-related diarrhea have been published (Robertson *et al.*, 2016; Deng *et al.*, 2020) and used for the development of basic intervention plans for chemotherapy-related diarrhea. Among the adverse reactions occurring in 41 pediatric patients receiving irinotecan-based chemotherapy, delayed diarrhea was the most common, with an incidence of 58.53% (24/41) with 2-17 stools per day, which included 22 cases of grade I/II diarrhea and 2 cases of grade III diarrhea; however, all cases improved after symptomatic treatment, such as use of loperamide, antibiotics and oral rehydration salts. The incidence rate of abdominal pain was 26.83% (11/41) and the incidence of nausea and vomiting was 14.63% (6/41); all cases were grades I/II. However, all acute toxicities were relieved by the 21st day of chemotherapy. Children with HB can tolerate adverse reactions to irinotecan. This is consistent with the results of other study (Katzenstein *et al.*, 2017).

CONCLUSION

In conclusion, although the effects of the C5VD protocol in pediatric patients with HB-PM are unclear, the vincristine + irinotecan + cyclophosphamide + cisplatin protocol, which allows a certain level of curative effects for AFP levels and pulmonary metastasis to be achieved, can be administered. There was a high incidence of delayed diarrhea, but it could be completely relieved by symptomatic treatment.

REFERENCES

- Chinese Anti-Cancer Association Pediatric Committee (2017). China Medical Association Pediatric Onco-surgery Group. Expert consensus for multidisciplinary management of hepatoblastoma (CCCG-HB-2016). *Chin J Pediatr Surg.* **38**(3): 733-739.
- Cole KA, Pal S, Kudgus RA, Ijaz H, Liu X, Minard CG, Pawel BR, Maris JM, Haas-Kogan DA, Voss SD, Berg SL, Reid JM, Fox E and Weigel BJ (2020). Phase I clinical trial of the weel inhibitor adavosertib (AZD1775) with irinotecan in children with relapsed solid tumors: A COG phase I consortium report (ADVL1312). *Clin Cancer Res.* **26**(6): 1213-1219.
- Deng C, Lou Y, Gao Y, Deng B, Su F and Jia L (2020). Efficacy and safety of Shengjiang Xiexin decoction in prophylaxis of chemotherapy-related diarrhea in small cell lung cancer patients: study protocol for a multicenter randomized controlled trial. *Trials*, **21**(1): 370.
- Goto H, Kitagawa N, Sekiguchi H, Miyagi Y, Keino D, Sugiyama M, Sarashina T, Miyagawa N, Yokosuka T, Hamanoue S, Iwasaki F, Shiomi M, Goto S and Tanaka Y (2017). The collagen gel droplet-embedded culture drug sensitivity test in relapsed hepatoblastoma. *J Pediatr Hematol Oncol.* **39**(5): 395-401.
- Ismail H, Broniszczak D, Kaliciński P, Dembowska-Bagińska B, Perek D, Teisseyre J, Kluge P, Kościeszka A, Lembas A and Markiewicz M (2012). Changing treatment and outcome of children with hepatoblastoma: Analysis of a single center experience over the last 20 years. *J. Pediatr. Surg.*, **47**(7): 1331-1339.
- Katzenstein HM, Furman WL, Malogolowkin MH, Krailo MD, McCarville MB, Towbin AJ, Tiao GM, Finegold MJ, Ranganathan S, Dunn SP, Langham MR, McGahren ED, Rodriguez-Galindo C and Meyers RL (2017). Upfront window vincristine/irinotecan treatment of high-risk hepatoblastoma: A report from the Children's Oncology Group AHEP0731 Study Committee. *Cancer*, **123**(12): 2360-2367.
- Meyers RL, Maibach R, Hiyama E, Häberle B, Krailo M, Rangaswami A, Aronson DC, Malogolowkin MH, Perilongo G, von Schweinitz D, Ansari M, Lopez-Terrada D, Tanaka Y, Alaggio R, Leuschner I, Hishiki T, Schmid I, Watanabe K, Yoshimura K, Feng Y, Rinaldi E, Saraceno D, Derosa M and Czauderna P (2017). Risk-stratified staging in paediatric hepatoblastoma: A unified analysis from the children's hepatic tumors international collaboration. *Lancet Oncol.* **18**(1): 122-131.
- O'Neill AF, Towbin AJ, Krailo MD, Xia C, Gao Y, McCarville MB, Meyers RL, McGahren ED, Tiao GM, Dunn SP, Langham MR Jr, Weldon CB, Finegold MJ, Ranganathan S, Furman WL, Malogolowkin M, Rodriguez-Galindo C and Katzenstein HM (2017). Characterization of pulmonary metastases in children with hepatoblastoma treated on Children's Oncology Group Protocol AHEP0731 (The treatment of children with all stages of hepatoblastoma): A report from the Children's Oncology Group. *J. Clin. Oncol.*, **35**(30): 3465-3473.
- Perilongo G, Shafford E, Maibach R, Aronson D, Brugières L, Brock P, Childs M, Czauderna P, MacKinlay G, Otte JB, Pritchard J, Rondelli R, Scopinaro M, Staalman C, Plaschkes J and International Society of Paediatric Oncology-SIOPEL 2 (2004). Risk-adapted treatment for childhood hepatoblastoma. Final report of the second study of the International Society of Paediatric Oncology--SIOPEL 2. *Eur. J. Cancer*, **40**(3): 411-421.
- Powers JM, Pacheco MM and Wickiser JE (2019). Addition of vincristine and irinotecan to standard therapy in a patient with refractory high-risk hepatoblastoma achieving long-term relapse-free survival. *J. Pediatr. Hematol. Oncol.*, **41**(3): e171-e173.
- Robertson JP, Wells CI, Vather R and Bissett IP (2016). Effect of diversion ileostomy on the occurrence and consequences of chemotherapy-induced diarrhea. *Dis. Colon. Rectum.*, **59**(3): 194-200.
- Sunil BJ, Palaniappan R, Venkitaraman B and Ranganathan R (2018). Surgical resection for hepatoblastoma-updated survival outcomes. *J. Gastrointest. Cancer.*, **49**(4): 493-496.
- Tang L, Li X, Wan L, Xiao Y, Zeng X and Ding H (2019). Herbal medicines for irinotecan-induced diarrhea. *Front Pharmacol.* **10**: 182.
- Tang MJ, Yuan XJ, Tan Z, Sheng Q, Zhang Q and Wang LF (2016). Assessment of efficacy of 47 children with hepatoblastoma under multidisciplinary treatment. *Chin. J. Appl. Clin. Pediatr.*, **31**(7): 1175-1179.
- Trobaugh-Lotrario AD, Meyers RL and Feusner JH (2016). Outcomes of Patients With Relapsed Hepatoblastoma Enrolled on Children's Oncology Group (COG) Phase I and II Studies. *J. Pediatr. Hematol. Oncol.*, **38**(3): 187-190.
- Trotti A and Bentzen SM (2004). The need for adverse effects reporting standards in oncology clinical trials. *J. Clin. Oncol.*, **22**(1): 19-22.
- Yuan XJ, Wang HM, Jiang H, Tang MJ, Li ZL, Zou X, Fang YJ, Pan C, Tou JF, Zhang KR, Liu X, Li WS, Li Y, Lu J and Wu YM (2016). Multidisciplinary effort in treating children with hepatoblastoma in China. *Cancer Lett.* **375**(1): 39-46.
- Zhang Y, Zhang W, Tang S, Chen L, Yi Y, Zhang P, Liu A, Zhi T and Huang D (2016). A single-center retrospective study of pediatric hepatoblastoma. *Oncol. Lett.*, **12**(5): 3919-3925.