

Hepatoprotective effect of herbal drug on CCl₄ induced liver damage

Zeeshan Feroz¹, Rafeeq Alam Khan^{2*}, Amber³ and Mahayrookh⁴

¹Ziauddin College of Pharmacy, Ziauddin University, Karachi, Pakistan

²King Saud bin Abdul-Aziz University for Health Sciences, College of Medicine, Jeddah, Kingdom of Saudi Arabia

³Department of Pharmacology, University of Karachi, Karachi, Pakistan

⁴Department of Pharmacology, Dow International Medical College, Dow University of Health Sciences, Karachi, Pakistan

Abstract: Herbs have been a huge source of natural substances used to treat and prevent several illnesses; therefore it is vital to identify the probable toxicity that might take place as a consequence of using herbal combinations.

This study was undertaken in rabbits to investigate the hepatoprotective effects of herbal drug in normal and CCl₄-induced hepatic damage. Herbal drug was tested in 3 different doses, each group comprising of seven rabbits of either sex followed by the administration of CCl₄ with herbal drug and saline for 45 days. Liver function tests and histopathological evaluation were carried out at the end of dosing using standards kits.

The result shows that normal dose of herbal drug (0.43 ml/kg) possess hepatoprotective effects against CCl₄ induced liver damage in rabbits which may be due to the various active ingredients present in herbal drug combination. Present study also suggests that there was a significant (p<0.05) increase in serum alkaline phosphatase and γ -GT in animals kept on high dose of herbal drug (10 ml/kg); however studies on huge number of animals and humans are requisite before reaching to definite conclusion.

Keywords: Liver function tests, Histopathological examination and antihepatotoxic.

INTRODUCTION

Herbal drugs had been extensively used for the treatment of various disorders since prehistoric times and even today most of the medicinal preparations are derived from plants. The recognition of herbal drugs is escalating worldwide owing to minor side effects in comparison to synthetic drugs (Srivastava *et al.*, 2006).

Herbal drugs have been playing an imperative role in improving human sufferings in the primary health care system of rural and remote hilly areas where more than 70% of population depends on traditional system of medicines (Zaidi *et al.*, 1998). The WHO reported that 80% of the world's population relies almost exclusively on traditional medicine for their primary health care (Azaizeh *et al.*, 2003).

Eisenberg and colleagues in 1993 estimated that 34% of adults in the United States use minimum 1 alternative form of health care during the previous year (Astin, 1998). The escalating use of herbal medicines in the society where individuals are also getting prescription drugs suggest that undesirable herb-drug interactions perhaps of important public health consequence (Coxeter *et al.*, 2004). Conventionally, herbs are generally measured to be harmless by the common public owing to their natural origin (Deng, 2002) and have been used for managing numerous health problems globally, though rigorous toxicity resulting from use of herbs has been predictable at many instance, still several people have not

recognized the probable toxicity of herbs (Oduola *et al.*, 2010), therefore this study has been specially designed to evaluate the hepatoprotective effect of herbal drug commonly used in our society without any pharmacological evaluation.

**Eclipta alba hassk* (35 mg leaves and stem), *Picrorrhiza curroa* (35 mg root and rhizome), *Solanum nigrum* (35 mg fruits), *Cichorium intybus* (35 mg seeds), *Glycyrrhiza glabra* (35 mg roots), *Tamarix dioica* (7 mg fruits), *Raphanus sativus* (18 mg seeds), *Berberis aristata* (fruits 14 mg), *Silybum marianum* (70 mg leaves, seeds and fruits), *Spheranthus indicus* (7 mg fruits), *Boerhaavia diffusa* (14 mg leaves and stem) per 10 ml.

MATERIALS AND METHODS

Experimental design and dosing

In present study rabbits were chosen as experimental animals since biochemical changes produced in rabbits are relatively similar as observed in humans; rabbits are easily accessible, easy to handle and cheap (Feroz *et al.*, 2009, 2010 & 2011a; Qamar *et al.*, 2011).

The study was conducted on 42 healthy white rabbits of both sex weighing from 1100-1600 gm. Animals were kept independently in cages, under controlled climatic room (23±2°C) and humidity (50-60%), during the entire study in an alternating 12-h of light/dark cycle.

All animals were uniformly divided into six groups. Each group comprising of seven animals. Groups received drugs orally in following pattern:

*Corresponding author: e-mail: rkhan1959@gmail.com

- Group A: Control group received saline only
- Group B: Normal dose of herbal drug (0.43 ml/kg)
- Group C: Moderate dose of herbal drug (5 ml/kg)
- Group D: High dose of herbal drug (10 ml/kg)
- Group E: CCl₄ (0.5 ml/kg)
- Group F: CCl₄+ Normal dose of herbal drug

Sample collection

Blood sample of approximately 5cc was collected in gel tubes via cardiac puncture technique (Feroz *et al.*, 2011b) at the end of dosing i.e. 46th day. Serum was separated by centrifugation (Heraeus, Christ Labofuge A) at 4000 rpm for 8 minutes.

Assessment of hepatic parameters

Alkaline phosphatase, γ -glutamyl transferase (γ -GT), alanine transaminases (ALT), aspartate transaminases (AST), total bilirubin and direct bilirubin were analyzed within 3 h of sample collection on vita lab eclipse automatic analyzer (Merck) at 37°C using standard reagent kits supplied by Merck.

Microscopic tissue examination

Microscopy of randomly selected liver was carried out to look for microscopic changes. Tissue sections of 3 to 4 micron thickness were cut from the wax blocks by rotary manual microtome. The tissue sections were mounted on slides and were dried gently by pressing with filter paper. The mounted slides were placed initially in an incubator at 37 °C overnight to dry. This is followed by standard staining procedure for histopathological analysis

STATISTICAL ANALYSIS

All values were compared with control by taking mean and standard error to the mean using t-test, value of p<0.05 were considered as significant.

RESULTS

Mortality Rate

Table 1 shows the comparison of mortality rate of animals kept on herbal drug in normal, moderate and high doses for 45 days. 28.5% death was reported in animals

received high dose.71.4 % death was reported in animals kept on CCl₄. However no death was observed in the animals of control group and animals received normal, moderate dose and herbal drug with CCl₄.

Table 1: Overall comparison of percentage mortality rate

Animal groups	Mortality rate
Control	0/7 (00.00)
Normal Dose	0/7(00.00)
Moderate Dose	0/7(00.00)
High Dose	2/7(0.285)
CCl ₄	5/7 (0.714)
Normal Dose + CCl ₄	0/7 (00.00)

Hepatic parameters

Table 2 discloses the comparison of alkaline phosphatase, ALT, AST, γ -GT, total and direct bilirubin at normal, moderate and high doses of herbal drug for a period of 45 days.

Animals received normal, moderate and high dose showed significant increase in the level of alkaline phosphatase i.e. 115.57 \pm 23.85 μ /l, 80.14 \pm 15.10 μ /l, 109.14 \pm 22.90 μ /l as compared to control animals i.e. 38.29 \pm 8.57 μ /l. There was also a significant increase in the level of γ -GT in animals kept on high dose of herbal drug i.e. 7.57 \pm 0.97 μ /l as compared to control animals 3.57 \pm 0.97 μ /l. Conversely there were no significant changes in the level of other hepatic parameters at the end of dosing.

Table 3 discloses the comparison of hepatic parameters of control animals and animals received CCl₄+ herbal drug for a period of 45 days. There were no significant changes in any of the hepatic parameter at the completion of dosing.

Microscopic tissue examination

Gross examination of liver did not show any macroscopic alteration in any group. Similarly microscopic examination of hepatic tissue of control animals and animals kept on herbal drug + CCl₄ also did not reveal any microscopic changes (fig. 1).

Table 2: Comparison of hepatic parameters following administration of herbal drug in different doses for 45 days

Parameters	Animal Groups			
	Control	Normal Dose	Moderate Dose	High Dose
Alkaline phosphatase (μ /l)	38.29 \pm 8.57	115.57 \pm 23.85*	80.14 \pm 15.10*	109.14 \pm 22.90*
ALT (μ /l)	71.43 \pm 7.49	76.43 \pm 24.28	113.86 \pm 17.79	109.86 \pm 28.67
AST (μ /l)	52.71 \pm 10.55	74.57 \pm 21.00	35.86 \pm 7.21	59.86 \pm 12.76
γ -GT (μ /l)	3.57 \pm 0.97	5.86 \pm 0.80	7.43 \pm 0.721	7.57 \pm 0.97*
Total bilirubin (mg/dl)	0.43 \pm 0.08	0.81 \pm 0.38	0.70 \pm 0.21	0.56 \pm 0.20
Direct bilirubin (mg/dl)	0.16 \pm 0.04	0.23 \pm 0.05	0.18 \pm 0.06	0.13 \pm 0.04

n = 7, Average values \pm S.E.M., *p <0.05 significant as compared to control.

Conversely microscopic examination of hepatic tissue in animals kept on normal and moderate dose of herbal drug shows inflammatory changes (fig. 2). Whereas animals kept on high dose shows mild patchy necrosis as compared to control animals (fig. 3). Microscopic examination of hepatic tissue of animals kept on CCl₄ shows patchy necrosis with inflammatory changes (fig.4).

DISCUSSION

Herbal medicines have been known to self-prescribe by the patients for health maintenance and treatment of minor ailment and chronic illnesses (Aziz and Tey, 2009). A huge number of patients use medicinal herbs; therefore, physicians should be aware about the benefits and risks of popular medicinal herbs (O'Hara et al., 1998), hence present study has been specially designed to evaluate the

hepatoprotective effect of herbal drug used in our society without any pharmacological assessment.

Animals of neither group showed gross toxicities at any stage during the entire duration period of drug administration, however average loss of weight was found during some intervals of experiment. Initial loss in weight of animals might be due to the change in environment that was gradually recovered.

Liver function tests are useful in identifying hepatic dysfunction (Kim, 2008; Thapa and Walia, 2007; Astegiano et al., 2004; Martin-Lopez et al., 1993). Since liver executes a variety functions, no single test is adequate to offer complete estimate of liver functions (Kim, 2008; Astegiano et al., 2004). Present study did not reveal any significant changes in the level of γ -GT, AST,

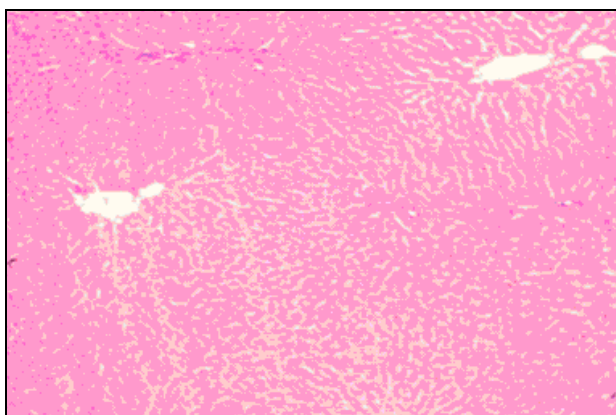


Fig. 1: Liver showing no remarkable changes.




Fig. 2: Liver showing inflammatory changes.




Fig. 3: Liver showing mild patchy necrosis.




Fig. 4: Liver showing mild patchy necrosis with inflammatory response.

Table 3: Comparison of hepatic parameters following administration of ccl₄ and normal dose of herbal drug for 45 days

Parameters/ Groups	ALP μ /l	ALT μ /l	AST μ /l	γ -GT μ /l	Total Bilirubin mg/dl	Direct Bilirubin mg/dl
Control	38.29 \pm 8.57	71.43 \pm 7.49	52.71 \pm 10.55	3.57 \pm 0.97	0.43 \pm 0.08	0.16 \pm 0.04
CCl ₄ + herbal drug	57.7 \pm 10	60.9 \pm 9.7	31.9 \pm 6.7	6.43 \pm 2.2	0.98 \pm 0.20	0.11 \pm 0.02

n = 7, Average values \pm S.E.M.

ALT, total and direct bilirubin in animals kept on normal and moderate doses, however there was significant increase in the level of alkaline phosphatase which may be due to disturb bone metabolism, since elevation in serum alkaline phosphatase is predominantly initiated from liver as well as bone (Renner and Dallenbach, 1992). While microscopic examination of hepatic tissue shows mild inflammatory changes (fig. 2), illustrating no remarkable changes in the hepatic tissue of these animals, hence it is not an indication of hepatic damage. On the contrary animals kept on high dose of herbal drug showed significant elevation in the level of alkaline phosphatase and γ -GT. Microscopic examination of hepatic tissue of these animals shows mild patchy necrosis (fig. 3), thus simultaneous elevation of alkaline phosphatase and γ -GT along with histological changes and increased mortality rate might be indicator of hepatic damage.

In present study hepatotoxicity was induced in rabbits using carbon tetrachloride (CCl₄) in a dose of 0.5 ml/kg for a period of 45 days. Microscopic examination of hepatic tissue of animals received CCl₄ only shows patchy necrosis with inflammatory changes (fig. 4). There are studies which show that per oxidation of CCl₄ induced liver damage was modeled in monolayer cultures of rat primary hepatocytes with a focus on involvement of covalent binding of CCl₄ metabolites to cell components and per oxidative damage as the cause of injury (Boll *et al.*, 2001; Deshwal *et al.*, 2011). In the liver, microsomal oxidizing systems produce reactive metabolites of CCl₄ such as trichloromethyl radical (CCl₃) or trichloroperoxy radical (CCl₃ O[•]). These free radicals cause lipid peroxidation which produces hepatocellular damage and enhances production of fibrotic tissue (Marotta *et al.*, 2003; Ulican *et al.*, 2003). Animals received CCl₄ with the herbal drug in normal dose (0.43 ml/kg) did not reveals any remarkable microscopic changes in the hepatic tissues (fig. 1), hence it may be concluded that herbal drugs combination used in present study possess hepatoprotective effects against CCl₄ induced liver damage in animals which may be due to the various active ingredient present in this combination such as *Eclipta Alba Hassk* (Handa, 1986), *Berberis aristata* (Gilani and Janbaz, 1995), *Picrorrhiza curroa* (Chander *et al.*, 1990), *Solanum nigrum* (Lin *et al.*, 2008), *Cichorium intybus* (Heibatollah *et al.*, 2008), *Glycyrrhiza glabra* (Yin *et al.*, 2011), *Spheranthus indicus* (Galani *et al.*, 2010), *Boerhaavia diffusa* (Rawat *et al.*, 1997) which have been reported to produce hepatoprotective effects due to the presence of flavonoids in them since they remove the free radical causing hepatic damage.

CONCLUSION

Present study was carried out to investigate the effect of herbal combination on hepatic parameters. The preparation was administered at three different doses i.e.

0.43ml kg, 5ml kg, 10ml kg of body weight. Overall results did not reveal any significant toxicity. However there had been significant increase in the level of alkaline phosphatase and γ -GT in animals kept on high dose of herbal drug which is important in relation to histopathological examination of liver, which shows mild patchy necrosis. Present study provide valuable information pertaining gross toxicities, microscopic changes and hepatoprotective effects of herbal drug in CCl₄ induced hepatotoxicity in rabbits, however studies on large number of animals and humans are required before reaching to any conclusion.

ACKNOWLEDGEMENT

Authors are thankful to Herbion Pakistan Pvt. Limited for providing their product and financial assistance for this piece of work.

REFERENCES

- Astegiano M, Sapone N, Demarchi B, Rossetti S, Bonardi R and Rizzetto M (2004). Laboratory evaluation of the patient with liver disease. *Eur. Rev. Med. Pharmacol. Sci.*, **8**(1): 3-9.
- Astin JA (1998). Why patients use alternative medicine: results of a national study. *JAMA*, **279**(19): 1548-1553.
- Azaizeh H, Fulder S, Khalil K and Said O (2003). Ethnomedicinal knowledge of local Arab practitioners in the Middle East Region. *Fitoterapia*, **74**: 98-108.
- Aziz Z and Tey NP (2009). Herbal medicines: Prevalence and predictors of use among Malaysian adults. *Complement. Ther. Med.*, **17**(1): 44-50.
- Boll M, Weber IW, Becker E and Stampfl A (2001). Mechanism of carbon tetrachloride-induced hepatotoxicity. Hepatocellular damage by reactive carbon tetrachloride metabolites. *Z. Naturforsch. C.*, **56**(7-8): 649-659.
- Chander R, Dwivedi Y, Rastogi R, Sharma SK, Garg NK, Kapoor NK and Dhawan BN (1990). Evaluation of hepatoprotective activity of picroliv (from *Picrorrhiza kurroa*) in *Mastomys natalensis* infected with *Plasmodium berghei*. *Indian J. Med. Res.*, **92**: 34-37.
- Coxeter PD, McLachlan AJ, Duke CC and Roufogalis BD (2004). Herb-drug interactions: An evidence based approach. *Curr. Med. Chem.*, **11**(11): 1513-1525.
- Deng J (2002). Clinical and laboratory investigations in herbal poisonings, *Toxicology*, **181-182**: 571-576.
- Deshwal N, Sharma AK and Sharma P (2011). Review on hepatoprotective plants. *Int. J. Pharm. Sci. Rev. Res.*, **7**(1): 15-26.
- Eisenberg DM, Kessler RC, Foster C, Norlock PE, Calkins Dr and Delbanco TL (1993). Unconventional medicine in United State. *New Engl. J. Med.*, **328**: 246-252.
- Feroz Z, Khan RA and Afroz S (2009). Effect of multiple drug administration on gross toxicities and electrolytes. *Pak. J. Pharmacol.*, **26**(2): 33-39.

- Feroz Z, Khan RA and Afroz S (2011a). Adverse effects of antiepileptic, antihypertensive, antidiabetic and antiarrhythmic drugs on hematological and hepatic parameters. *Lat. Am. J. Pharm.*, **30**(2): 229-236.
- Feroz Z, Khan RA and Afroz S (2011b). Cumulative toxicities on lipid profile and glucose following administration of antiepileptic, antihypertensive, antidiabetic and antiarrhythmic drugs. *Pak. J. Pharm. Sci.*, **24**(1): 47-51.
- Feroz Z, Khan RA, Mirza T and Afroz S (2010). Adverse effects of cumulative administration of anti-epileptic, anti-hypertensive, anti-diabetic, anti-arrhythmic drugs on renal and cardiac parameters. *Int. J. Med. Res.*, **1**(1): 39-47.
- Galani VJ, Patel BG and Rana DG (2010). *Sphaeranthus indicus* Linn. A phytopharmacological review. *Int. J. Ayurveda. Res.*, **1**(4): 247-253.
- Gilani AH and Janbaz KH (1995). Preventive and curative effects of *Berberis aristata* fruit extract on paracetamol- and CCl₄-induced hepatotoxicity. *Phytother Res.*, **9**(7): 489-494.
- Handa SS, Sharma A and Chakarborty KK (1986). Natural Products and plants as liver protecting drugs. *Fitoterapia.*, **57**(5): 307-352.
- Heibatollah S, Reza NM, Izadpanah G and Sohailla S (2008). Hepatoprotective effect of *Cichorium intybus* on CCl₄-induced liver damage in rats. *Afr. J. Biochem. Res.*, **2**(6): 141-144.
- Kim YJ (2008). Interpretation of liver function tests. *Korean J. Gastroenterol.*, **51**(4): 219-224.
- Lin HM, Tseng HC, Wang CJ, Lin JJ, Lo CW and Chou FP (2008). Hepatoprotective effects of *Solanum nigrum* Linn extract against CCl₄-induced oxidative damage in rats. *Chem. Biol. Interact.*, **171**(3): 283-293.
- Marotta F, Shield YR, Bamba T, Naito Y, Minelli E and Yoshioka M (2003). Hepatoprotective effect of *Curcumin absinthium* compound in experimental server liver injury. *Chinese. J. Diges. Disease.*, **4**: 122-127.
- Martin-Lopez E, Diaz L and Martinez F (1993). Liver function tests. *Rev. Gastroenterol. Mex.*, **58**(2): 144-153.
- Oduola T, Bello I, Adeosun G, Ademosun A, Raheem G and Avwioro G (2010). Hepatotoxicity and nephrotoxicity evaluation in Wistar albino rats exposed to *Morinda lucida* leaf extract. *N. Am. J. Med. Sci.*, **2**(5): 230-233.
- O'Hara M, Kiefer D, Farrell K and Kemper K (1998). A Review of 12 commonly used medicinal herbs. *Arch. Fam. Med.*, **7**(6): 523-536.
- Qamar F, Afroz S, Feroz Z, Siddiqui S and Ara A (2011). Evaluation of hypoglycemic effect of *Cassia italica*. *J. Basic. Appl. Sci.*, **7**(1): 61-64.
- Rawat AK, Mehrotra S, Tripathi SC and Shome U (1997). Hepatoprotective activity of *Boerhaavia diffusa* L. roots – a popular Indian ethnomedicine. *J. Ethnopharmacol.*, **56**(1): 61-66.
- Renner EL and Dallenbach A (1992). Increased liver enzymes: what should be done? *Ther. Umsch.*, **49**(5): 281-286.
- Srivastava SK, Rai V, Srivastava M, Rawat AKS and Mehrotra S (2006). Estimation of heavy metals in different *Berberis* Species and its Market Samples. *Environ. Monit. Assess.*, **116**: 315-320.
- Thapa BR and Walia A (2007). Liver function tests and their interpretation. *Indian J. Pediatr.*, **74**(7): 663-671.
- Ulican O, Greksak M, Vancova O, Zlatos L, Galbavy S, Bozek P and Nakano M (2003). Hepatoprotective effect of Rooibos tea (*Aspalathus linearis*) on CCl₄ induced liver damage in rats. *Physiol Res.*, **52**: 461-466.
- Yin G, Cao L, Xu P, Jeney G, Nakao M and Lu C (2011). Hepatoprotective and antioxidant effects of *Glycyrrhiza glabra* extract against carbon tetrachloride (CCl₄)-induced hepatocyte damage in common carp (*Cyprinus carpio*). *Fish Physiol Biochem.*, **37**(1): 209-216.
- Zaidi SH (1998). Existing indigenous medicinal plant resources of Pakistan and their prospects for utilization. *Pak. Forest Jour.*, **48**(2): 5-7.