

Anti-inflammatory and gastroprotective activities of the aqueous extract of *Micromeria fruticosa* (L.) Druce ssp *Serpyllifolia* in mice

Eman Abu-Gharbieh^{1*}, Naglaa Gamil Shehab² and Saeed Ahmed Khan³

¹Department of Pharmacology and Therapeutics, Dubai Pharmacy College, Dubai, UAE

²Department of Pharmacognosy, Faculty of Pharmacy, Cairo University, Egypt

³Department of Pharmaceutical and Medicinal Chemistry, Dubai Pharmacy College, Dubai, UAE

Abstract: *Micromeria fruticosa* is used widely in many Mediterranean regions for various inflammatory conditions. The aim of this work was to assess the anti-inflammatory and gastroprotective activities of the aqueous extract of *Micromeria fruticosa*. The aqueous extract of *Micromeria fruticosa* was tested orally in mice at doses of 50, 100 and 200 mg/kg in carrageenan-induced paw edema, vascular permeability, myeloperoxidase activity (MPO) and indomethacin-induced gastric ulceration. In the paw edema model, the extract at dose of 200 mg/kg, exhibited a significant anti-inflammatory effect, while the extract at 100 and 200 mg/kg reduced significantly the vascular permeability and MPO activity in a dose dependant manner. Oral pretreatment of the aqueous extract reduced significantly the development of gastric lesions induced by indomethacin at dose of 200 mg/kg only. Results suggest that the aqueous extract of *Micromeria fruticosa* has both anti-inflammatory as well as, gastroprotective activities. Thus it could be used as an alternative or supplementary herbal remedy for the treatment of inflammatory diseases especially when combined with strong anti-inflammatory medications that have ulcerogenic side effects such as NSAIDs.

Keywords: *Micromeria fruticosa*; Gastroprotective; Vascular permeability; Myeloperoxidase activity.

INTRODUCTION

Micromeria fruticosa (L.) Druce ssp *serpyllifolia* (Lamiaceae) is used widely in many Mediterranean regions for various inflammatory conditions and in wound healing. The plant is also used for many gastrointestinal ailments including abdominal pain and diarrhea (Dafni *et al.* 1984; Yaniv *et al.* 1982). Although the plant and its extract are used extensively in the folk medicine, no scientific evidences are available in literature to support its medical uses. Therefore, in the present study we studied plausible anti-inflammatory activity of the plant's aqueous extract and also thought worthwhile to evaluate the gastroprotective activity, to be advantages over the classical non-steroidal anti-inflammatory drugs that are potentially exert adverse effects on the gastrointestinal tract.

MATERIALS AND METHODS

Animals

Male albino mice weighing 25 ± 5 g were used. They were kept under standard conditions of light and dark cycle and had free access to food and tap water. The animals were fasted for 24 h before the experiments and allowing water ad libitum. The experimental protocol was approved by the Research Committee in Dubai Pharmacy College. Animal welfare and experimental procedures were carried out according to the guide for the care and use of laboratory animals (NIH, 1996).

Drugs and chemicals

Carrageenan, indomethacin, hexa-decyltrimethyl ammoniumromide (HTAB), o-dianisidine, hydrogen peroxide, omeprazole and carboxymethyl cellulose (CMC) were purchased from Sigma-Aldrich.

Plant material

The aerial parts of the *Micromeria fruticosa* were collected before the flowering stage in March 2010, from Nablus in Palestine. Taxonomy identification was confirmed by Taxonomy Department, Faculty of Science, Cairo University, Egypt. Plant materials were air-dried and then grounded to course powder.

A voucher specimen was deposited at the Herbarium of the Department of Pharmacognosy, Faculty of Pharmacy, Cairo University, Egypt.

Preparation of *Micromeria fruticosa* extract (MFE)

300 g of aerial parts of the plant were macerated in warm-distilled water (1L×2) and kept in refrigerator for three days, and then filtered. The combined aqueous extracts were lyophilized and it yielded 11.24 g.

Carrageenan induced paw edema

The edema was induced in mice paws by injecting of 25 μ l of (1% w/v) carrageenan suspension in saline (Winter CA *et al.* 1962). Fasted mice were deprived of food for 18 hrs and divided into five groups of six animals each. Control group received the vehicle (CMC) orally, reference group received indomethacin (8 mg/kg, p.o.) in CMC and the test groups were treated with MFE at

*Corresponding author: e-mail: emanfa@yahoo.com

different doses (50, 100 and 200 mg/kg in a 1% w/v CMC, p.o.). The paw edema was induced one hour post-treatments in all groups.

The swelling induced by carrageenan in the hind-paws was measured three hours after carrageenan injection. Degree of swelling was assessed a/b ratio, where a and b represent the total volumes of both paws post and pre carrageenan treatment, respectively. A ratio less than 1.5 post treatment was considered a significant inhibitory effect (Chi and Jun 1990).

Assay for myeloperoxidase activity

The animals from different groups were sacrificed by excess diethyl-ether four hours post carrageenan injection. The paws were weighed and the myeloperoxidase activity was assessed using a modified myeloperoxidase (MPO) assay as described by Bradley *et al.* (1982). The tissue was homogenized in phosphate buffer at pH 6.0 containing 0.5% HTAB at 0°C for 45 sec and then centrifuged at 3,000 rpm for 25 min at 4°C. The MPO activity was measured by adding 50µl of the following: supernatant, phosphate buffer containing 0.5% HTAB and o-dianisidine. The reaction started by adding 50µl of freshly prepared 0.003% hydrogen peroxide. The change in absorbance at 450nm was measured by spectrophotometer (UV-1700 PharmaSpec, Shimadzu, Japan).

Acetic acid-induced vascular permeability

The mice were divided into five groups (6 mice/each) and deprived of food for ten hours prior to the experiment. The test drugs (0.5 mg/kg dexamethasone, 50, 100 and 200 mg/kg MFE) or a vehicle (CMC) were orally administered to the mice. Then each mouse received Evans blue dye (1%, i.v.) 30min after the oral treatment. 0.6% acetic acid in saline was then injected intraperitoneally at 30min post Evans blue injection. After 20min, the mice were sacrificed by neck dislocation and 10ml of normal saline were injected intraperitoneally, and the wash solution was aspirated and centrifuged at 2,000 rpm for 10 min. The supernatant absorbance was measured at 610nm using a spectrophotometer. Vascular permeability was expressed as the amount of the total dye (µg/mouse) leaked into the intraperitoneal cavity (Whittle 1964).

Indomethacin-induced ulcer in mice

Animals were divided into five groups with six mice per each. Gastric ulcerations were induced by oral administration of indomethacin (20 mg/kg in 1% CMC). The animals were fasted for 15 hours. The MFE (50, 100, and 200 mg/kg), vehicle (1% w/v CMC), or omeprazole (3 mg/kg, as positive standard drug) were administered orally 60 min before indomethacin administration. Eight hours after ulcer induction, the animals were sacrificed by cervical dislocation and their stomachs were extracted and opened along the greater curvature (Molina *et al.*, 2005) and the tissues were proceed for macroscopic and microscopic assessment.

Macroscopic damage score assessment

The gastric mucosal areas were evaluated using a transparent sheet and a dissecting microscope. The mucosal damage was scored based on the severity of hyperemia and erosions by grading it on a 0 to 4 scale as following: 0: normal mucosa; 0.5: mild hyperemia; 1: one or two lesions; 2: severe lesions; 3: very severe lesions and 4: full of lesions. The macroscopic data are presented as mean ±S.E.M. (Dokmeci *et al.*, 2005).

Microscopic damage score assessment

For histopathological study, three samples from each stomach were cut out and fixed in 10% formalin solution. Sections of 5 µm thickness were stained with hematoxylin and eosin (H&E) and examined under a light microscope after they were coded. 1 cm length of each histological section was divided into three fields. Each field was scored histologically based on a 0-4 scale system as following: 0: normal epithelial cell; 1: damage epithelial cell; 2: upper mucosal vasocongestion, glandular disruption or edema; 3: lower mucosal disruption, vasocongestion or edema and 4: extensive full thickness mucosal damage. The mean score value of each field was considered as histological ulcer index for that section (Esplugues and Whittle 1989).

STATISTICAL ANALYSIS

The data were expressed as mean ± SEM, statistical analysis was performed by one way ANOVA followed by Bonferroni's multiple comparison test, *p* values <0.05 were considered as significant.

RESULTS

Carrageenan induce edema in mice

The toxicity study for the aqueous extract have been reported previously to be safe up to dose of 5 g/kg (Shehab and Abu-Gharbieh 2012). Carrageenan injection in the paw caused maximal swelling at 3 h post-injection and the mean increase in volume at that time was about 100% (a/b~2) in control inflamed group. Data analysis shows that MFE reduced the edema in a dose dependant manner compared to the inflamed group and it was statistically significant at the dose of 200 mg/kg (*p*<0.05) as shown in table 1.

Myeloperoxidas activity

Carrageenan injection into the mice paws is known to caused extensive cellular infiltration(Kang *et al.*, 2008). MPO activity was significantly increased after carrageenan injection as shown in fig. 1. Administration of plant extract at doses of 50, 100 and 200 mg/kg resulted in dose dependant reduction of MPO activity. Treatment at doses of 100 and 200 mg/kg of MF extract significantly inhibited MPO activity by 55.4% and 77.4%, respectively (fig. 1).

Vascular permeability

Administration of the plant extract at doses of 100 and 200 mg/kg significantly reduced the dye leakage into the peritoneal cavity by 40.7% and 68.3% respectively as shown in table 2.

Macroscopic damage score

Macroscopic lesions with obvious borderlines in different forms and sizes were dispersed randomly on the stomachs surfaces of the indomethacin treated animals (control group). Animals treated with the plant extract at doses of 100 and 200 mg/kg showed a significant dose-dependent gastric mucosal protection compared to the control group ($p < 0.05$), as shown in fig. 2.

Microscopic damage score

Histopathological study confirmed that the pretreatment with the aqueous plant extract prevented indomethacin-induced microscopical damage in the gastric mucosa as shown in fig. 2. Indomethacin administration induced a disruption of the gastric gland with evident epithelial cell loss (fig 3, a). Histological analysis showed that the MFE at dose of 200 mg/kg significantly prevented this damage ($p < 0.05$) (fig. 3d), while the MFE at doses of 50 and 100 mg/kg showed no or lesser degree of protection respectively (figs. 3, b and c respectively).

DISCUSSION

Phytochemical analysis of the essential oil and aqueous extract of *Micromeria fruticosa* that will be published shortly showed that they are rich in flavonoid and terpenoidal compounds (Shehab and Abu-Gharbieh 2012). Many literature support their various pharmacological activity like analgesic and anti-inflammatory actions (Li et al., 2003; Taesotikul et al., 2003; Della et al., 1986).

The anti-inflammatory effects of MF extract were assessed by carrageenan-induced paw edema, acetic acid-induced vascular permeability models and MPO activity *in vivo*.

During the progression of carrageenan-induced edema the prostaglandins are considered as the main inflammatory mediator at the late stage, while histamine, bradykinin and serotonin are extensively released in the early stage ((Della et al. 1986; Winter CA et al. 1962; Muniappan and Sundararaj 2003). Therefore, the significant anti-inflammatory effect shown by the aqueous extract on those models represents in part the ability of the extract to inhibit prostaglandins and this activity may be attributed to the flavonoids and/or terpenoidal contents.

On the other hand, myeloperoxidase enzyme is involved in tissue inflammation reaction, and the anti-inflammatory activity of many drugs have been attributed to their ability to inhibit the leukocytic MPO release (Kettle and Winterbourn 1991). A previous study had demonstrated the ability of MF extract to inhibit MPO activity *in vitro* (Abu-Gharbieh et al. 2010). The MPO activity was reduced significantly by the plant extract and this confirms its strong effect on the cellular migration, primarily due to polymorphonuclear leukocytes (Fernandez et al. 2001)

Furthermore, indomethacin-induced gastric ulceration basically resulted from two main mechanisms; a direct local irritating effect that lead to mucosal barrier disruption and the systemic reduction of mucosal protection due to cyclooxygenase inhibition in gastric.

Table 1: Anti-inflammatory effect of MFE on carrageenan-induced paw edema 3 h post-carrageenan injection

Treatment	Dose mg/kg (p.o.)	Degree of swelling (a/b)	Edema inhibition (%)
Control	-	1.98±0.011	0
Indomethacin	8	1.16±0.023*	83
MFE	50	1.61±0.013	38
MFE	100	1.52± 0.021	47
MFE	200	1.19± 0.022*	80

Value represents mean ± S.E.M. for 6 animals. (* $a/b < 1.5$); *a* and *b* are total volumes of both hind paws after and before carrageenan treatment respectively.

Table 2: Anti-inflammatory effect of MFE on acetic acid -induced vascular permeability in mice

Treatment	Dose mg/kg (p.o.)	Day leakage µg	Leakage inhibition (%)
Control	-	95.5±4.3	0.0
Dexamethasone	0.5	22.3±2.9	76.7
MFE	50	88.8 ±5.7	7.0
MFE	100	56.6± 4.6	40.7*
MFE	200	30.3± 3.1	68.3*

Value represents mean ± S.E.M. for 6 animals (* $p < 0.05$)

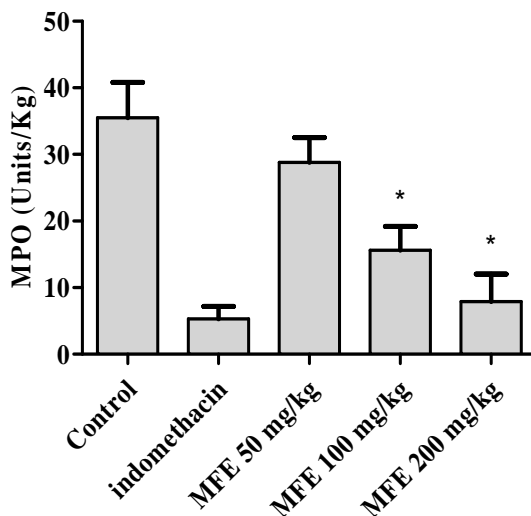


Fig. 1: MPO activity of the aqueous extract of *Micromeria fruticosa* in carrageenan-induced paw edema in mice

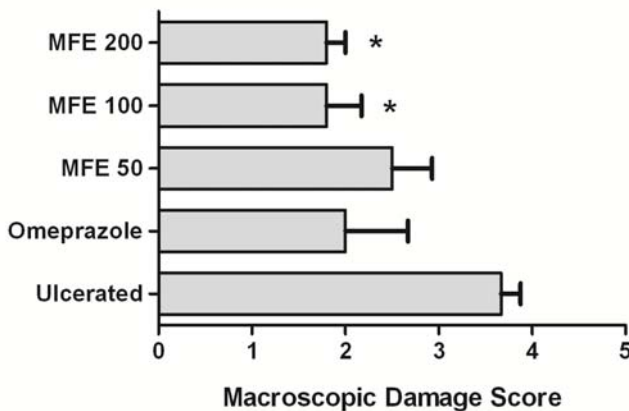


Fig. 2: Macroscopic damage score in indomethacin-induced gastric ulcer model, * $p < 0.05$

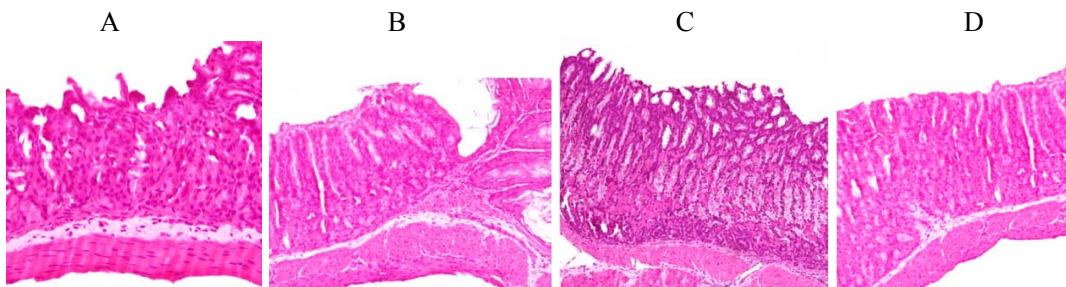


Fig. 3: Sections of hematoxylin and eosin (HE) staining, X 100 (a-d). Section through gastric mucosa in the sham treated groups. (a): Microscopic appearance of lesions induced by indomethacin in gastric mucosa pretreated with vehicle; (b): Microscopic appearance of stomach showing sharply demarcated deep ulcer at dose of 50 mg/kg of MFE; (c): Microscopic appearance of stomach section revealing erosion of the superficial lining of mucosal epithelium pretreated with 100 mg/kg MFE and (d): Microscopic appearance of stomach section revealing intact mucosal epithelium pretreated with 200 mg/kg MFE

mucosa (Scarpignato 1995). Furthermore, *in vivo* studies had shown that indomethacin activates the neutrophils locally causing a release of many inflammatory mediator including MPO, proteases, and free radicals (Scarpignato

1995). Therefore the inhibitory activity of MF extract on the neutrophilic release of MPO and other inflammatory mediators could be in part responsible for the gastroprotective activity of this extract. Nevertheless,

further studies are needed to reveal the exact mechanism of anti-ulcer activity.

CONCLUSION

This study provides evidence that the aqueous extract of *Micromeria fruticosa* has both anti-inflammatory as well as, gastroprotective activities. Thus it could be used as an alternative herbal remedy in the management of inflammatory disorders especially when combined to strong anti-inflammatory medications that are known for their ulcerogenic side effects such as NSAIDs.

ACKNOWLEDGMENT

The authors would especially like to thank Lama Lozon, Maimona Jairoon, Arwa Kassim and Samira Maher for helping us in this study

REFERENCES

- Abu-Gharbieh E, Bustanji Y and Mohammad M (2010). *In vitro* effects of *Micromeria fruticosa* on human leukocyte myeloperoxidase activity. *J. Pharm. Res.* **3**(10): 2492-2493.
- Bradley PP, Priebe DA, Christensen RD and Rothstein G (1982). Measurement of cutaneous inflammation: Estimation of neutrophil content with an enzyme marker. *J. Invest. Dermatol.*, **78**(3): 206-209
- Chi SC and Jun HW (1990). Anti-inflammatory activity of ketoprofen gel on carrageenan-induced paw edema in rats. *J. Pharm. Sci.*, **79**(11): 974-977
- Dafni A, Yaniv Z and Palevitch D (1984). Ethnobotanical survey of medicinal plants in northern Israel. *J. Ethnopharmacol.*, **10**(3): 295-310.
- Della LR, Tubaro A, Dri P, Zilli C and Del NP (1986). The role of flavonoids in the antiinflammatory activity of *Chamomilla recutita*. *Prog. Clin. Biol. Res.*, **213**: 481-484.
- Dokmeci D, Akpolat M, Aydogdu N, Doganay L and Turan FN (2005). L-carnitine inhibits ethanol-induced gastric mucosal injury in rats. *Pharmacol. Rep.*, **57**(4): 481-488.
- Espugues JV and Whittle BJ (1989). Gastric damage following local intra-arterial administration of reactive oxygen metabolites in the rat. *Br. J. Pharmacol.*, **97**(4): 1085-1092.
- Fernandez A, Alvarez A, Garcia MD and Saenz MT (2001). Anti-inflammatory effect of *Pimenta racemosa* var. *ozua* and isolation of the triterpene lupeol. *Farmacol.*, **56**(4): 335-338.
- Kang OH, Chae HS, Oh YC, Choi JG, Lee YS, Jang HJ, Kim JH, Kim YC, Sohn DH, Park H and Kwon DY (2008). Anti-nociceptive and anti-inflammatory effects of *Angelica dahuricae radix* through inhibition of the expression of inducible nitric oxide synthase and NO production. *Am. J. Chin. Med.*, **36**(5): 913-928.
- Kettle AJ and Winterbourn CC (1991). Mechanism of inhibition of myeloperoxidase by anti-inflammatory drugs. *Biochemical Pharmacology*, **41**(10): 1485-1492.
- Li RW, David LG, Myers SP and Leach DN (2003). Anti-inflammatory activity of Chinese medicinal vine plants. *J. Ethnopharmacol.*, **85**(1): 61-67.
- Molina V, Carbajal D, Arruzazabala L and Mas R (2005). Therapeutic effect of D-002 (abexol) on gastric ulcer induced experimentally in rats. *J. Med. Food*, **8**(1): 59-62.
- Muniappan M and Sundararaj T (2003). Anti-inflammatory and antiulcer activities of *Bambusa arundinacea*. *J. Ethnopharmacol.*, **88**(2-3): 161-167.
- NIH (1996). Guide for the Care and Use of Laboratory Animals, (NIH Publication No. 85-23 revised). Bethesda, MD, US National Institutes of Health.
- Scarpignato C (1995). Nonsteroidal anti-inflammatory drugs: how do they damage gastroduodenal mucosa? *Dig. Dis.*, **13**(Suppl. 1): 9-39.
- Shehab NG and Abu-Gharbieh E (2012). Constituents and biological activity of essential oil and aqueous extract of *Micromeria fruticosa* L druce *M. Serpyllifolia*. *Pak. J. Pharm. Sci.*, **25**(3): 687-692.
- Taesotikul T, Panthong A, Kanjanapothi D, Verpoorte R and Scheffer JJ (2003). Anti-inflammatory, antipyretic and antinociceptive activities of *Tabernaemontana pandacaqui* Poir. *J. Ethnopharmacol.*, **84**(1): 31-35
- Whittle BA (1964). The use of changes in capillary permeability in mice to distinguish between narcotic and nonnarcotic analgesics. *Br. J. Pharmacol. Chemother.*, **22**: 246-253.
- Winter CA, Risley EA and Nuss GW (1962). Carrageenan-induced edema in hind paws of the rat as an assay for anti-inflammatory drugs. *Proc. Soc. Exp. Bio. Med.*, **111**: 544-547.
- Yaniv Z, Dafni A and Palevitch D (1982) Labiateae as medicinal plants in Israel. Aromatic plants: Basic and applied aspects. The Hague: Martinus Nijho, pp.265-269.