

## **REPORT**

### **A case report on Nevirapine induced exfoliative dermatitis**

**Thattakudian Sheikuduman Mohamed Saleem<sup>1\*</sup>, Kakavakam Jyothi<sup>1</sup> and S Chandra Babu<sup>2</sup>**

<sup>1</sup>Drug Information Centre, Department of Pharmacy Practice, Annamacharya College of Pharmacy, Rajampet, India

<sup>2</sup>Department of General Medicine, Rajiv Gandhi institute of medical sciences, Kadapa, India

**Abstract:** Drug induced adverse drug reactions is more common in long term therapy particularly in immune compromised patients. Most of the drugs causing dermatological reactions like skin rashes, pruritus, steven johnson syndrome and exfoliative dermatitis. Nevirapine is the first line drug for human immunodeficiency virus (HIV) infection from the category of non-nucleoside reverse transcriptase enzyme inhibitor (NNRTI). In the present cases, we have reported the nevirapine induced severe exfoliative dermatitis. A patient admitted in the hospital with the symptoms of scaling on the skin and he received Nevirapine as a drug for his diagnosis of HIV for past three years. After clear examination exfoliative dermatitis was conformed and suspected with the cause due to Nevirapine. The drug was stopped and the patient was treated with drugs for symptomatic cure. The patient was recovered from his condition and other antiretroviral drugs were recommended for his treatment.

**Keywords:** Antiretroviral therapy, adverse drug reaction, erythroderma, HIV, skin rashes.

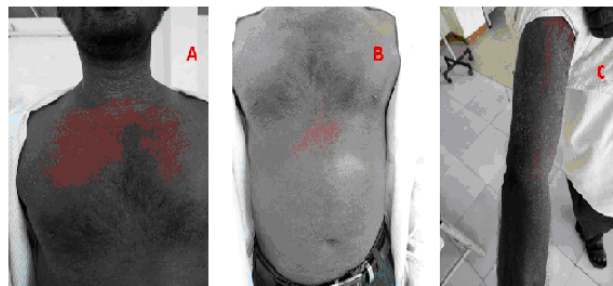
#### **INTRODUCTION**

Nevirapine is the first line drug for human immunodeficiency virus (HIV) infection from the category of non-nucleoside reverse transcriptase enzyme inhibitor (NNRTI). Hepatotoxicity and skin rashes are the most common adverse drug reaction of the drug nevirapine (Flexner, 2006; Aronson 2006; Safrin, 2009). In some case study it has been reported that the use of nevirapine produce the exfoliative dermatitis (ED) commonly called as erythroderma (Sharma *et al.*, 2007; Bhandarkar *et al.*, 2011; Rachamanti *et al.*, 2014; Kumar and Kiran, 2014). ED is a skin disease with an inflammatory scaling which affect mostly on the cutaneous surface. Drug reaction is most important cause for the development of ED. The following drugs are reported with ED like Allopurinol, Nevirapine Carbamazepine, Codeine, Captopril, Diphenylhydantoin Gold, Antimicrobials etc (Rachamanti *et al.*, 2014).

#### **Case report**

A 30 years old male was admitted in the Rajiv Gandhi Institute of Medical Science Hospital, Kadapa with complaints of scaling over the skin since nine days. He was diagnosed with HIV disease for last three years and received Lamivudine and Zidovudine as initial drug treatment with the dose of 150 and 300mg twice daily respectively. Then the drug treatment was changed to Nevirapine 200 mg as once in a day administration for first two weeks and twice daily from third week onwards. His past medical history with other drugs does not showing any evidence of dermatological diseases like

psoriasis and a topic dermatitis. During his admission, after clear examination it was found that the lesions are erythematous and scaly plaques present over the face, neck, trunk and back and involving more than 50% of the total body (fig. 1). No mucosal and genitalia involvement. Hair and nails are normal. The condition was diagnosed as drug induced ED and the suspecting drug was Nevirapine as causative by the Dermatologist. The laboratory investigation like RBS, Liver function tests shows normal values. CD4<sup>+</sup> T-cell count was 350 cells/mm<sup>3</sup>.



**Fig. 1:** Exfoliative dermatitis a) exfoliation and scaling on the trunk region, b) intense exfoliation over the stomach region, c) severe exfoliation and scaling over the upperlimbs.

#### **Outcome and follow-up**

After suspecting the condition the patient was advised to stop Nevirapine and started treatment for ED. He was prescribed with Dexamethasone injection (Decadron) 2cc, Avil injection 2cc, Cetirizine tablet and Betamethasone ointment initially and after four days the injections were replaced with tablets along with vitamin supplements,

\*Corresponding author: e-mail: saleemcology@gmail.com

betamethasone cream and Liquid paraffin for topical application. After two weeks of treatment the patient showed significant improvement in his condition. He was discharged after three weeks and the ART treatment was changed to Zidovudine 300mg plus Lamivudine 150mg twice daily.

## DISCUSSION

Before Nevirapine treatment the patient was prescribed with Zidovudine plus Lamivudine. The ED was observed after initiation of the Nevirapine treatment. Then after withdrawal of the Nevirapine the ED symptoms were slowly normalised and the patient is able to tolerate the new HAART therapy (Rachamanti *et al.*, 2014). In many case reports it was observed that Nevirapine was the main causative agent for ED. WHO Uppsala Monitoring Centre Causality Assessment Criteria also indicated a probable association with nevirapine (Edwards and Aronson, 2000). Usually mild to moderate maculopapular rash (immune mediated) occur most frequently within the first 6 weeks of therapy of nevirapine (Cattelan and Trevenzoli, 2001). This adverse reaction is not dose-related, can be labeled as a type-B (bizarre) class of adverse effect and can be considered as probable or likely as per WHO scale of causality assessment of suspected adverse drug reactions (Rachamanti *et al.*, 2014). Delay in discontinuing nevirapine after onset of mild to moderate rash may result in more severe reaction. Mild nevirapine rash is usually a self-limited reaction that can be treated symptomatically. Moderate to severe nevirapine rash, with or without hepatitis, requires discontinuation of nevirapine. HLA-B\*3505 allele is a strong predictor for Nevirapine induced skin ADR in HIV infected patients (Kumar and Kiran, 2014).

## CONCLUSION

Adverse drug reactions are needed to be monitored and assessed using the causality assessment scales to know severity and type of ADR. Managing ADRs in ART ward are crucial to establish a successful HIV regimen. Early withdrawal of the causative agent is essential to prevent the progression of the reaction.

## REFERENCES

- Aronson JK (2006). *Meyler's side-effects of drugs*, 15<sup>th</sup> ed., Elsevier., The Netherlands, pp.2498-2502.
- Bhandarkar AP, Kop PB and Pai VV (2011). Nevirapine induced exfoliative dermatitis in an HIV-infected patient. *Ind. J. Pharmacol.*, **43**(6): 738-739.
- Cattelan AM and Trevenzoli M (2001). Toxic epidermal necrolysis induced by nevirapine therapy: Description of two cases and review of the literature. *J. Infection.*, **43**: 246-254.

- Edwards IR and Aronson JK (2000). Adverse drug reactions: Definitions, diagnosis and management. *Lancet.*, **356**: 1255-1259.
- Flexner C (2006). Antiretroviral agents and treatment of HIV infection. In: Brunton LL, Lazo JS, Parker KL editors. *The Pharmacological basis of therapeutics*, 10<sup>th</sup> ed. Mc Graw-Hill., New York, pp.1273-314.
- Kumar KB and Kiran AG (2014). Cutaneous adverse drug reaction to antiretroviral therapy in children. *Indian J. Paediatr. Dermatol.*, **15**: 96-99.
- Rachamanti R, Naidu MB and Rajkumar K (2014). Nevirapine Induced Exfoliative Dermatitis: A Case Report. *IOSR. J. Dental. Medical Sci.*, **13**(4): 1-3
- Safrin S (2009). Antiviral agents. In: Katzung BG, Masters SB, Trevor AJ editors. *Basic and clinical pharmacology*, 11<sup>th</sup> ed., McGraw-Hill. New York, pp.845-875.
- Sharma A, Modi M, Sharma A and Marfatia YS (2007). Cutaneous eruptions associated with nevirapine therapy in AIDS cases. *Indian J. Sex. Transm. Dis.*, **28**: 94-96.